HIPPOCAMPAL FORMATION

1. Gyrus dentatus (s. fascia dentata)
2. Ammon horn (s. hippocampus proper)

} two interlocking gyri

Taip pat priskiriama:

3. SUBICULUM – transition zone between gyrus parahippocampalis (six-layered cortex) and Ammon horn (three-layered cortex); dvoda aksonus, kurie per fornix inervuoja hypothalamus

4. HIPPOCAMPAL RUDIMENTS:
   1) BROCA diagonal band
   2) Gyrus supracallosus (s. indusium griseum)
   3) Gyrus fasciolaris

ALVEUS – baltoji medžiaga, dengianti skilvelinį hippocampus paviršių; pereina į FIMBRIA (narrow sharp-edged crest of white matter, attached to medial border of hippocampus), o ši į FORNIX

baltoji medžiaga paviršiuje!

Hippocampus (s. hippocampal formation) – primitive cortex (archicortex – three-layered) along medial margin of temporal lobe, rolled into the floor of temporal horn along choroid fissure

Hippocampus in frontal section

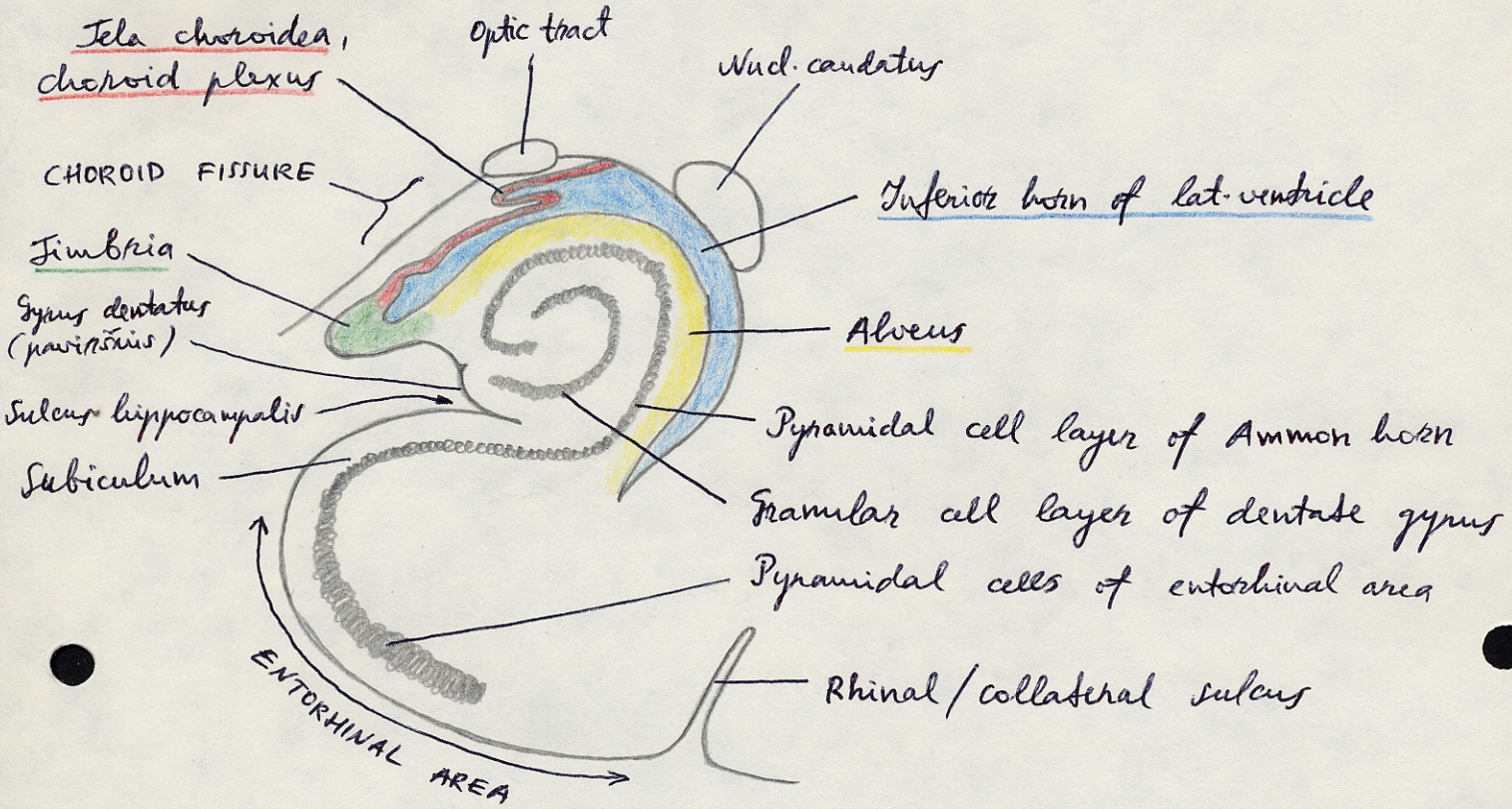

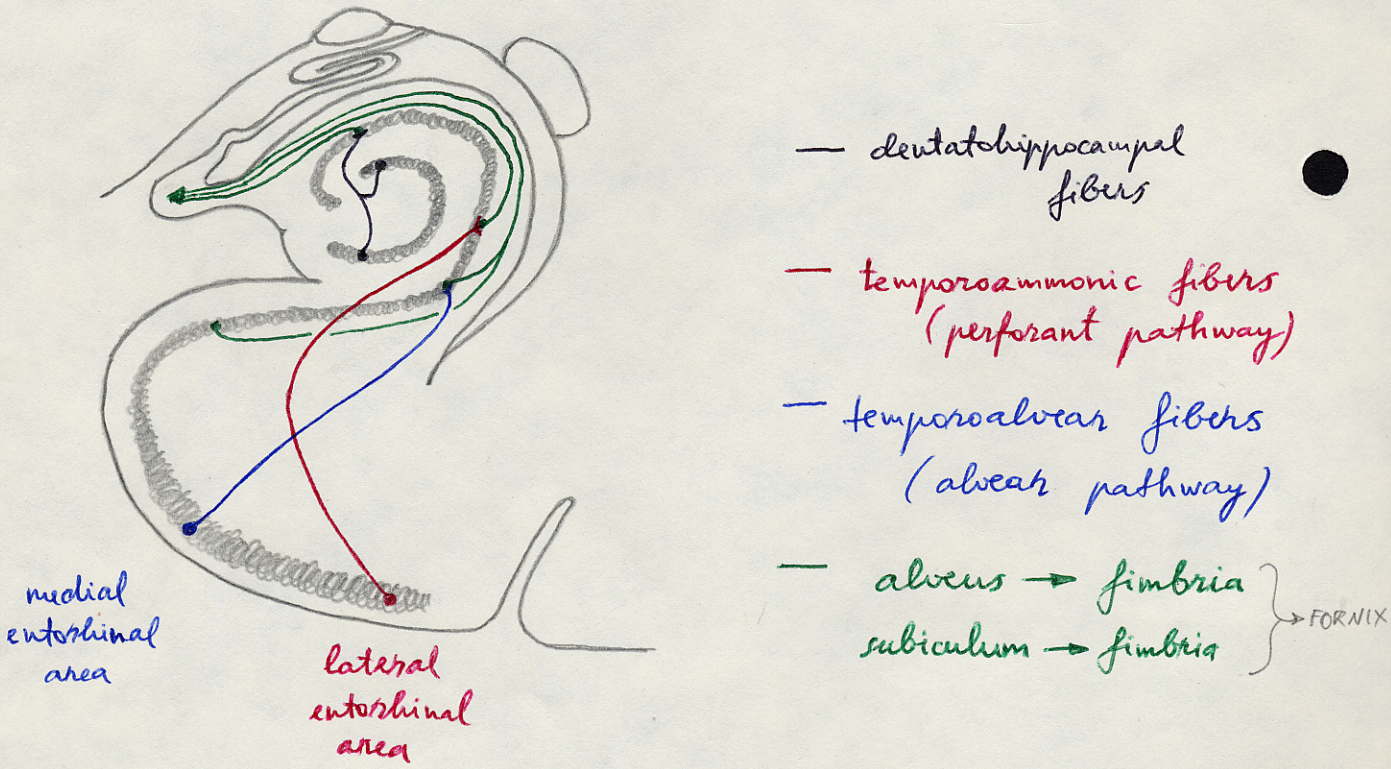

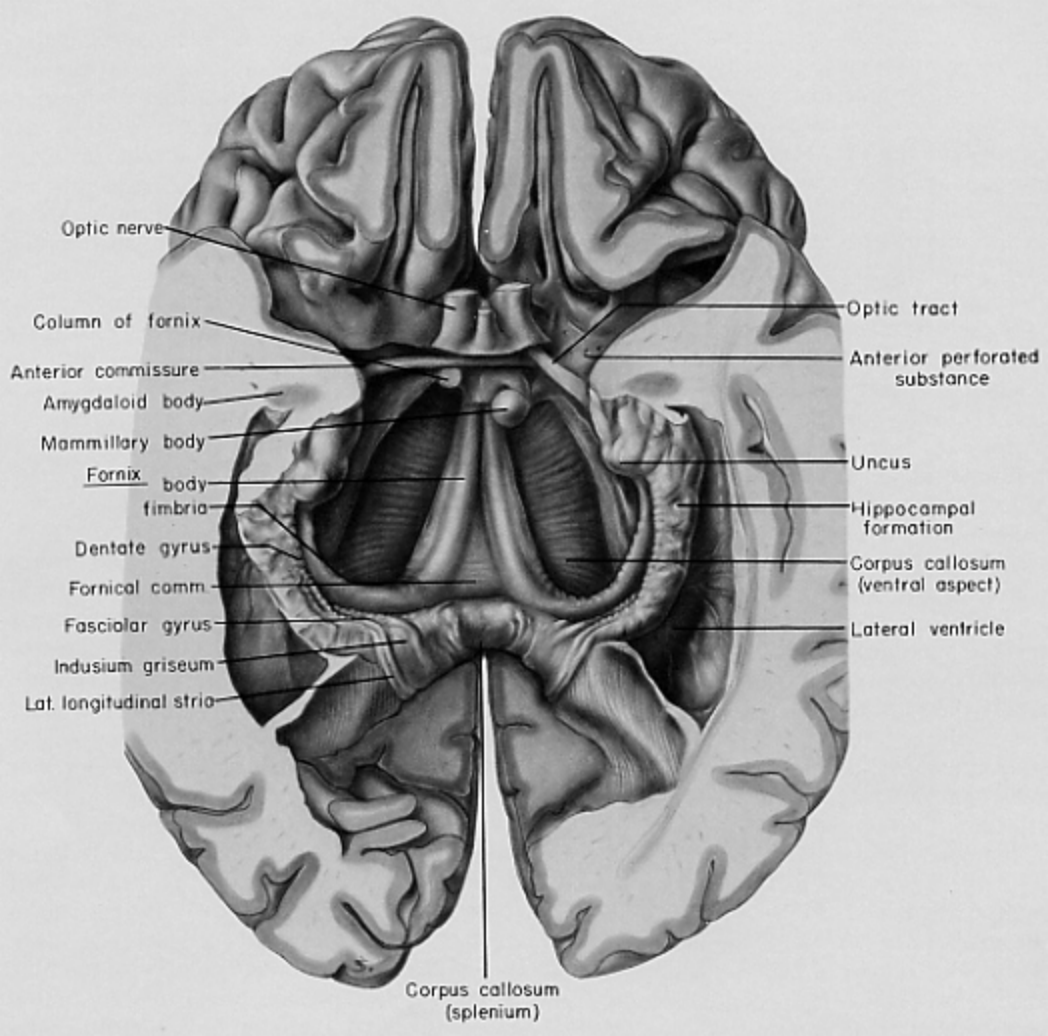
Optic nerve
Column of fornix
Anterior commissure
Amygdaloid body
Mammillary body
Fornix
body
fimbria
Dentate gyrus
Fornical comm.
Fasciolar gyrus
Indusium griseum
Lat. longitudinal stria
Optic tract
Anterior perforated substance
Uncus
Hippocampal formation
Corpus callosum (ventral aspect)
Lateral ventricle
Corpus callosum (splenium)

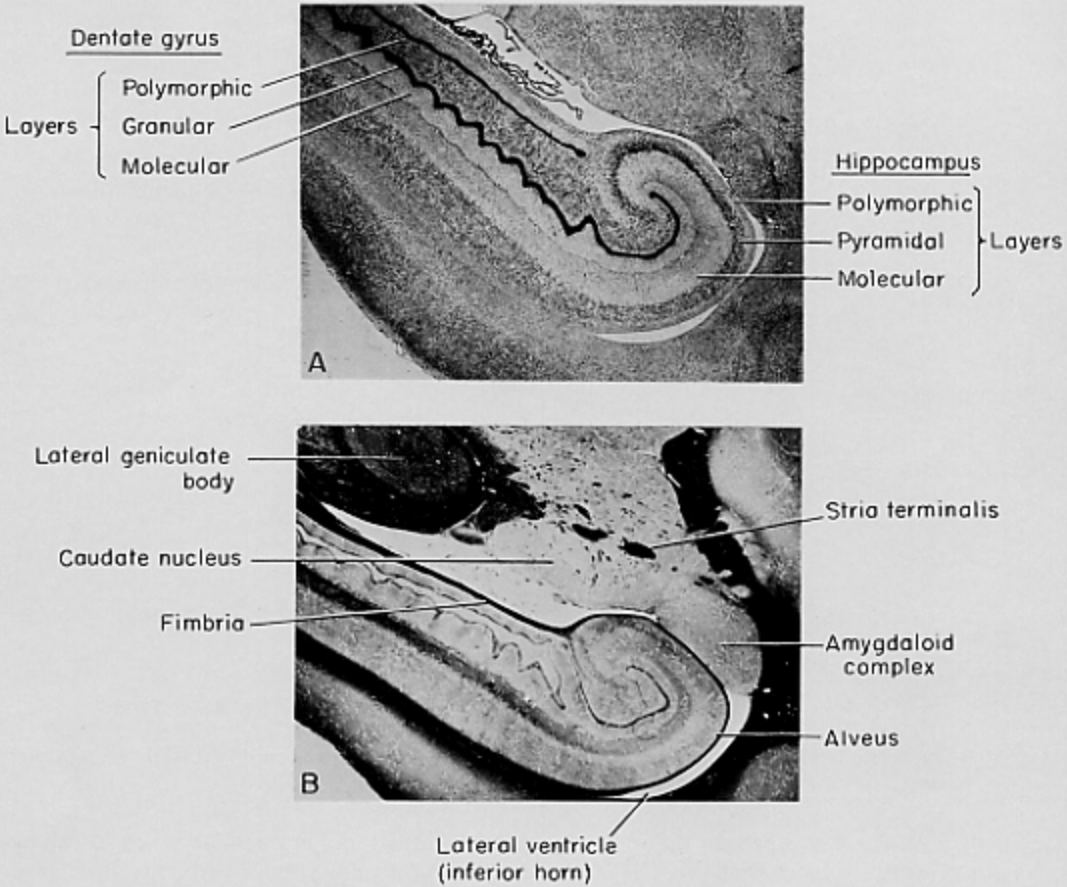

Fig. 11-7. Sagittal sections through the hippocampal formation and dentate gyrus in the rhesus monkey showing the relationships of these structures to the inferior horn of the lateral ventricle, the neostriatum and the amygdaloid nuclear complex. In *A*, the cellular layers of the hippocampal formation and dentate gyrus are identified. In *B*, the alveus, fimbria, tail of the caudate nucleus, stria terminalis, amygdaloid complex and part of the lateral geniculate body are identified. *A*, Nissl stain, × 8; *B*, Weil stain, × 9. (From Truex and Carpenter, *Human Neuroanatomy*, 1969; courtesy of The Williams & Wilkins Company.)

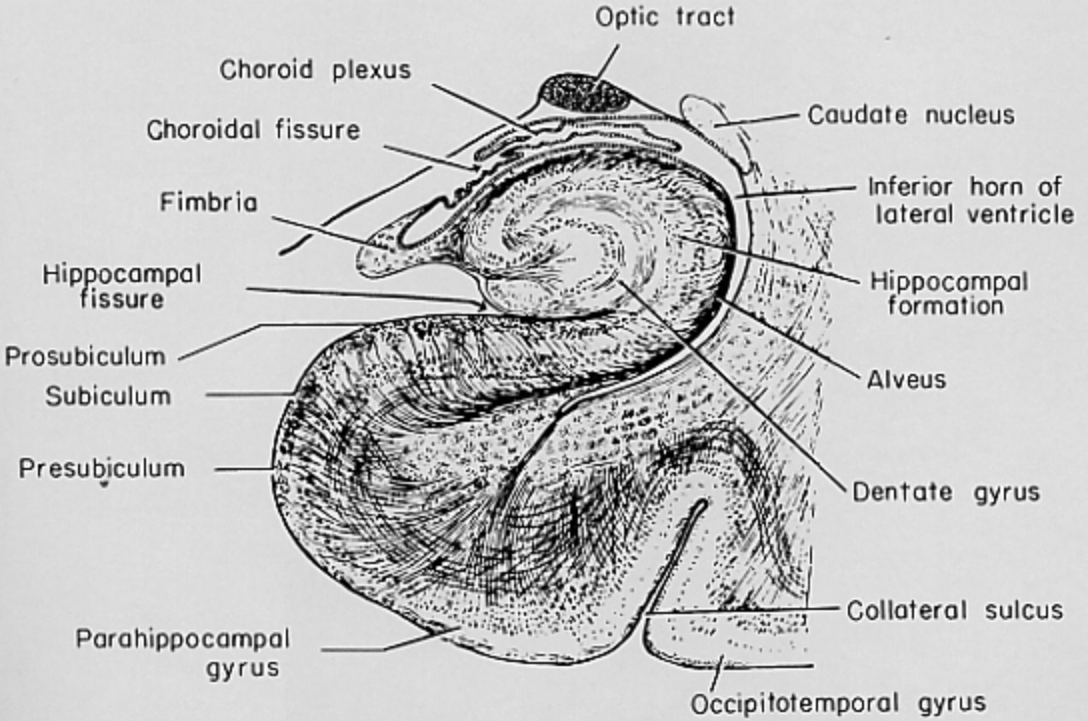

Fig. 11-6. Transverse section through human hippocampus and parahippocampal gyrus. (From Truex and Carpenter, *Human Neuroanatomy*, 1969; courtesy of The Williams & Wilkins Company.)

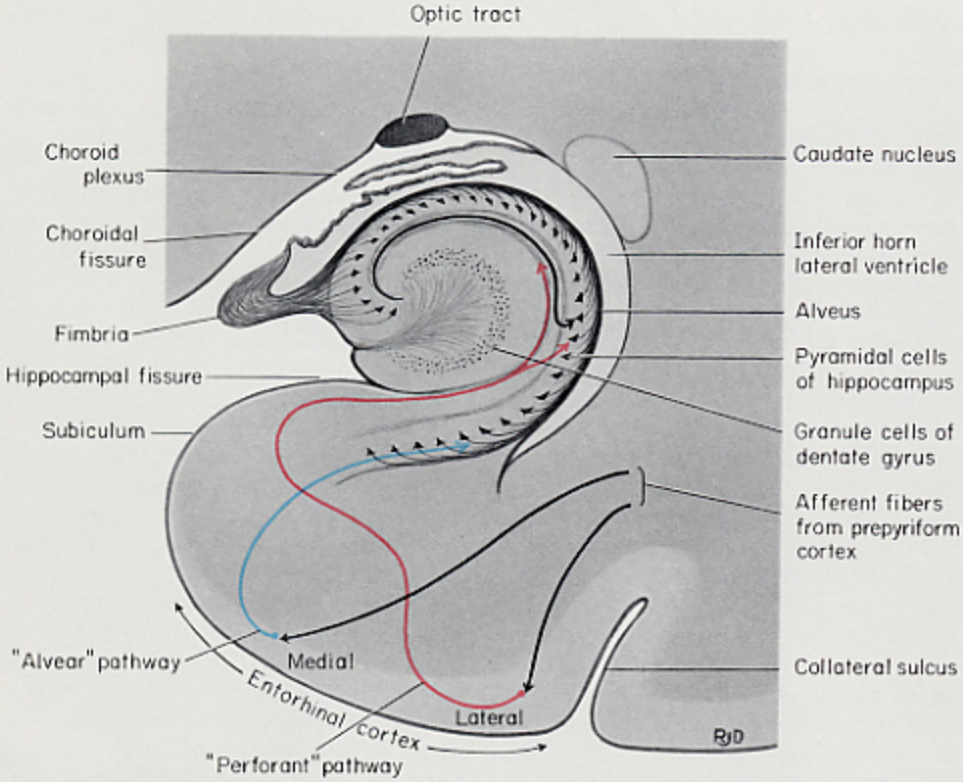

11-8. Semischematic diagram of the hippocampal formation, dentate gyrus and entorhinal area. In the dentate gyrus only the granular layer is indicated. In the hippocampal formation only pyramidal cells and their axons projecting into the alveus are shown. Afferent fibers from prepyriform cortex projecting to the entorhinal cortex are shown in *black*. Projections of the entorhinal cortex to the hippocampal formation follow two pathways: (1) the lateral region gives rise to fibers which follow the so-called "perforant" pathway (*red*), and (2) the medial region gives rise to fibers which follow the so-called "alvear" pathway (*blue*). Axons of pyramidal cells in the hippocampal formation entering the alveus pass to the fimbria of the hippocampus. The dentate gyrus gives rise to fibers that project only to the hippocampal formation. (Based on Lorente de Nó, '34, and a schematic diagram by Peele, '61). (From Truex and Carpenter, *Human Neuroanatomy*, 1969; courtesy of The Williams & Wilkins Company.)

Connections:

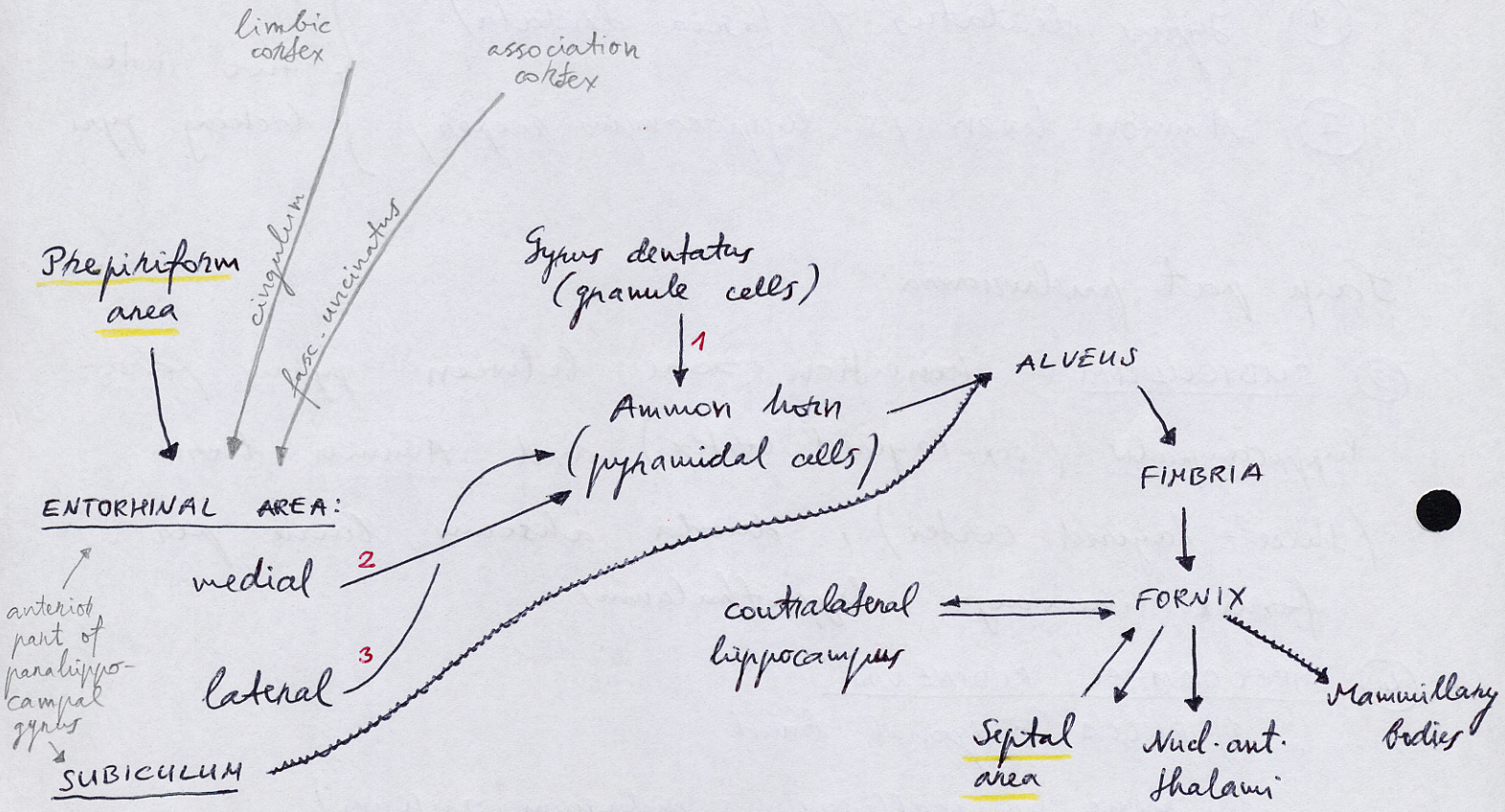

— major afferent connections

1 dentatohippocampal fibers – gyrus dentatus projektuojasi tik (!) į Ammon horn; tai kad gyrus dentatus pereina į gyrus fasciolaris yra tik anatomiškai

2 temporoalvear fibers (alvear pathway) – skaidulos į Ammon horn žievę patenka iš ALVEUS pusės (t.y. iš skilvelio pusės); čia priskiriama ir „subiculum → fimbria" skaidulos ?

3 temporoammonic fibers (perforant pathway) – skaidulos perforuoja subiculum žievę ir patenka į Ammon horn žievę iš kitos pusės

(NA) teigia, kad gausiausios Ammon horn (pyramidal cells) projekcijos eina į subiculum ir entorhinal cortex

apie FORNIX – A118 (1) psl.

Hippocampus žievė primityvi, trisluoksnė (archicortex):

a) Ammon horn:

1) molecular layer
2) pyramidal layer
3) polymorphic layer

pyramidal neurons – – „final common pathway" iš hippocampus

b) gyrus dentatus:

1) molecular layer
2) granular layer
3) polymorphic layer

Hippocampus embriogenezė:

• hippocampus formuojasi along hippocampal sulcus, immediately above and parallel to choroidal fissure (which marks invagination of choroid plexus into ventricle)

• evaginuojant temporal lobe, šie plyšiai ir hippocampus užsirieda žemyn ir į priekį (kaip „C" raidė)

• fuomet viršutinę hippocampal sulcus dalį perauga corpus callosum ir ji tampa sulcus corporis callosi, o viršutinė hippocampus dalis lieka kaip rudimentas – indusium griseum; apatinė hippocampus dalis tolian vystosi į hippocampal formation

Functions:

- hippocampus has exceedingly low threshold for seizure activity
- belongs to circuit of recent memory and learning
- belongs to PAPEZ circuit for emotions

Hippocampus labai jautrus hipoksijai ir hipoglikemijai (joms kartojantis ar sekant epilepsija atrofuoja hippocampus bei adjecent temporal cortex [subiculum, entorhinal area]) – mesial temporal lobe sclerosis