

Rubrospinal tract

Last updated: April 20, 2019

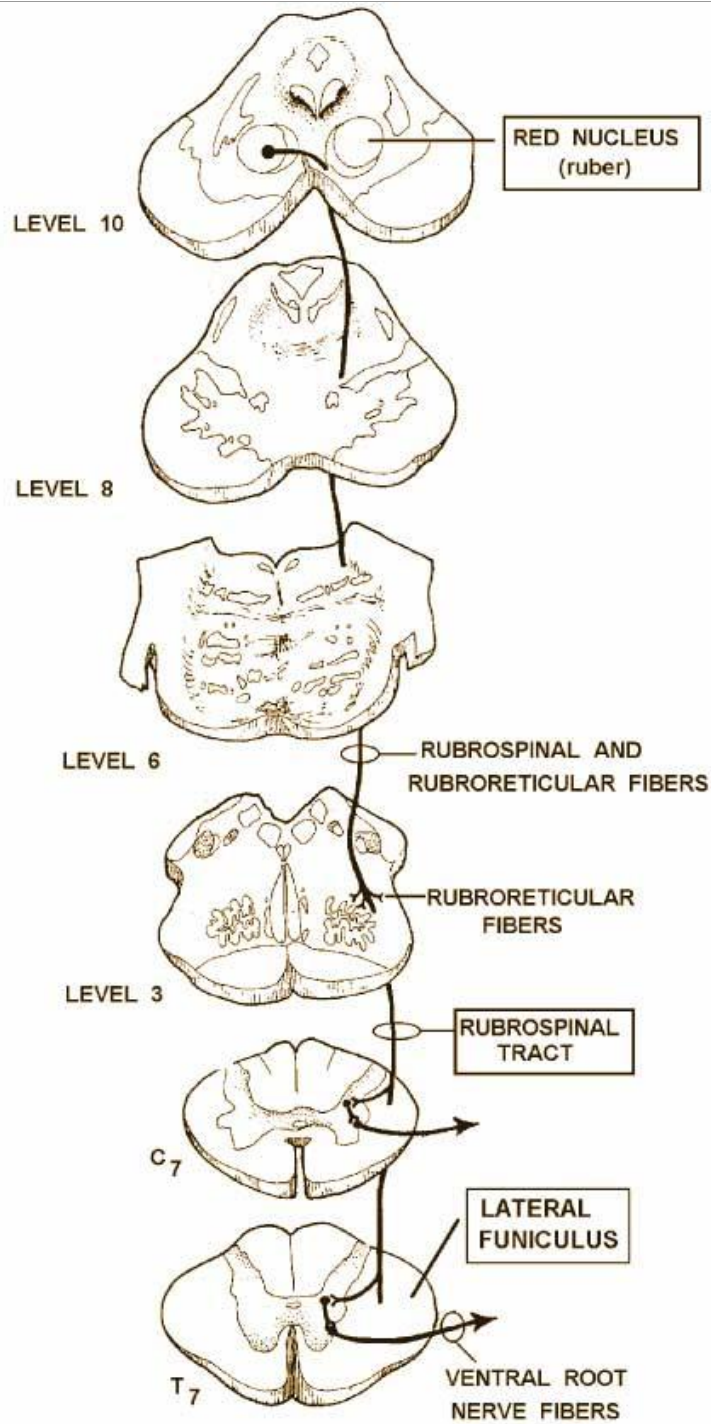
Involved in the maintenance of flexor tone.

Fibers from red nucleus in the ventral tegmentum, travel anteriorly, and partially intermingle with the corticospinal tract to descend to laminae V, VI, and VII over the entire length of the cord.

Red nucleus input-both cerebral cortices and the contralateral cerebellar nucleus interpositus via superior peduncle, with somatotopic organization from cortex to the spinal cord.

Red nucleus stimulation-contralateral flexion and inhibition of extension

The rubrospinal tract originates in the magnocellular region of the red nucleus, decussates in the ventral tegmentum, and descends to all spinal levels in the lateral funiculus of the spinal cord. Corticorubral fibers from the motor cortex project bilaterally to the red nuclei, and rubrospinal fibers then descend and terminate in laminae V, VI, and VII of the spinal gray. Crossed cerebellar efferentes from the dentate nucleus and interposed nuclei enter the superior cerebellar peduncle and terminate in the red nucleus as well. The rubrospinal tract is primarily concerned with flexor muscle group tone and represents a nonpyramidal pathway of motor control. Lesions rostral to the red nuclei remove cortical inhibition of rubrospinal neurons resulting in flexor (decorticate posturing). Decorticate posturing results in flexion of the upper extremities and extension of the lower extremities because the majority of rubrospinal input is to cervical levels of the spinal cord.



RUBROSPINAL TRACT

BIBLIOGRAPHY for ch. "Spinal Cord" → follow this [LINK >>](#)