HISTOLOGY – supporting cells

Supporting tissues of NS funkcijos:

1. Atrama neuronams
2. Apsauginiai dangalai (skull, meninges)
3. Skysčių (intercellular, CSF) gamyba
4. Blood-brain barrier
5. Randų formavimas
6. Mielino dangalas

• Kiek yra du tipai of supporting tissue:

1) fibrous connective tissue – sudaro CNS ir PNS dangalus
2) glia – jeina į nervinio audinio sudėtį (atstoja fibrous connective tissue funkciją)

• Glia contains no extracellular fibrils and relatively little extracellular fluid

• Kai kas glijai priskiria ir Švano bei satelitines ląsteles

• Gliocitų daugiau negu neuronų
└ ≈ 10-50 kartų!

• Gliocitai įprastiniose preparatuose (H&E) sušviečiami pagal nucleus – tik jis gerai matomas

CNS glia (NA – 30)

Kilmė:
MACROGLIA (oligodendrocytes, astrocytes, ependyma) – neuroectoderm
MICROGLIA – bone marrow

① OLIGODENDROCYTES

mielinas!

• few processes
• myelin-forming cells of CNS

② ASTROCYTES

CNS stroma – karkasas! (randai)

• many processes
• processes develop END-FEET at the junction of nerve tissue and non-nerve tissue:
  a) aplink kraujagysles
  b) smegenų paviršiuje (glia limitans)
  c) po ependima skilvelinose
• susijungę tarpusavyje GAP JUNCTIONS (? – gal TIGHT JUNCTIONS)
• tipai:
  a) fibrous (white matter) ← many intracytoplasmic INTERMEDIATE FILAMENTS
  b) protoplasmic (gray and white matter) ← granular cytoplasm

• sudaro ASTROCYTE SHEATH (Ranvier sąsmaukose, aplink sinapses – t.y. ten, kur nėra mielino); perisinaptiniai astrocitai neleidžia išplisti neurotransmiteriui į aplinką ir metabolizuoja jo perteklių

• reguliuoja K^+ kiekį nerv. audinyje; gamina neurotrophins.
• sudaro randus in CNS (gliosis)

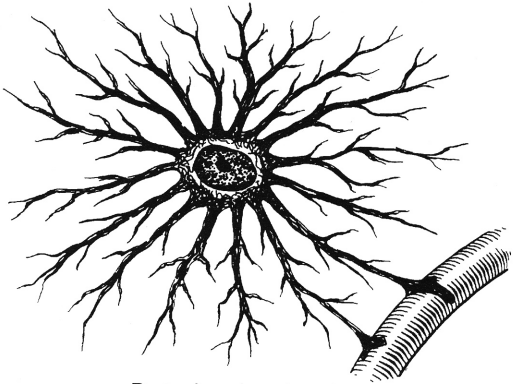

Protoplasmic astrocyte

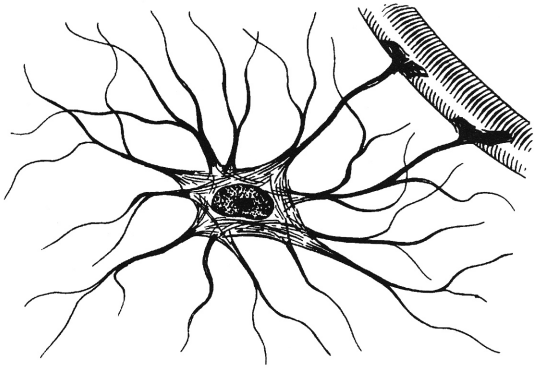

Fibrous astrocyte

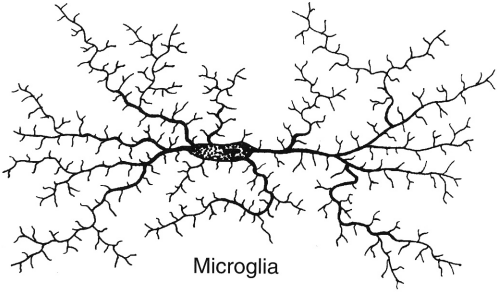

Microglia

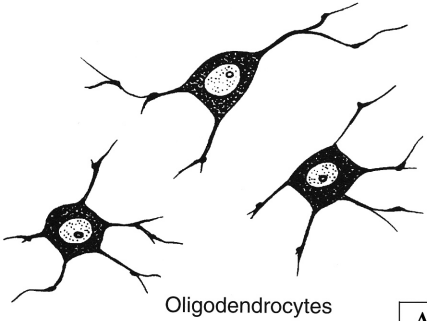

Oligodendrocytes

A6 (1a)

③ MICROGLIA fagocitozė! (fixed macrophages of CNS)

- smallest glial cells, present only in small numbers
- members of MONONUCLEAR PHAGOCYTE SYSTEM – kaupiasi pažeidimų židiniuose

④ EPENDYMAL CELLS skilvelių sienelės!

- simple columnar epithelium
- line cavities of CNS
- dalyvauja liquoro sekrecijoje (choroidal plexus epitelis)

Perineuronal satellite cells – tai astrocitai, oligodendrocitai ir mikroglia – atsiglėmis kontaktuoja perikarjon

PNS glia

- kilusi iš neural crest (todėl nėra glia per se)
- sudaro vientisą sluoksnį, padengiantį PNS neuronus

① SCHWANN cells (s. neurolemma cells) myelin

- myelin-forming cells of PNS
- also ensheath unmyelinated axons
- reguliuoja metabolizmą tarp aksono ir periaxonal space

② SATELLITE cells (s. amphicytes) (Atlas – 267 (4)) (→ 317 (4)) in ganglia

- sudaro epitelioidinį sluoksnį aplink neuronų kūnus ganglijuose
- nesudaro mielino (išsk. ganglia of n. VIII)

Neuropil – kompleksinis neuronų ir neuroglijos atsaugų tinklas (primenantis veltinį (graik. PILOS – veltinis)), sudarantis didžiąją dalį CNS pilkosios medžiagos; neuronal perikarya lie embedded in neuropil

Figure 29–2. Astrocytes and their processes. Some processes are attached to blood vessels (*arrow*) (Cajal gold sublimate).

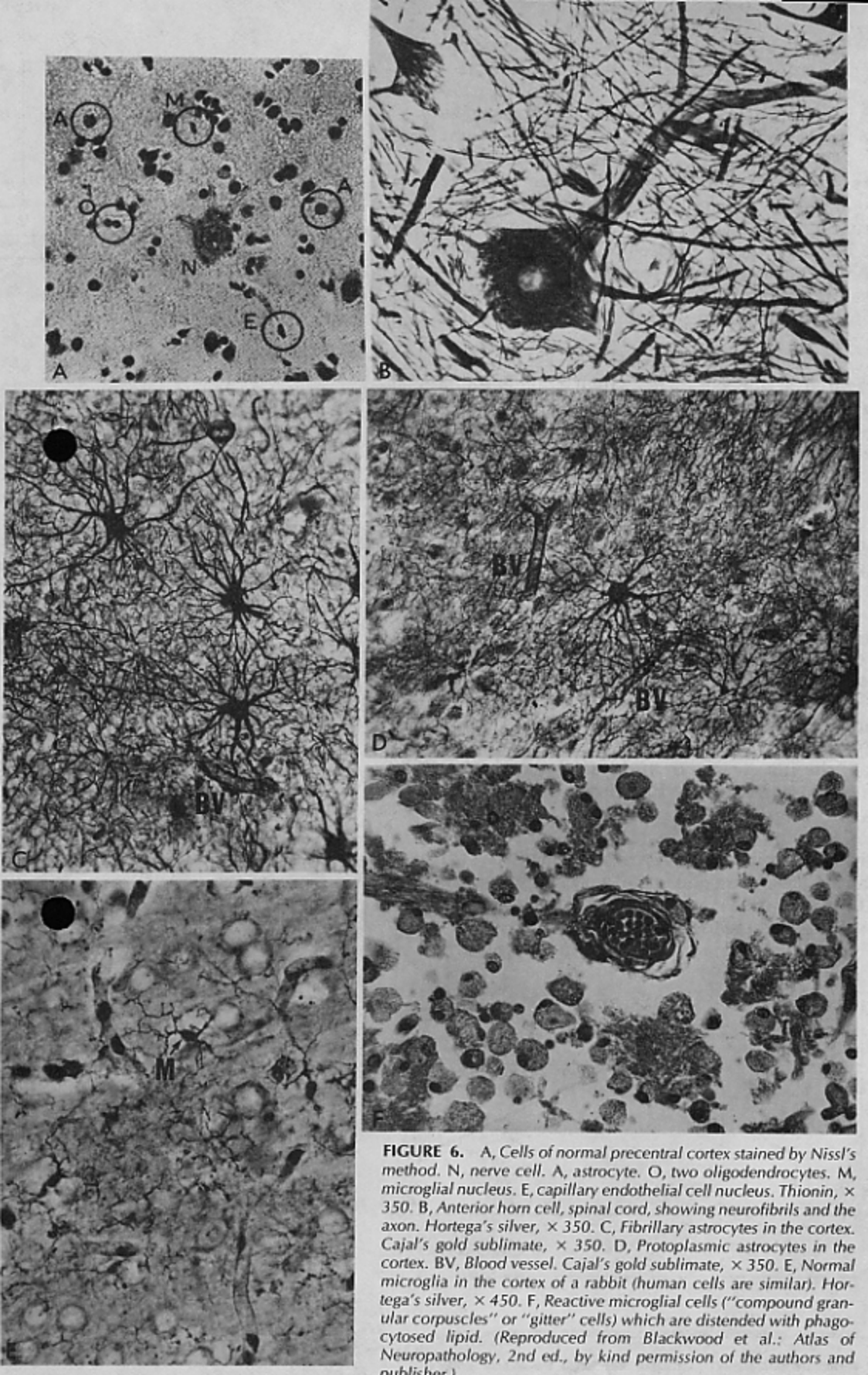

FIGURE 6. A, *Cells of normal precentral cortex stained by Nissl's method.* N, *nerve cell.* A, *astrocyte.* O, *two oligodendrocytes.* M, *microglial nucleus.* E, *capillary endothelial cell nucleus. Thionin,* × *350.* B, *Anterior horn cell, spinal cord, showing neurofibrils and the axon. Hortega's silver,* × *350.* C, *Fibrillary astrocytes in the cortex. Cajal's gold sublimate,* × *350.* D, *Protoplasmic astrocytes in the cortex.* BV, *Blood vessel. Cajal's gold sublimate,* × *350.* E, *Normal microglia in the cortex of a rabbit (human cells are similar). Hortega's silver,* × *450.* F, *Reactive microglial cells ("compound granular corpuscles" or "gitter" cells) which are distended with phagocytosed lipid. (Reproduced from Blackwood et al.: Atlas of Neuropathology, 2nd ed., by kind permission of the authors and publisher.)*