Neurologic Examination

Last updated: June 3, 2019

Note: portions of the text are in a process of being translated into English

Three main functions of nervous system:

1. Sensory
2. Motor
3. Mental

Objective examination is started during history taking – by observing patient and listening to his / her

speech.

Aging alone causes symmetrical changes!

EQUIPMENT FOR NEUROLOGIC EXAMINATION:

INSTRUMENT	USE
Flexible steel **measuring tape**	measuring body circumferences, length of extremities, size of skin lesions, etc.
Transparent mm **ruler**	measuring pupillary size, size of skin lesions, distances on radiographic films
Stethoscope	auscultation for bruits (neck vessels, eyes, cranium)
Blood pressure cuff	checking blood pressure and orthostatic hypotension
Flashlight with rubber adapter	checking pupillary reflexes, inspection of pharynx, transillumination of infant head
Tongue blades (three per patient)	1 – for depressing tongue 2 – for eliciting gag reflex 3 (broken) – for eliciting abdominal and plantar reflexes
Opaque **vial** of coffee	testing smell
Opaque **vials** of salt and sugar	testing taste
Ophthalmoscope	funduscopy; examination of ocular media and skin surface for beads of sweat
Tuning fork (256 Hz recommended)	testing vibratory sensation and hearing
Otoscope	examination of auditory canal and drum
10-cc **syringe**	caloric ear irrigation
Cotton wisp	one end rolled for eliciting corneal reflex; other loose for testing light touch
Two stoppered **tubes**	testing hot and cold discrimination
Disposable straight **pins**	testing pain sensation
Penny, nickel, dime, paper clip, key	testing stereognosis
Page of stimulus figures (Halstead-Reitan screening test)	screening for cerebral dysfunctions
Reflex **hammer**	eliciting muscle stretch reflexes; muscle percussion for myotonia

BABINSKI/RABINER Hammer:

TAYLOR Hammer:

TRÖMNER Hammer:

RIESTER DEJERINE Hammer:

COMPLAINTS (QUERIMONIA)

1. **Loss of consciousness** (fainting, blackouts)
2. **Sensory** (exact location, symmetry):
    1) **pains** (incl. headache)
    2) **numbness** (anesthesia)
    3) **tingling** (paresthesias)
3. **Motor**:
    1) muscle **weakness** (local, general) – what pacientas gali daryti ir ko negali (e.g. is this weakness for brushing the hair or opening a twist-top bottle?).
    2) **involuntary** movements (incl. tremors)
    3) **fallings** (all adults who fall without ready explanation should be evaluated neurologically).

4. **Autonomic: defecation, micturition, sexual** disorders, **flushing** / **pallor**, (**non**)**sweating** of different body parts.
5. **Sleep** disorders.
6. **Mood / affective** disorders.
7. **Memory** disorders.
8. **Speech & language** disorders (ask for ***handedness***).
9. **Seizures** further see p. E1 >>
7. **Trauma** - mechanisms, forces & circumstances (būtinai apklausti ir liudininkus, paramedikus):
   a) **head injury** further see p. TrH1 >>
   b) **spinal injury** further see p. TrS5 >>

- inquire about ***actions / maneuvers that patient suspects of triggering his/her symptoms***; then reproduce these actions and perform any necessary tests (pvz. jei skundžiasi, jog sunku lipti laiptais – tegul parodo kaip lipa laiptais).
- attention to *subjective descriptions of complaint* - same words often mean different things to individual patients.

HISTORY

1. **Temporal course** of illness:
   1) ***rapid onset*** (seconds ÷ minutes)
      a) VASCULAR EVENT ("negative" symptoms - sensory or motor); transient remission or regression indicates that process is likely ischemic and not hemorrhagic.
      b) SEIZURE ("positive" symptoms - sensory or motor).
      c) MIGRAINE
      d) TRAUMA
   2) ***subacute onset*** (hours ÷ days)
      a) DEMYELINATING process
      b) INFECTIOUS process.
   3) ***chronic course*** (over years)
      a) MULTIPLE SCLEROSIS (remissions and exacerbations involving different levels of neuraxis)
      b) NEURODEGENERATIVE disorder (slowly progressive symptoms without remissions).
2. **Previous nervous system disorders**:
   1) disorders (meningitis, encefalitis, seizures)
   2) traumas
   3) surgeries
3. Previous / current **systemic illnesses** (esp. *MALIGNANCIES* – whether chemotherapy or radiotherapy was given?, metastases, paraneoplastic syndrome).

   If patient is known to have carcinoma, metastatic disease is assumed to be basis of neurologic symptoms until proved otherwise!
4. Vartojami ir vartoti **medications** (both prescribed, OTC and illicit); e.g.:
   digitalis → yellow vision;
   excessive vitamin A → pseudotumor cerebri;
   excessive pyridoxine → peripheral neuropathy;
   aminoglycosides → dizziness, weakness exacerbation in disorders of neuromuscular transmission.
   alcohol – most common neurotoxin!
5. Exposure to **toxins** (environmental or industrial).
6. **Stroke risk factors**:
   1) TIAs
   2) diabetes
   3) hypertension
   4) smoking
   5) c/v disorders (esp. atrial fibrillation)
   6) anticoagulants, antiaggregants
   7) oral contraceptive pills.
7. **Family history** - existence of similar symptoms in other family members, possibility of parental *consanguinity*.

- ***corroborate history by others*** (***surrogate historians*** - family, friends, observers, paramedics) to expand patient's description.
  esp. in cases of memory loss, personality change, drug & alcohol abuse, physical abuse, loss of consciousness!
- ***summarize history for patient*** - effective way to ensure that all details were covered sufficiently; patient (or surrogate historian – family member, caregiver) may correct any historical misinformation at this time.
- ***end by asking patient what he / she thinks is wrong*** - allows physician to evaluate patient's concerns about and insight into condition (some patients have specific diagnosis in mind that spurs them to seek medical attention).

HISTORY indicates **disease nature** or **diagnosis**, whereas NEUROLOGIC EXAMINATION **localizes** it and **quantitates** its severity.

General diagnostic algorithm:

Where is the lesion?
↓
What is the lesion?

90% diagnosis depends on patient's **MEDICAL HISTORY** and remainder 10% comes from **NEUROLOGIC EXAMINATION & LABORATORY TESTS**.

GENERAL EXAMINATION

1) **pulse & BP**
2) **breathing** pattern (diafragminis kvėpavimas - tarpšonkaulinių raumenų paralyžius)

HEAD

1. **Face** - bendra išraiška, veido detalės, plaukai.
2. **Skull** shape, symmetry, malformations.
   - *head circumference* should be measured (normally 55 ± 5 cm in adults); routinely – only children ≤ 2 yrs.
   - *palpable lesions under scalp*.
3. ***Distension of scalp veins*** - sign of increasing ICP.
4. Jei skundžiasi ***galvos skausmais*** - perkutuoti sinusus ir processus mastoideus; sinusus bandyti ir transiliuminuoti.

BACK

also see p. Exam5 >>

1. **Alignment & deformities**
2. **Limitation of motion** (*judesio blokas* - segmentas ir kryptis).
3. **Percussion** (intraspinal lesions frequently produce localized percussion tenderness).
4. **Palpation**:
   1) processus spinosi
   2) paravertebral (per pirštą nuo vidurio linijos, tarp dviejų proc. spinosi - stuburo sąnarėliai)
   3) plexus cervicalis, brachialis et lumbalis.
   - ***pressure over nerve roots*** may produce pain.
   - *generalized paraspinal tenderness* may represent arthritis or myositis, but rarely is associated with intraspinal pathology of surgical significance.
5. **DYSRAPHIC LESIONS**: dimples, nevi, localized hair growth, dermal sinuses, myelomeningoceles.

EXTERNAL SIGNS OF TRAUMA

1) **skalpo pažeidimai** - apžiūrėti ir apčiupinėti. further see p. TrH1 >>
2) **kaukolės lūžimai** (palpuojamos *deformacijos*, *kraujas / likvorėja* nosyje ar ausų landose, periorbitalinės & retroaurikulinės *hematomos*). further see p. TrH5 >>
3) **veido traumos** (apžiūrėti ir apčiupinėti – tenderness, crepitus, false motion); ***burna*** – sąkandis, kraujas / vėmalai / kiti svetimkūniai / išmušti dantys / lūžę dantų plokštelės, echimozės); ***nosis*** – septal hematoma, CSF rhinorrhea. further see p. TrH25 >>
4) **stuburas** - priverstinė padėtis, palpuoti keterines ataugas, paravertebraliai - tai būtina atlikti prieš tikrinant meninginius simptomus (sprando rigidiškumą). further see p. TrS5 >>
   N.B. kol neekskliuduota ūmi nugaros trauma - ligonio nelankstyti!!!
5) ***gretutinės traumos*** - krūtinė, pilvas, juosmuo, galūnės.

MENINGEAL SIGNS

- rutiniškai netiriama (tiriama tik įtariant meningitą ar SAH).

- position patient supine with no pillow; expose and fully extend both legs.

1. Nuchal rigidity – passive flexion **chin-to-chest**:

- *lateral neck movements* are preserved (vs. in neck rigidity from *musculoskeletal pain*).

2. Kernig sign (**bent-knee leg raising**) - ligonis guli ant nugaros, pasyviai sulenkiama koja stačiu kampu per klubo ir kelio sąnarius (with your left hand placed over medial hamstrings) → use your right hand to extend knee (while hip is maintained in flexion) - skauda, neišsitiesia, other leg flexes.

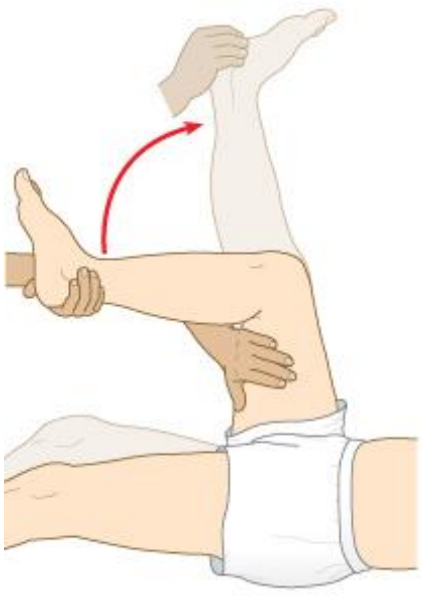

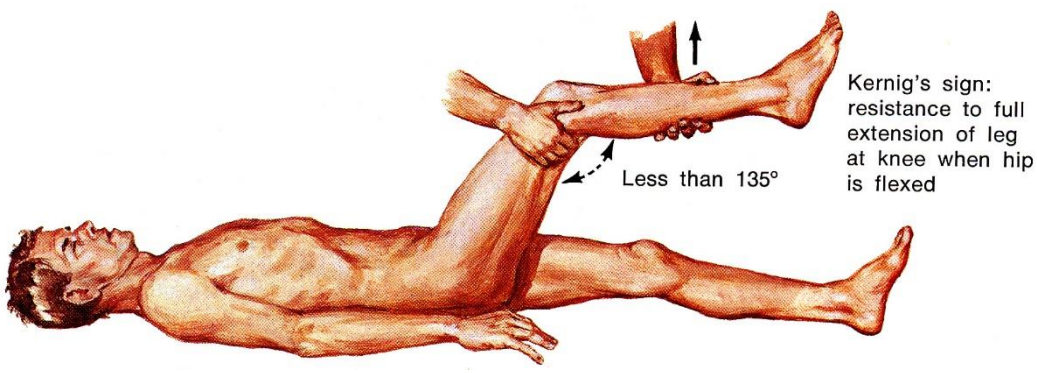

3. Brudzinski signs - ligonis guli ant nugaros:
   1) neck (s. upper) sign - pasyviai lenkiama chin-to-chest*
   2) middle sign - spaudžiamas viršutinis simfizės kraštas*
   3) contralateral (s. lower) sign - atliekamas Kernigo simptomas.**

   *esant meninginiam dirginimui, ***kojos refleksiškai susilenkia***.
   esant meninginiam dirginimui, ***priešinga koja refleksiškai susilenkia*.

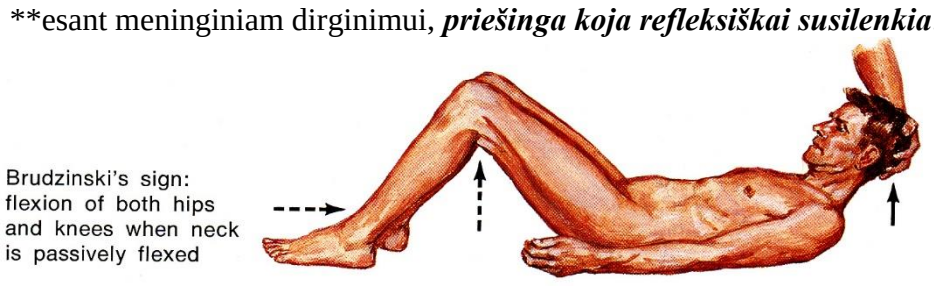

Demented elderly patients may have *false-positive* meningeal signs!

Pediatric aspects → see p. D5 >>

SENSORY EXAMINATION

LESION LOCALIZATION GUIDE → see p. S22 >>

- requires cooperation and concentration by patient - provide brief introduction to purpose and methods of each sensory test.

in ***obtunded patient***, sensory examination is reduced to observing briskness of defensive movements in response to noxious stimulus.

in ***alert but uncooperative patient***, evaluate proprioception by noting patient's movements requiring balance and precision; cutaneous sensation may be unexaminable!

- sensory testing readily fatigues patient (→ unreliable, inconsistent results) – **repeated testing at another time** is often required to confirm abnormalities.
- ligonis **nusirengęs** ir **užsimerkęs**.
- tuo pačiu apžiūrima ir visa oda – *NEUROCUTANEOUS STIGMATA* (e.g. *café au lait* spots, cutaneous angiomata, adenoma sebaceum).
- ***vary pace of testing*** so that patient does not merely respond to your repetitive rhythm.

Tiriant DERMATOMUS, judama taip, kad ligonis galėtų **palyginti gretimus dermatomus**:
a) galūnėse – cirkuliariai.
b) liemenyje – up and down anteriorly or posteriorly (usually, some physiological overlap occurs at sensory level when examiner first moves rostrally then caudally).

N.B. nepamiršk pratestuoti pakaušio srities (supplied by upper cervical dorsal roots) ir tarpvietės (gali būti vienintelis požymis, kad nugaros smegenų transekcija nepilna).

Skriningui (jei pacientas neturi sensorinių nusiskundimų):
1) **light touch** over arms & legs
2) **pain & vibration** in hands & feet
3) **stereognosis**.

1. **Light touch (esthesia)** with fine cotton wisp – touch skin lightly (avoid any pressure on subcutaneous tissue) - ask patient to respond whenever you touch his skin.
"Respond whenever you feel a touch"
   - thresholds are increased in elderly.
   - *quantitative* assessment of light touch threshold - **SEMMES-WEINSTEIN nylon monofilaments** (standardized thickness creates specific force at point which monofilament bends after contact with skin).

2. **Pain (algesia):**
   1) **superficial pain** - ***adatėle*** ir ***buku daiktu*** – ask patient "Sharp or dull?".
   N.B. skausmą testuoja tik adatėlė, o bukas daiktas – only to check patient reliability!
   2) **deep pain** (ask patient to report as soon as he feels discomfort) - squeeze muscle bellies (e.g. calf, biceps) or apply pressure to finger or toe nail beds.
   Do not apply pressure with instrument, e.g. pen!

3. **Temperature** (nereikia, jei skausminiai jutimai normalūs) – du mėgintuvėliai su karštu ir šaltu vandeniu (arba tuning fork - viena kojelė šalta, kita pašildyta su ranka).
   - it is satisfactory if patient can identify as warm flask that is 35-36°C and as cool one that is 28-32°C.
   - between 28 and 32°C, most individuals can distinguish temperature differences in 1°C steps.

4. **Vibration**

- 128-256 Hz tuning fork is placed firmly over distal IP joints of finger and toe (examiner supports joint by placing his finger under patient's joint).
- ask patient what he feels (if uncertain whether patient feels pressure or vibration, ask him to tell you when vibration stops – when you stop fork vibrating with your fingers; examiner feels vibration through patient's joint and should note vibration end about the same time as patient);
"Do you feel vibration / buzzing?"
- after patient stops sensing, quickly move fork to identical spot on contralateral limb without striking it again (it is normal to perceive 3-5 additional seconds of vibration after such transference).

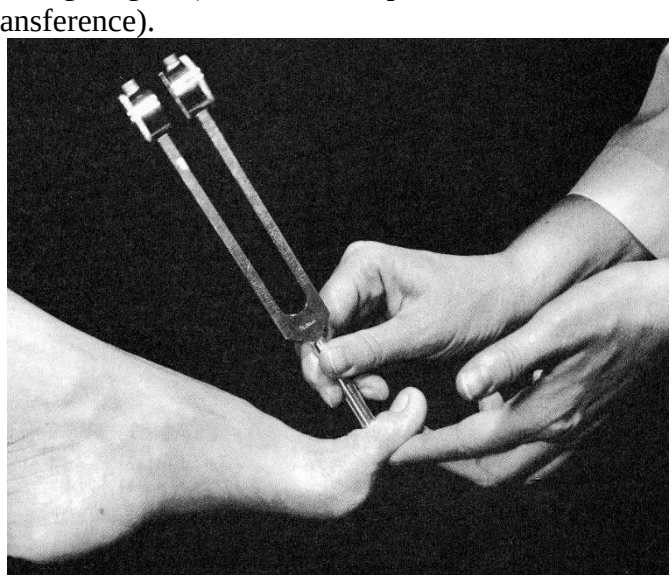

– jei pirštuose vibration sense is O.K., tai ir proksimaliau bus O.K.;
– *jei pirštuose vibration sense is impaired → proceed to more proximal bony prominences*: malleoli, anterior tibial area, anterosuperior iliac crest, sacrum, spinous process of vertebrae, sternum, clavicle, styloid processes of ulna or radius, epicondyli, skull.

N.B. vibration sense is often first sensation to be lost in ***peripheral neuropathy***! vs. in ***sensory cortex lesions*** vibration sense is most preserved!

N.B. vibration sense is often first sensation to be normally diminished in ***elderly***! (tuomet būtinai testuok position sense – jei nesutrikęs, tai tikrai normalūs amžiniai pokyčiai)

5. **Proprioreception (position sense)**
   1) **locate** limb in space
   2) **lankstyti** rankos ir kojos I ar IV piršto falangas (laikyti pirštą iš šonų!; avoid friction against neighbor fingers):
      – before testing, while eyes are open, demonstrate: "This is up, and this is down.
      – ask patient to close eyes and identify directions in random sequence of small movements (e.g. up, down, down, up).
      "Close your eyes and tell me which direction I am moving your big toe."
      – jei pirštuose position sense is O.K., tai ir proksimaliau bus O.K.;
      – *jei ligonis neteisingai** *nustato judesio kryptį, tiriami proksimalesni sąnariai*;

      – normal threshold is 5-10° in interphalangeal joint of index finger, 1° at shoulder;
      *patient with absence of position sense will have 50% error rate (answers that are consistently > 50% in error should be viewed with skepticism).
   3) rankoms tinka **finger-to-nose, finger-to-finger tests**
   4) kojoms tinka ir **Rombergo test**

- proprioceptive loss often produces PSEUDOATHETOSIS of outstretched limb.

6. **Discrimination** (all other types of primary sensation must be intact; patient's eyes closed) – testing ***sensory cortex***; always compare symmetric sites!!!
   a) ***STEREOGNOSIS*** (skrininginis tyrimas) - ligonis paima į ***delną*** daiktą (moneta, parkeris, sąvaržėlė, etc.) ir vartydamas delne jį atpažįsta (patient can manipulate object freely in hand but should not use contralateral hand at same time).
      - normally, familiar objects can be named within 5 seconds of contact.

      N.B. asking to distinguish "heads" from "tail" on coin is sensitive test of stereognosis!

   b) ***GRAPHESTHESIA, S. NUMBER IDENTIFICATION*** (kai pakenkta motorika ir negali atlikti stereognosis) - ant odos buku daiktu išbraižyti skaičių (numbers should be drawn large enough to occupy most of palm).
      - test areas: ***palm***, ***anterior forearm***, ***thigh***, ***lower leg***.
      - clearest figures for interpretation are 8, 4, 5; most difficult - 6, 9, 3.

   c) ***TOPESTHESIA, S. POINT LOCALIZATION*** - paliesti odą, ligonis atsimerkia ir pirštu parodo (ar pasako), kur tai buvo padaryta.

   d) ***BARESTHESIA*** - place two objections of different weight in sequence in patient's ***hand*** and have him identify which is heavier.

   e) ***TWO-POINT DISCRIMINATION*** – using sides of two pins touch ***finger pad*** in two places simultaneously (alternate irregularly with one-point touch) – find minimal distance which patient can discriminate one from two points (norma 2-3 mm).

      distances↑ - in sensory cortex lesions or innervation density↓ [as in neuropathy]

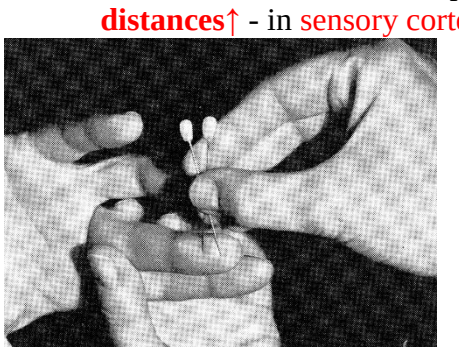



   f) ***EXTINCTION*** (testing for HEMINEGLECT) – simultaneously stimulate symmetrical areas on both body sides – ask patient where he feels touch (normally should feel both stimuli; parietal cortex lesion – only one stimulus may be recognized).

      N.B. if affected side is stimulated in isolation, it is recognized normally!

      e.g. touch ***back of each hands*** in turn and ask which has been touched; now touch both hands simultaneously and ask whether left, right or both sides were touched.

Areas that normally are less sensitive to touch:
1) antecubital fossa, supraclavicular fossa, neck.
2) areas of thicker skin (e.g. elbow, regions covered by calluses).

Radus jutimo sutrikimus, būtina tiksliai **surasti ribas** nuo pakitusio taško judant proksimalyn.
- taisyklė – judama nuo patologinės zonos link normalios (people are much more sensitive to appearance of sensation than to its disappearance).
- level of ***spinal lesion*** is more likely to be indicated by cutaneous sensory loss than by motor signs!
- dermatomal vs. peripheral nerve pattern – by mapping altered sensation areas:

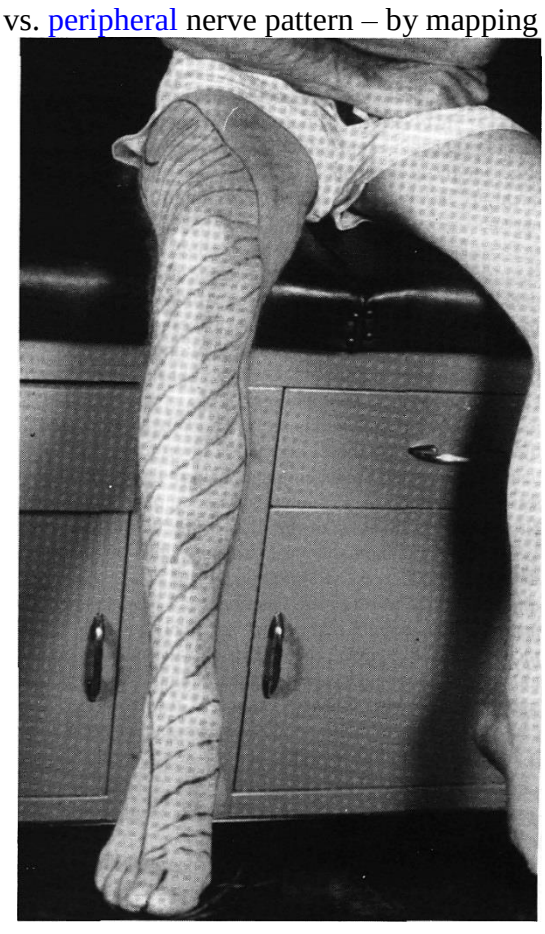

Fasc. gracilis et cuneatus – vibracija, propriorecepcija, taktiliniai (diksriminaciniai).
Tr. spinothalamicus – t-ra, pain, taktiliniai (nediskriminaciniai).
Sensorinė žievė – diskriminacija.

LHERMITTE sign (spinal posterior column demyelination): neck flexion (stretches and irritates damaged fibers in dorsal columns of cervical spine) → electric-shock-like feeling that travels down spine or into extremities.

SPURLING test (cervical root disease): patient is seated, extended neck is rotated and laterally flexed to side of symptoms → careful pressure applied to top of head in downward direction → exacerbation of pain / numbness in upper extremity.

Axial loading test (cervical disk pathology): patient standing; examiner pushes down on patient's head → neck pain:

CUTANEOUS INNERVATION

DERMATOMES see p. also PN1 >> (radiculopathy)

C1 – no such dermatome!
interaural line – border between C2 and n. ophthalmicus

C2 – occiput
C3 – neck, thyroid cartilage
C4 – clavicle, suprasternal notch
(**C3-4** – cape area)
C5 – below clavicle
C6 – 1st-2nd fingers
C7 – 3rd finger
C8 – 4-5th fingers

C4(5) abuts on **T2(1)**

T2 – axilla
T4 – nipple
T10 – umbilicus

L1 – inguinal (femoral pulse)
L2 – medial thigh
L3 – medial-anterior knee
L5 – big toe

S1 – little toe, lateral heel
S2 – popliteal fossa
S2-Cx converge on coccyx (bull's eye) not anus!

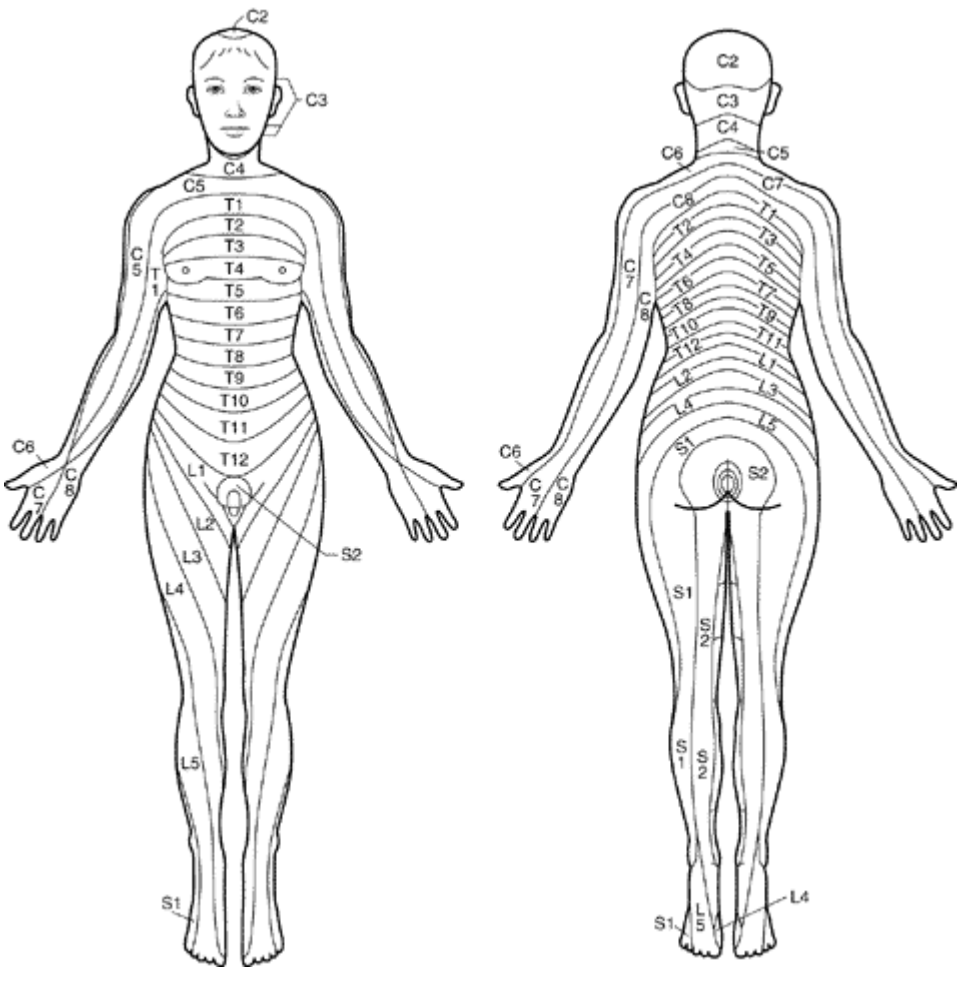

N.B. as one passes from one skin area to adjacent area supplied by much higher spinal segment*, it is normal for patient to sense sudden increase in stimulus at point of segmental border.
*e.g. on chest where dermatomes C4 and T2 abut.

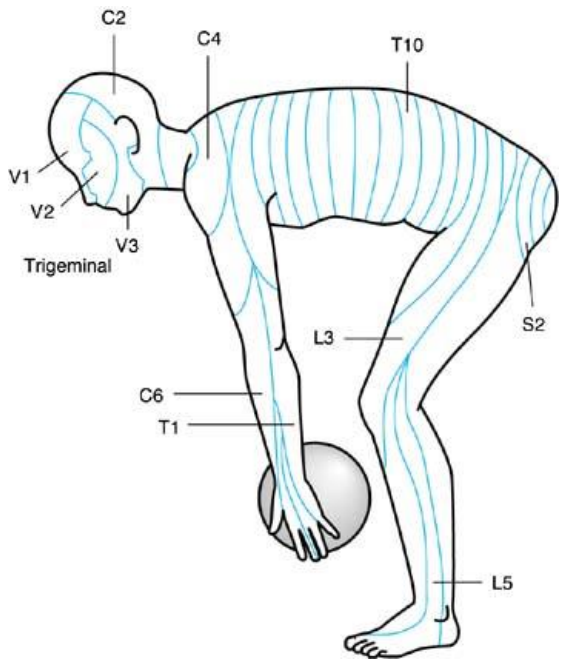

Cutaneous Nerve Distributions (upper limb):

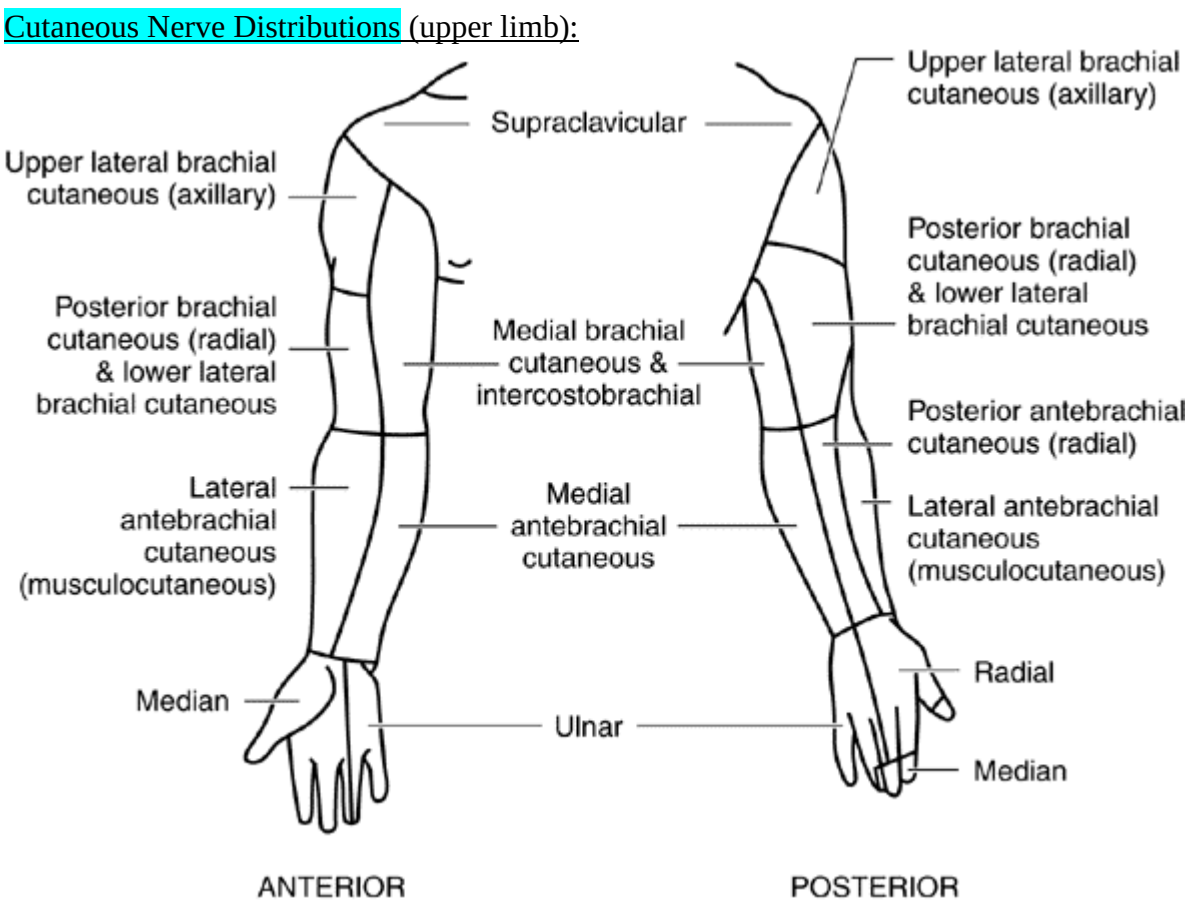

Cutaneous Nerve Distributions (lower limb):

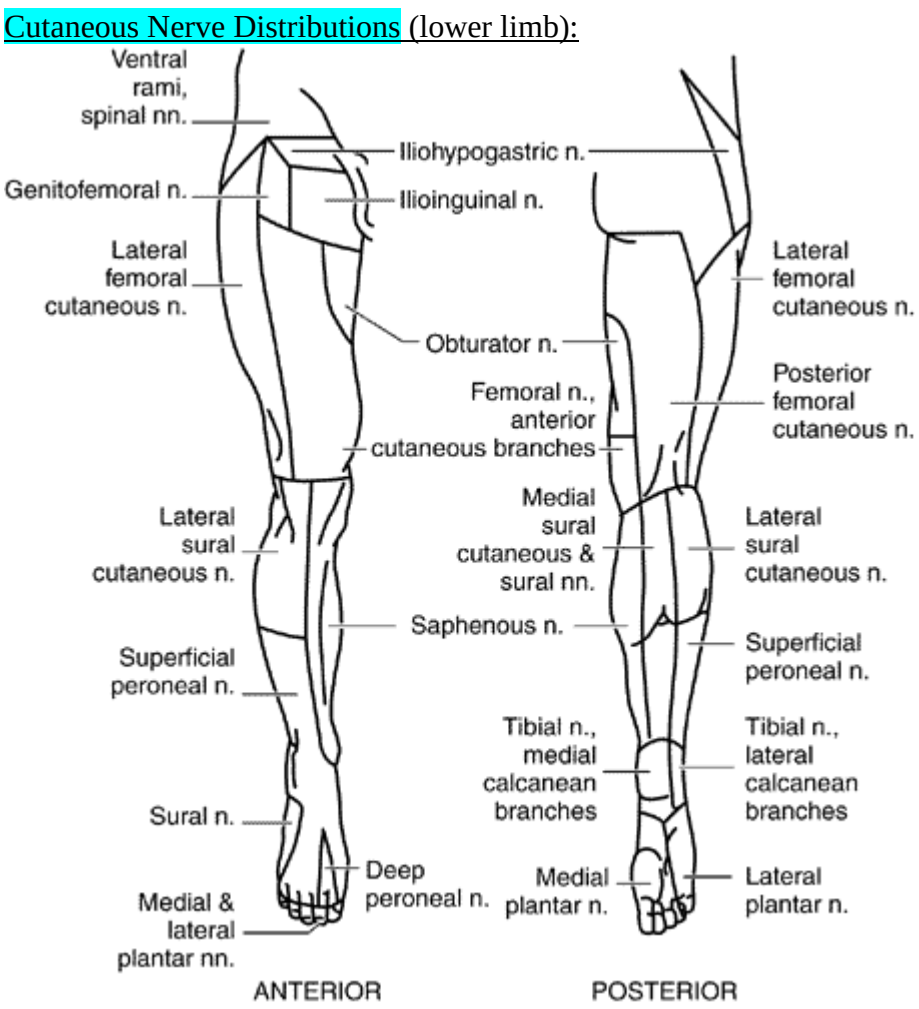

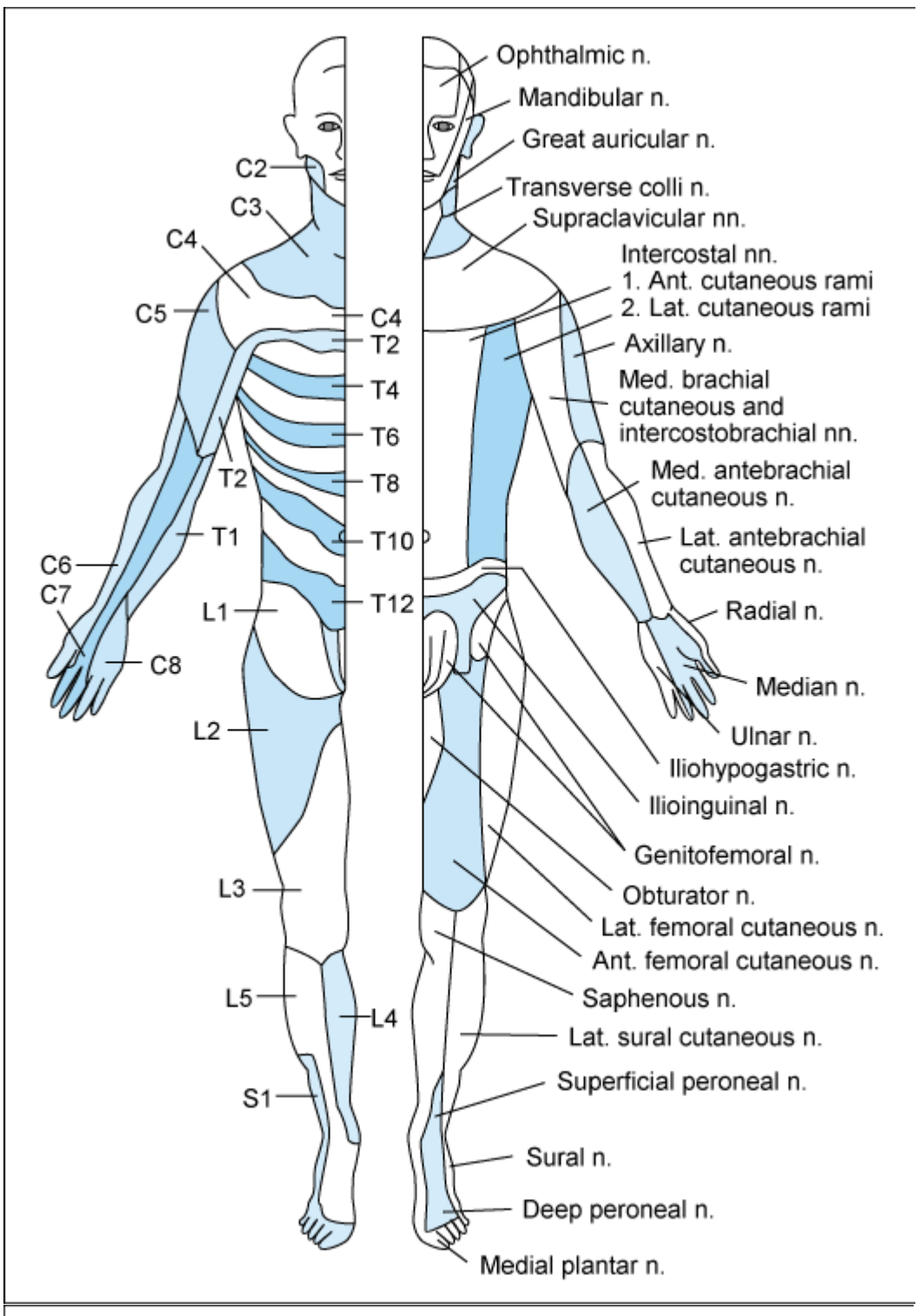
C2
C3
C4
C5
C4
T2
T4
T6
T2
T8
T1
T10
C6
C7
L1
T12
C8
L2
L3
L5
L4
S1
Ophthalmic n.
Mandibular n.
Great auricular n.
Transverse colli n.
Supraclavicular nn.
Intercostal nn.
1. Ant. cutaneous rami
2. Lat. cutaneous rami
Axillary n.
Med. brachial cutaneous and intercostobrachial nn.
Med. antebrachial cutaneous n.
Lat. antebrachial cutaneous n.
Radial n.
Median n.
Ulnar n.
Iliohypogastric n.
Ilioinguinal n.
Genitofemoral n.
Obturator n.
Lat. femoral cutaneous n.
Ant. femoral cutaneous n.
Saphenous n.
Lat. sural cutaneous n.
Superficial peroneal n.
Sural n.
Deep peroneal n.
Medial plantar n.

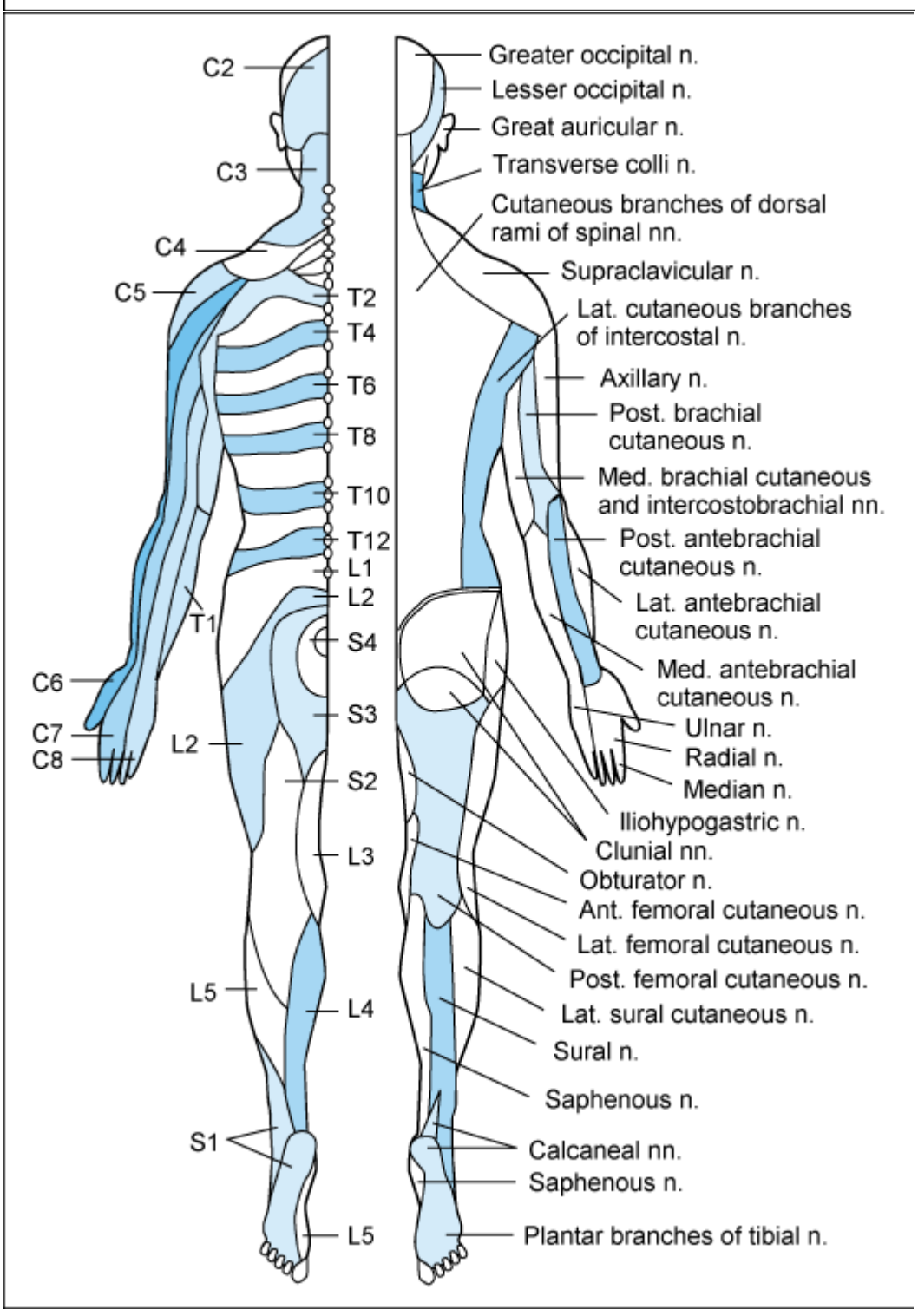
C2
C3
C4
C5
T2
T4
T6
T8
T10
T12
L1
L2
T1
S4
C6
S3
C7
C8
L2
S2
L3
L5
L4
S1
L5
Greater occipital n.
Lesser occipital n.
Great auricular n.
Transverse colli n.
Cutaneous branches of dorsal rami of spinal nn.
Supraclavicular n.
Lat. cutaneous branches of intercostal n.
Axillary n.
Post. brachial cutaneous n.
Med. brachial cutaneous and intercostobrachial nn.
Post. antebrachial cutaneous n.
Lat. antebrachial cutaneous n.
Med. antebrachial cutaneous n.
Ulnar n.
Radial n.
Median n.
Iliohypogastric n.
Clunial nn.
Obturator n.
Ant. femoral cutaneous n.
Lat. femoral cutaneous n.
Post. femoral cutaneous n.
Lat. sural cutaneous n.
Sural n.
Saphenous n.
Calcaneal nn.
Saphenous n.
Plantar branches of tibial n.

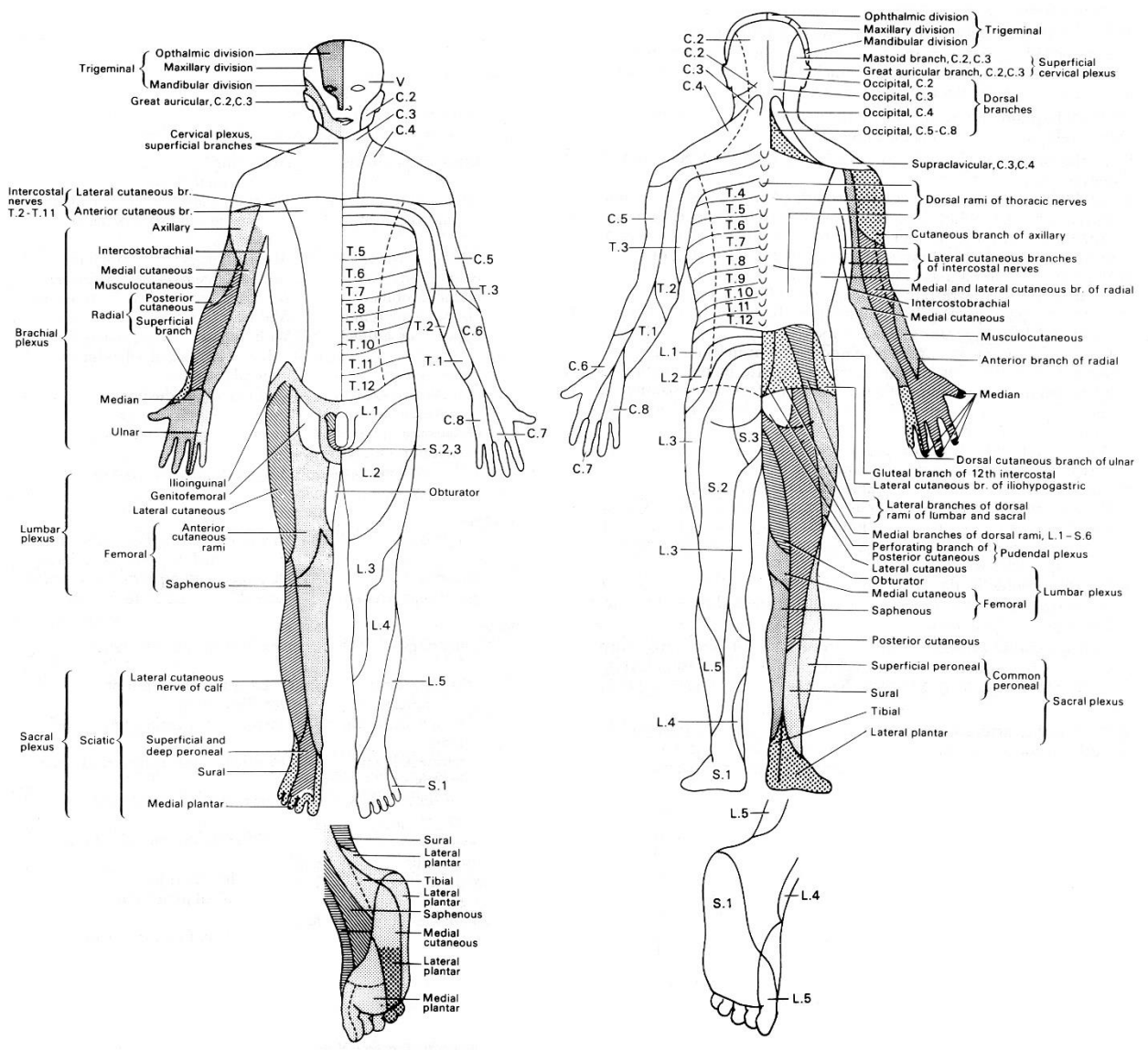
Trigeminal
Opthalmic division
Maxillary division
Mandibular division
Great auricular, C.2,C.3
Cervical plexus, superficial branches
Intercostal nerves T.2-T.11
Lateral cutaneous br.
Anterior cutaneous br.
Axillary
Intercostobrachial
Medial cutaneous
Musculocutaneous
Radial
Posterior cutaneous
Superficial branch
Brachial plexus
Median
Ulnar
Ilioinguinal
Genitofemoral
Lateral cutaneous
Lumbar plexus
Femoral
Anterior cutaneous rami
Saphenous
Obturator
Sacral plexus
Sciatic
Lateral cutaneous nerve of calf
Superficial and deep peroneal
Sural
Medial plantar
Mastoid branch, C.2, C.3
Great auricular branch, C.2,C.3
Superficial cervical plexus
Occipital, C.2
Occipital, C.3
Occipital, C.4
Occipital, C.5-C.8
Dorsal branches
Supraclavicular, C.3,C.4
Dorsal rami of thoracic nerves
Cutaneous branch of axillary
Lateral cutaneous branches of intercostal nerves
Medial and lateral cutaneous br. of radial
Intercostobrachial
Medial cutaneous
Musculocutaneous
Anterior branch of radial
Median
Dorsal cutaneous branch of ulnar
Gluteal branch of 12th intercostal
Lateral cutaneous br. of iliohypogastric
Lateral branches of dorsal rami of lumbar and sacral
Medial branches of dorsal rami, L.1-S.6
Perforating branch of Posterior cutaneous
Pudendal plexus
Lateral cutaneous
Obturator
Medial cutaneous
Saphenous
Femoral
Lumbar plexus
Posterior cutaneous
Superficial peroneal
Common peroneal
Sural
Tibial
Lateral plantar
Sacral plexus
Lateral plantar
Tibial
Saphenous
Medial cutaneous
Medial plantar

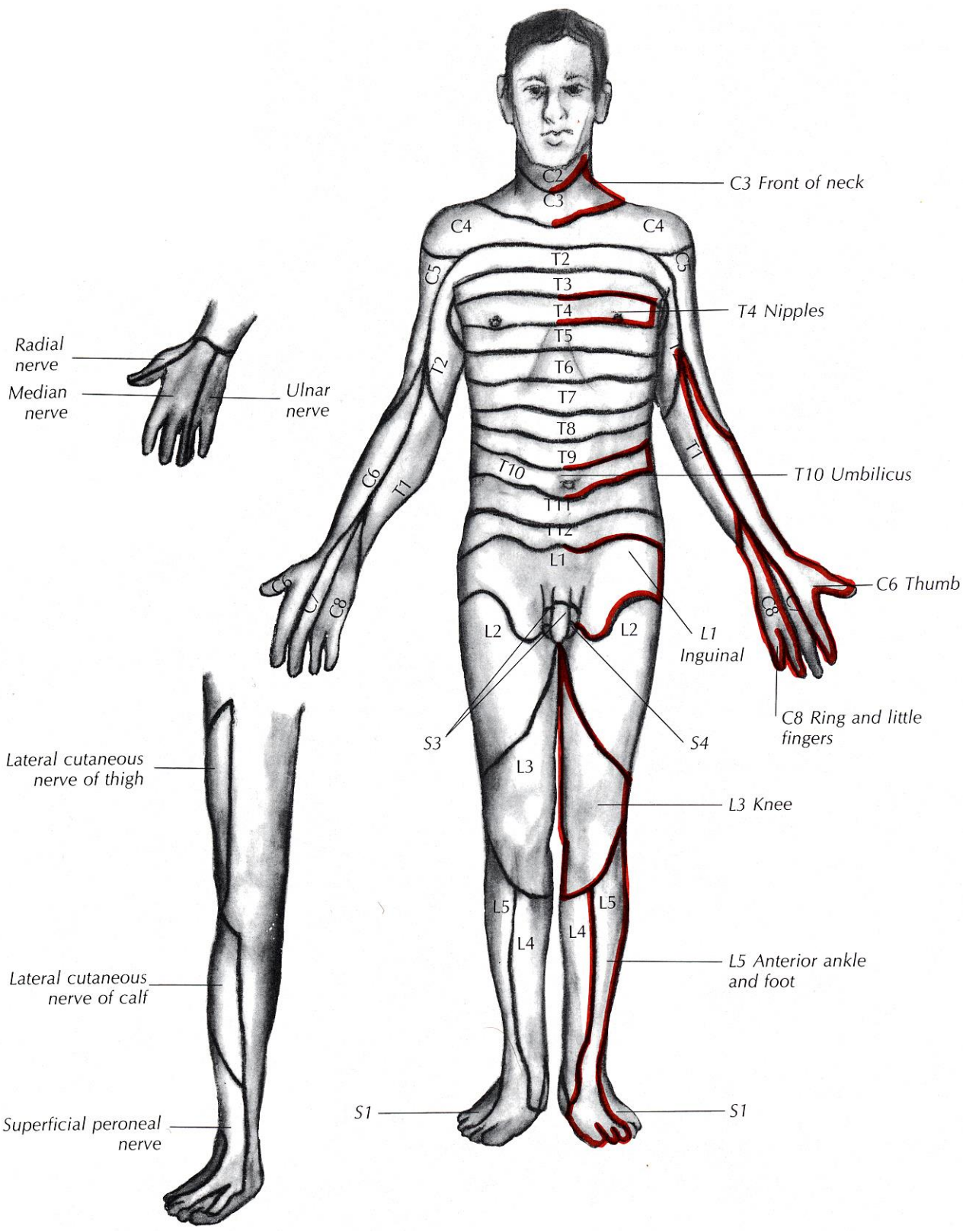
C3 Front of neck
T4 Nipples
T10 Umbilicus
C6 Thumb
C8 Ring and little fingers
L1 Inguinal
S3
S4
L3 Knee
L5 Anterior ankle and foot
S1
S1
Radial nerve
Median nerve
Ulnar nerve
Lateral cutaneous nerve of thigh
Lateral cutaneous nerve of calf
Superficial peroneal nerve

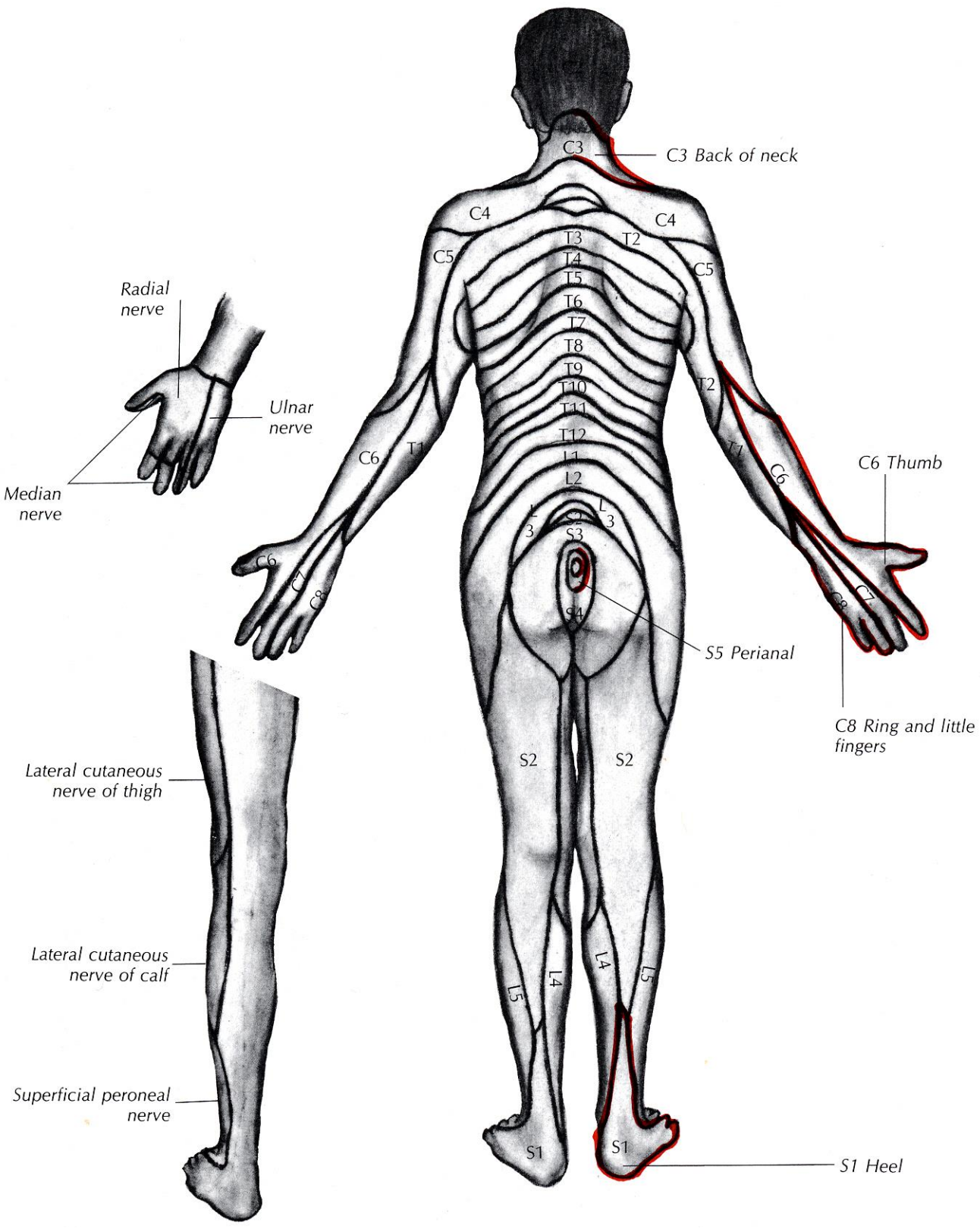

DETECTION OF SENSORY MALINGERING

N.B. it also applies to nonorganic sensory disorders (e.g. conversion reaction in hysteria).

CLUES:

1) zone hyperesthetic for one sensation and anesthetic for another.
2) anesthesia with sharp (!) demarcation that does not fit any peripheral nerve or dermatome in hands or feet ("glove and stocking" with very sharp line of demarcation at joint lines).
3) anesthesia exactly to midline (esp. midline change for vibration sense over bony areas).
4) absolute loss of all cutaneous sensation.
5) loss of hearing and vision on same side as skin anesthesia (pansensory loss).
6) hyperesthesia that resolves with mild distraction.
7) marked variation with repeated examination.
8) preserved function despite dramatic sensory findings (no clumsiness or ataxia, and gait is unaffected).

DIAGNOSTIC METHODS (patient eyes closed!!!):

1. Ask patient to respond **"yes"** when he believes that stimulus has been applied and **"no"** when he does not feel that stimulus was applied - must be done quickly and only once!
   malingering patient may be identified such that timing of answer "no" exactly coincides with each stimulus contact.
2. Mark boundaries of alleged anesthetic ***area*** with pen; when testing is **repeated** at short intervals alleged area will be found to vary considerably.
3. **Zig-zag test** - ***border*** of hypesthetic or anesthetic zone is marked; start again at periphery of limb and work upward with stimulus in zig-zag fashion.
   in malingering patient, border may shift downward (and repeated tests will continue to bring it lower) - patient is led to feel greater distance has been covered in straight line reference.
4. **Draw figures** of different shapes on patient's skin; figures are drawn such that part of outline falls within alleged anesthetic area and part without.
   malingering patient may correctly identify figure even when critical portion of figure necessary for identification is drawn within alleged anesthetic area.
5. **Cross patient's hands & fingers behind back** and then proceed to test sensibility.
   in malingering patient observer may see bending of alleged insensible finger as it is touched or hesitation in responding to stimulus.
6. **Withdrawal from pinprick** is one of least useful modalities (because some patients may withstand great pain without withdrawal!).

MOTOR EXAMINATION

LESION LOCALIZATION GUIDE → see p. Mov3 >>

It is axiomatic that patients typically have **motor** signs before* motor symptoms** and, conversely, **sensory** symptoms before sensory signs.

*patients with even severe weakness may not report symptoms of weakness!
**usually reported by patient in terms of loss of specific functions (i.e. difficulties with specific tasks).

N.B. symptom of "weakness" *without findings of weakness on examination* is not usually result of neuromuscular disease but can be sign of neurologic disease ***outside motor unit*** or more commonly symptom of disease ***outside nervous system*** altogether!

N.B. pain presence may invalidate motor examination!

If it is not possible to perform formal motor testing (patient is not cooperative or is comatose):
for details see p. S30 >> (motor asymmetry)

1) motor movement should be elicited by *application of noxious stimuli* – record any movement of extremities (kuriomis galūnėmis ginasi nuo skausmo, ant kurio šono spontaniškai gulasi ir pan.).
   N.B. voluntary purposeful movement must be distinguished from abnormal motor posturing (decorticate, decerebrate)!
2) check for *muscle tone* letting limb passively to fall down.

<u>False localizing motor examination</u> – see p. S30 >>

1. SOMATOTYPE (BODY GESTALT), MUSCLE BULK

- patient in state of sufficient undress.
- skriningui – **pelvic & shoulder girdles, hands** (thenar, hypothenar, spaces between metacarpals).
  - *upper extremities* should be inspected in both pronated and supinated positions (differences in extensor and flexor compartments of forearm).
  - *lower extremities* should be observed from front and back while patient is standing.
- if asymmetry is apparent → bulk of muscle groups is ***measured objectively*** by measuring girth and comparing sides:
  - point (at which circumference is to be measured) is marked with ballpoint pen, usually at point of greatest estimated girth.
  - to find same site on opposite limb, distance to closest bony landmark is measured, and that measurement is used on opposite limb.
  - muscle bulk is greater in dominant limb.
  - normal difference between sides: ≤ 1.0 cm in leg & thigh, ≤ 0.5 cm in forearm & arm.
- in most cases, significant asymmetry indicates ATROPHY (in some cases, it may be unusual HYPERTROPHY or PSEUDOHYPERTROPHY).

MUSCLE ATROPHY

a) ***neurogeninė*** – periferinis paralyžius.
b) ***miogeninė*** – miopatija.
c) ***artrogeninė*** – ankilozė.

N.B. mild atrophy of hand muscles may be due to *aging* (sarcopenia).

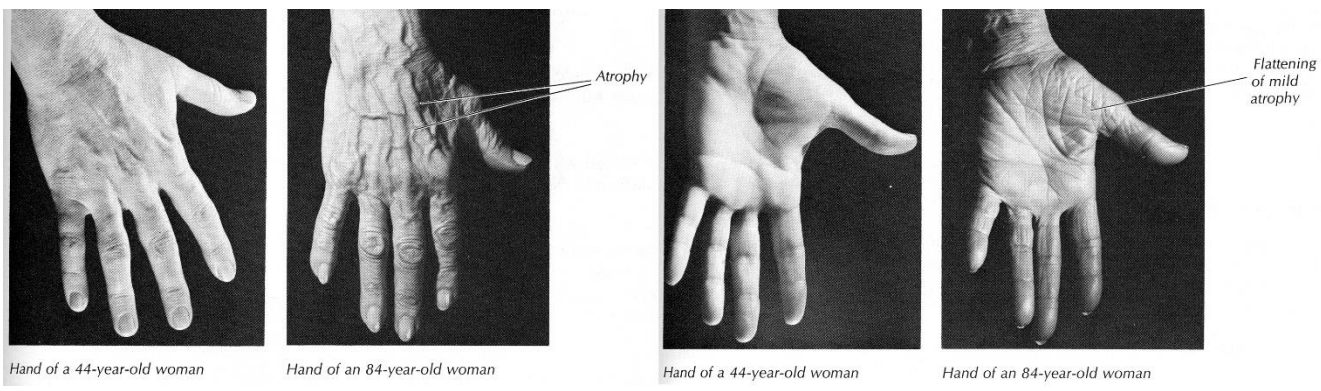

MUSCLE HYPERTROPHY

- differentiate from PSEUDOHYPERTROPHY (muscle tissue replaced by excessive fibrous tissue or storage material) - generally **symmetrical** and involves **calves** (compare muscle bulk ***between upper and lower extremities***!).

2. ABNORMAL MOTOR ACTIVITY

FASCICULATIONS

- observe relaxed limbs that are illuminated from behind.
- **place to look** for fasciculations depends on subcutaneous tissue amount:
  - thin elderly men - shoulder girdle and pectoral muscles are often good.
  - more adipose people - first dorsal interosseous muscle of hand.
  - fasciculations are best observed in ***relaxed tongue*** (no subcutaneous tissue separates muscular layer from epithelium).
- forcible contraction or muscle percussion may **increase frequency** of fasciculations.

N.B. fasciculations are commonly experienced as benign phenomenon in absence of any disorder! <u>Motor neuron disease never starts with fasciculations alone</u>!

DYSKINESIAS (tremor, chorea, athetosis, dystonia, etc.) - primary testing conditions:

1) **REST** - sitting quietly in comfortable position (extremities fully relaxed and supported so that patients are not holding posture); when engaged in conversation, most normal individuals have spontaneous hand gestures, often cross one leg over other, and smile when chatting.
   N.B. **sitting** position is one of rest for *extremities*, but one of activation for *trunk* and *neck* muscles (if you need to relax them also – use **lying supine** position!)
   - if ***myoclonus*** or heightened ***startle reflex*** is suspected, investigator should suddenly clap hands or drop book on floor to surprise patient.

2) **STATIC POSTURE** – observe ***postural tremor***, ***chorea***, ***myoclonic jerks***, ***dystonic tremor*** (patient's own compensatory movement to overcome dystonia - therefore tremor is maximized in position that opposes natural dystonic contraction).
   - ***'flapping tremor' (asterixis)*** (hepatic failure or CO_2 retention) may be apparent only when arms are outstretched with hands dorsiflexed:

3) **VOLITIONAL ACTIVITY**:
   finger tapping:
   - slow and cramped in hypokinesia;
   - sloppy and overridden with additional movements in chorea;
   - may precipitate spasm of contorted hand posture in dystonic.

   handwriting:
   - bradykinesia causes small and cramped parkinsonian script (micrographia);
   - action tremor causes large, tremulous signature;
   - dystonia induces irregular script and often patient will need to adjust pen several times because of painful spasms or involuntary dystonic movements.

   finger-to-nose task helps differentiate tremors.
   speech - to detect dysarthria, hypophonia, language disorders; talking is common motor act that induces overflow dystonic movements elsewhere in body.
   Movement disorders of all types can affect production and clarity of speech!!!
4) **WALKING**

3. MUSCLE TONE

- ask patient to ***relax completely*** (it is useful to distract patients attention; room must be warm!).
- patients vary in **ABILITY TO RELAX**:
  - it is easier to relax ***lower extremities*** in sitting position, whereas ***upper limbs*** can be examined in either sitting or lying position.
  - *mildly demented elderly people* tend to voluntarily help move limb in desired direction.

– *pain* or *bone / joint abnormalities* may cause resistance to passive movement.
– in completely relaxed patient, no resistance should be felt at wrist and elbow, and minimal resistance at shoulder, knee, and ankle.
N.B. **limitation of joint range of motion** or **painless swelling of joints** is often sign of unsuspected neurologic lesion!

- move each joint through full range of flexion and extension – first **slowly**, then **quickly**.
- *compare sides!* (minimal but pathological increase in tone may initially be considered normal until one compares it with normal side)

UPPER EXTREMITIES: hold patient's hand as if shaking hands, using your other hand to support patient's elbow → rotate forearm, flex and extend wrist, elbow and shoulder
Vary speed and direction of movement!

- flexion of wrist can be compared by noting distance thumb can be brought to flexor aspect of forearm.
- shake forearm and observe floppiness of movements of hand at wrist.
- with arms raised overhead, compare degree of flexion or limpness of wrist on each side.

LOWER EXTREMITIES:

1) begin by rolling or rotating leg from side to side:

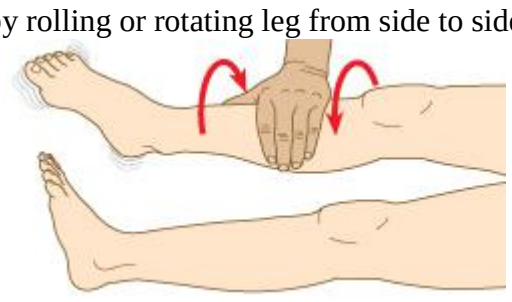

2) briskly lift knee into flexed position, then extend:

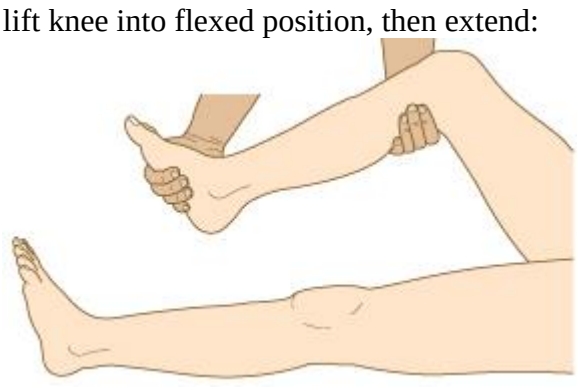

3) flex-extend ankle:

- place your hands behind thighs and rapidly raise them after instructing patient to let leg flop:
  a) **normal tone** - heel may come off bed slightly and transiently and then drag along sheet; heel drags along table surface for variable distance before rising.
  b) heel of **flaccid leg** will be dragged across bed from very beginning.
  c) **increased tone** - immediate heel lift off surface and never fall back to bed.

TONUS↓ - A(HYPO)TONIA (S. FLACCIDITY)
TONUS↑: see p. Mov3 >>
a) SPASTICITY
b) RIGIDITY
c) PARATONIA / GEGENHALTEN

4. MUSCLE STRENGTH

Power may be examined in variety of ways:

A. **Direct testing** - patient is asked to push or pull in specified direction against resistance of physician - strength in *each muscle group is graded* 0 ÷ 5 by scale developed by Medical Research Council.
B. **Observation of task performance** - useful in detecting *mild, asymmetric weakness*.
C. **Functional testing with quantitation** (e.g. *counting* number of times person can perform deep-knee bend or *timing* length of time arms can be held abducted to 90 degrees) - provides *reproducible data* for assessment of changes over time.

RAUMENŲ JĖGOS SKALĖ (Medical Research Council rating of muscle strength) - maximum force generated by effort to move involved body area:

0 - no contraction (paralysis)
1 - palpable muscle contraction, no limb movement (paresis)
2 - active movement in gravity-neutral plane (paresis)
3 - active movement against gravity (paresis)
4 - active movement against gravity and resistance (paresis)
5 - normal power

[skalės trūkumas – large range in strength between grades 4 and 5; todėl kai kas dar naudoja papildomus balus: 4- ir 4+]

1) **UPPER EXTREMITIES:** Arm (strength).avi >>

– **triceps**, **biceps**:

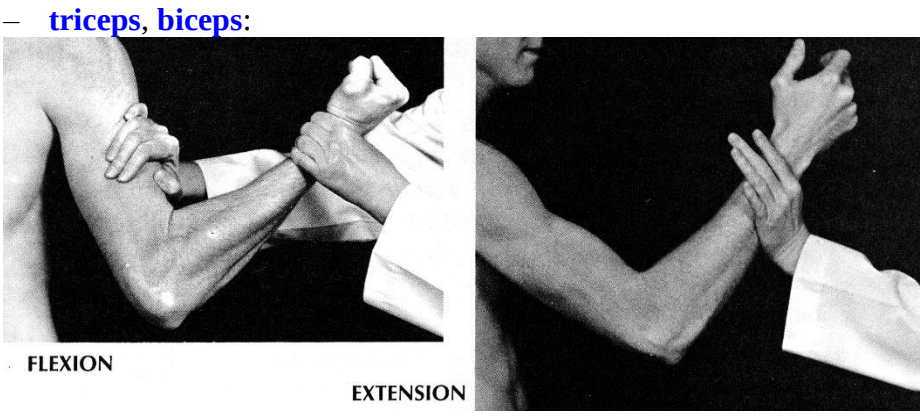

– **wrist flexion, extension**
– **hand grip** (duok suspausti savo II ir III pirštus sudėtus vieną ant kito; paprastai tiriame abi puses simultaniškai), **finger abduction & extension**;

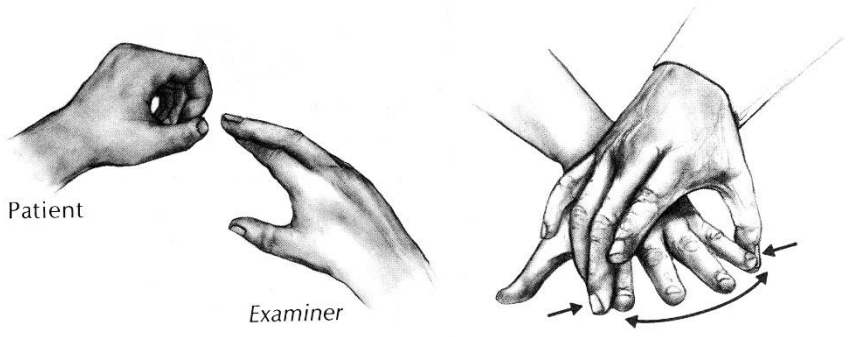

– **finger adduction & thumb opposition** (instruct patient to hold his thumb tightly against his fingertips; pull your thumb between his thumb and fingers):

2) **SHOULDER GIRDLE** - priešinamės abdukcijai; lėtai spaudžiame abdukuotą žastą prie liemens (scapula alata - m. serratus ant. silpnumas); priešinamės addukcijai.

3) **excursions** of **RIB CAGE**.

4) **ABDOMINAL MUSCLES** – have supine patient do **sit-up** or just **raise head** (watch for umbilical migration upward – **Lord BEEVOR sign** – paralyzed lower abdominal muscles, but intact upper muscles).

5) **LOWER EXTREMITIES** – test hip flexors, abductors, adductors, knee flexors, foot inverters and everters:

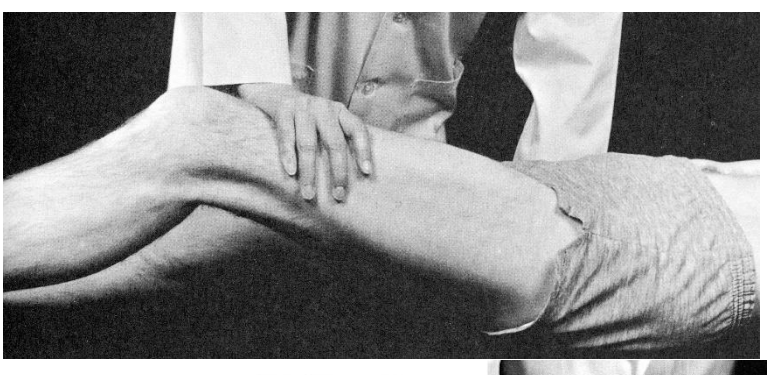

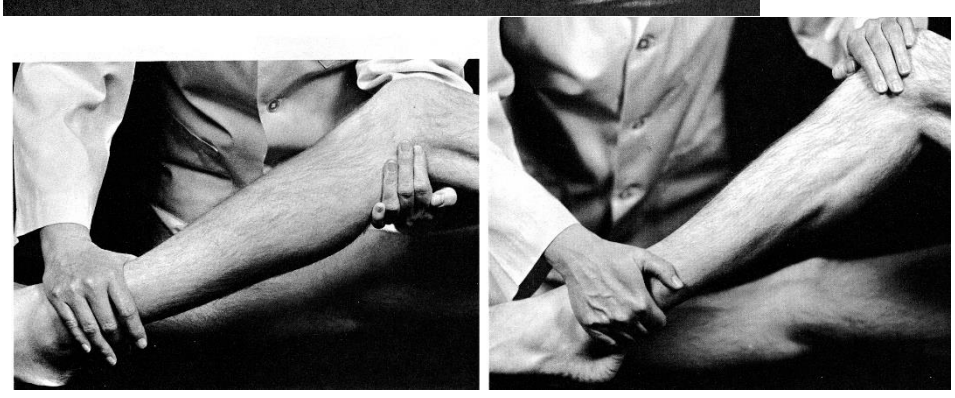

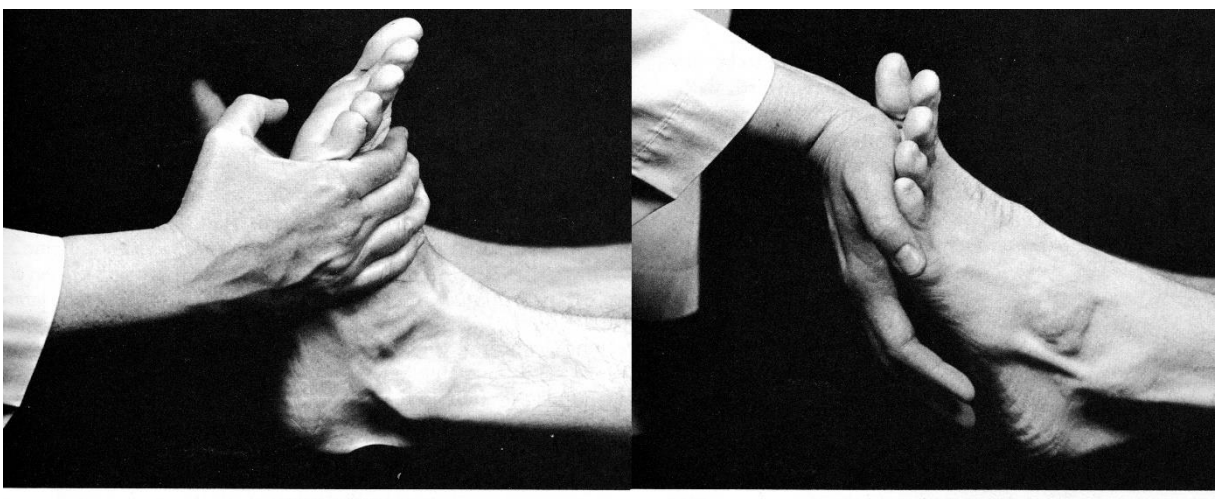

DORSIFLEXION PLANTAR FLEXION

Knee extensors are tested by deep knee bend, plantar flexors – by toe walking, foot dorsiflexors – by heel walking.

6) **tests to detect mild paresis**:

Upper BARRÉ sign – patient is asked to extend arms in fully supinated position while keeping eyes closed; mildly paretic arm gradually becomes pronated and sometimes flexed and drifts downward ("*pronator drift*").

Lower BARRÉ sign – patient is placed in prone position with limbs flexed at knees; paretic limb is unable to maintain flexed position and leg extends.

Digiti quinti minimi sign (hyperabduction of outstretched fifth finger on paretic side).

Forearm rotator sign - patient rotates forearms around each other; paretic arm tends to stay fixed while good arm rotates around it.

7) **objective measurements** - DINAMOMETRIJA (e.g. handgrip ergometer or by having patient squeeze inflated BP cuff).

Symmetric weakness:
proximal – MYOPATHY*, distal – POLYNEUROPATHY**

*exception - **Kugelberg-Welander syndrome**
exception – **myotonic dystrophy (affects distal limbs)

NEUROGENIC weakness: atrophy > weakness; initially affects distal muscle groups; reflexes early absent; fasciculations ± sensory changes.

MYOGENIC weakness: weakness > atrophy; initially affects large proximal muscle groups; reflexes long present (diminish in proportion to weakness degree); no fasciculations & sensory loss.

NEUROMUSCULAR JUNCTIONAL disorders: fatigable weakness (initially in extraocular and bulbar muscles); reflexes present; no atrophy, no fasciculations.

HYSTERICAL weakness - normal resistance to movement, followed by sudden giving way!

Hypotonia may be associated with normal strength or with weakness;
Enlarged muscles may be weak or strong;
Thin, wasted muscles may be weak or have unexpectedly normal strength.

5. FUNCTIONAL MOVEMENTS

- *bring out more subtle deficits* escaping detection when muscle strength is tested against resistance.

1) ***walking*** (gait observation is essential component of neurologic examination!!!); observe patient in following sequence:
   - SITTING (to make sitting balance more challenging, ask subject to sit on examining table with arms and legs not touching any support surface);
   - ability to ARISE FROM CHAIR;
   - STANDING unaided (static balance); note distance between feet (indicator of lateral stability)!
   - GAIT at slow then fast pace;
   - passage through NARROW SPACES, DISTRACTIONS, TURNS;
   - TANDEM WALKING heel-to-toe in straight line (tests lateral stability - indicator of cerebellar and vestibular dysfunction);
   - PUSH PATIENT TO SIDE and PULL HIM BACKWARD (tests reactive postural responses).
2) ***hopping in one place on either feet*** – puikus skriningas - jei atlieka normaliai, vadinasi motorinė sistema & smegenėlės & propriorecepcija & praxis nepakenkti.
3) ***toe walking***, ***heel walking***, ***make tight fist*** – DISTAL MUSCULATURE
   weakness of foot dorsiflexion (L_5 lesion) reduces ability to walk on heels;
   weakness of gastrocnemius (S_1 lesion) diminishes ability to rise on toes.
4) ***lift arms over head***, ***deep knee bends***, ***rising from deep chair*** – PROXIMAL MUSCULATURE.
5) ***rising from supine position*** (look for **GOWERS sign** → see p. D5 >>).

6. FATIGABILITY

(jei įtariama iš anamnezės) - **REPEAT SIMPLE TASKS**:

a) mirkčioti akimis 100 kartų.
b) skaičiuoti balsu iki 30.
c) **JOLLY test** - patient repetitively squeezes inflated ***blood pressure cuff***; height of excursions of mercury manometer are monitored (decrement in pressure produced by each squeeze is readily appreciated).
d) **TENSILON (EDROPHONIUM) test** → see p. Mus1 >>

7. MYOTONIC MANEUVERS

a) **direct muscle percussion**:
   - in *normal muscle*, tap produces such brief contraction and relaxation that it is not seen.
   - in *myotonic muscle* contraction remains as dimple for few seconds before contraction subsides; in smaller muscle such as thenar eminence, contraction is strong enough to produce adduction of thumb.
b) **forceful grip**; myotonia patient has marked difficulty in relaxing and opening fingers.
c) **myotonia in eyelids** - ask patient to look upward and then rapidly look down; this produces pronounced lid lag.
d) press edge of wooden blade against **tongue dorsal surface** → deep furrow that disappears slowly.

8. SYNKINESIA (MIRROR MOVEMENTS)

- most often seen in children with cerebral palsy:

a) ***globalinės*** (paryškėja V-M poza, kliudant sveikajai).
b) ***imitacinės*** (juda nesveika, kliudant sveikajai).
c) ***koordinacinės*** (atliekant judesius per paralyžuotus sąnarius, juda ir kiti nesveiki sąnariai).
d) ask patient to produce rapid alternating movement of hand; when he does so, it will be ***mirrored*** by same movement in opposite hand.

MOTOR SEGMENTS

also see p. PN1 >> (radiculopathy)

Myotome	Muscle (nerve)	Testing
UPPER LIMB		
C_{3-4}	trapezius (**spinal accessory n.**)	shrug shoulder, adduct scapula
BRACHIAL PLEXUS:		
C_{4-5}	rhomboids (**dorsal scapular n.**)	brace shoulder back
C_5	supraspinatus (**suprascapular n.**)	abduct arm first 15°
C_{5-6}	infraspinatus (**suprascapular n.**)	externally rotate arm, flexed elbow at side (only muscle responsible for external rotation of humerus!)
	subclavius (**subclavian n.**)	
	subscapularis (**subscapular n.**)	
	teres major (**subscapular n.**)	
	teres minor (**axillary n.**)	
	deltoid (**axillary n.**)	abduct arm between 15° and 90°
	biceps (**musculocutaneous n.**)	flex supinated forearm
	levator scapulae (**dorsal scapular n.**)	
	pectoralis minor (**medial pectoral n.**)	
C_{5-7}	pectoralis major, clavicular head (**lateral pectoral n.**)	adduct arm from above horizontal and forward
	serratus anterior (**long thoracic n.**)	push forward against resistance
C_6-T_1	pectoralis major, sternocostal head (**medial pectoral n.**)	adduct arm below horizontal
C_{6-8}	latissimus dorsi (**thoracodorsal n.**)	adduct horizontal and lateral arm
RADIAL NERVE:		
C_{5-6}	supinator	arm by side, resist hand pronation
	brachioradialis	flex elbow with forearm half-way between pronation and supination
C_{6-7}	extensor carpi radialis longus	extend wrist to radial side with fingers extended
C_{7-8}	triceps	extend elbow against resistance
	extensor digitorum	keep fingers extended at MCP joint
	extensor carpi ulnaris	extend wrist to ulnar side
	abductor pollicis longus	abduct thumb at 92° to palm
	extensor pollicis brevis	extend thumb at MCP joint
	extensor pollicis longus	resist thumb flexion at MCP joint
MEDIAN NERVE:		
C_{6-7}	pronator teres	keep arm pronated against resistance
C_{6-8}	flexor carpi radialis	flex wrist towards radial side

C_7-T_1	flexor digitorum superficialis	resist extension at PIP joint (while you fix his proximal phalanx)
C_8-T_1	flexor digitorum profundus I-II	resist extension at DIP joint
	flexor pollicis longus	resist thumb extension at IP joint (fix proximal phalanx)
	abductor pollicis brevis	abduct thumb (nail at 90° to palm)
	opponens pollicis	thumb touches 5th finger-tip (nail parallel to palm)
	lumbricales I-II	extend PIP joint against resistance with MCP joint held hyper-extended
ULNAR NERVE:		
C_{7-8}	flexor carpi ulnaris	abduct little finger, see tendon when all fingers extend
C_8-T_1	flexor digitorum profundus III-IV	fix middle phalanx of 5th finger, resisting extension of distal phalanx
	dorsal interossei	abduct fingers (use index finger)
	palmar interossei	adduct fingers (use index finger)
	adductor pollicis	adduct thumb (nail at 90° to palm)
	abductor digiti minimi	abduct 5th finger
	opponens digiti minimi	with fingers extended, carry 5th finger in front of other fingers
	lumbricales III-IV	
LOWER LIMB		
L_{2-4}	thigh adductors (**obturator n.**)	adduct leg against resistance
L_4-S_1	gluteus medius & minimus (**superior gluteal n.**)	internal rotation at hip, hip abduction
L_5-S_2	gluteus maximus (**inferior gluteal n.**)	extension at hip (lie prone)
S_{2-4}	anal sphincter	anal sphincter tone
FEMORAL NERVE:		
L_{1-3}	iliopsoas	flex hip with knee flexed and lower leg supported (patient lies on back)
L_{2-3}	sartorius	flex knee with hip externally rotated
L_{2-4}	quadriceps femoris	extend knee against resistance
SCIATIC NERVE:		
L_4-S_2	hamstrings (biceps, semi-)	flex knee against resistance
L_{4-5}	tibialis posterior	invert plantar-flexed knee
	tibialis anterior	dorsiflex ankle
L_5-S_1	extensor digitorum & hallucis longus	dorsiflex toes against resistance
	peroneus longus & brevis	evert foot against resistance
S_1	extensor digitorum brevis	dorsiflex toes & hallux
S_{1-2}	gastrocnemius & soleus	plantarflex ankle joint
	flexor digitorum & hallucis longus	flex terminal joints of toes
	small muscles of foot	make sole of foot into cup

More than one root is generally responsible for each muscle; nevertheless, certain muscles serve as standard clinical indices for each root (so that if one particular root is out, there should be one muscle that is particularly weak):

Root	Muscle	Action
C_5	**Deltoid** Infraspinatus	Shoulder abduction Humeral external rotation (externally rotate humerus with arm held at side and flexed at elbow)
C_{5-6}	**Biceps**	Flexion of supinated forearm
C_6	Extensor carpi radialis & ulnaris	Wrist extension
C_7	Extensors digitorum, **triceps**	Finger extensions; elbow extension
C_8-T_1	**Interossei and lumbricales**, flexor digitorum profundus	Digital abduction, adduction, flexion (move fingers apart and together against resistance; flex distal phalanx of middle finger)
T_1		5th finger abduction
L_2	Iliopsoas	Thigh flexion
L_3	Quadriceps Thigh adductors	Knee extension Thigh adduction
L_{4-5}	Anterior tibial	Ankle dorsiflexion (walk on heels)
L_5	Extensor hallucis longus	Large toe extension
S_1	Gastrocnemius	Ankle plantar flexion (walk on tiptoes)
S_{2-4}	Anal sphincter	Anal sphincter tone

Reflex	Roots	
Ankle jerk	S1	"going from ankle to triceps, roots are numbered consecutively from 1 to 8".
Knee jerk	L2-4	
Biceps	C5-6	
Triceps	C7-8	

Localization in T1-12 area is best accomplished with sensory examination!

NORMAL REFLEXES

Refleksų simetriškumas!

- ask patient to relax.
- position limbs properly and symmetrically; muscle (which tendon is tested) must be *partially stretched*!
- REFLEX (PERCUSSION) HAMMER:
  pointed end – for striking small areas (e.g. finger as it overlies biceps tendon).
  flat end – less discomfort for patient (esp. over brachioradialis).
- two most commonly used types of hammers:
  1) **"Queen Square" hammer** (developed at National Hospital for Nervous Diseases at Queen Square in London)
  2) **tomahawk-shaped hammer** (used most often by American neurologists).
- judesys eina iš riešo, plaktukas keliauja lanku.
- strike tendon briskly.
  N.B. *reflex response partly depends on stimulus force* – so use no more force than you need to provoke definite response.

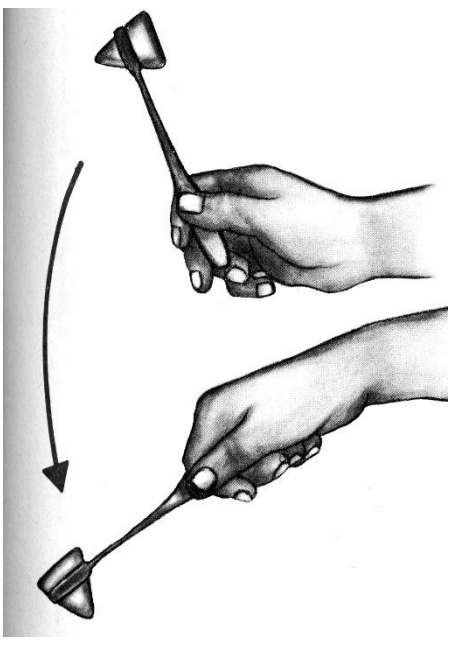

GRADE REFLEX ACTIVITY:

0+ **no response** (absent even with reinforcement)
1+ **low normal** (amplitude & velocity↓; elicited with reinforcement)
2+ **normal** (normal amplitude and velocity without reinforcement)
3+ **normal brisker than average** (amplitude and/or velocity↑ with spread to adjacent site)
4+ **very brisk** (as 3 + duplication of jerk or **clonus**) (often indicates UMN disease)

Rezultatų užrašymui galima panaudoti figūrėlę (užrašyti skaičiai – norma):

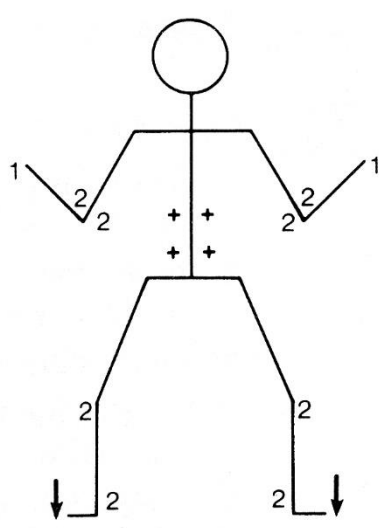

If you use ***reinforcement***, indicate it in record!

Kai refleksai abipus (!) ***SILPNI ar NEIŠGAUNAMI***, naudok REINFORCEMENT (**JENDRASSIK maneuver**) – isometric contraction of other muscles:

- tiriant kojas - ligonis suima rankas už pirštų ir traukia į priešingas puses, o gydytojas tuo metu išgauna reikiamą refleksą;
- tiriant rankas - sukanda dantis.

N.B. tell patient to do maneuver just before you strike tendon!; patient must relax between repeated attempts.

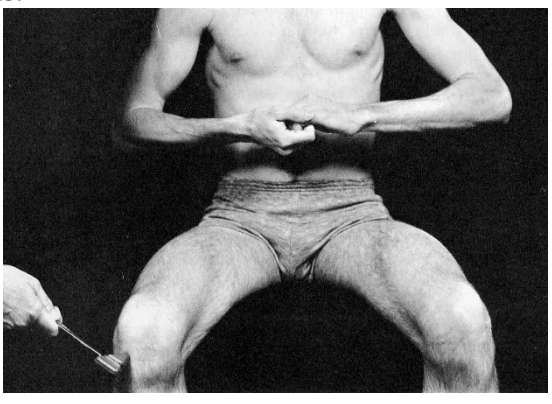

Kai refleksai ***HIPERAKTYVŪS***:

1) suduoti plaktuku ir aplinkui - **išplitę reflektorinės zonos**
2) **check for CLONUS** (rhythmic, rapid alternation of muscle contraction and relaxation caused by sudden, passive tendon stretching):
   a) ***ankle*** (ligonio koja truputį sulenkta per kelio sąnarį, gydytojas staiga atlieka pėdos dorsifleksiją ir tokioje padėtyje užfiksuoja) – rhythmic oscillations between dorsiflexion and plantar flexion; in developed cases, repetitive plantar flexion of foot can be maintained virtually indefinitely as long as upward pressure is maintained on foot.

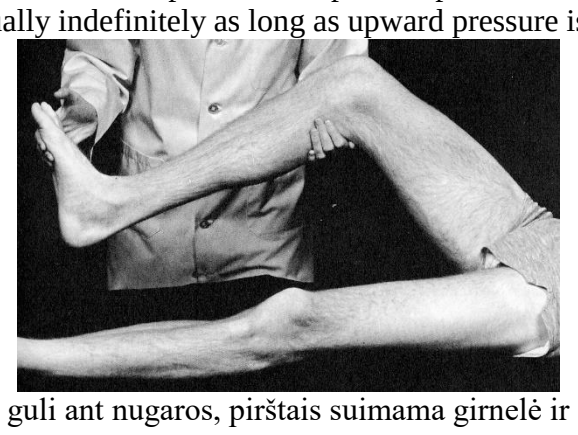

   b) ***patellar*** (ligonis guli ant nugaros, pirštais suimama girnelė ir staiga patraukiama žemyn, ranka neatitraukiama).
   c) ***plaštakos*** (staiga atlenkiama ligonio plaštaka).

N.B. only ***sustained clonus*** suggests UMN damage!

- generally speaking, however, clonus cannot be obtained at any site in normal individual (occasionally, 1-2 beats of clonus can be obtained at ankle in normal individuals with naturally brisk reflexes).
- severity of clonus parallels severity of spasticity & hyperreflexia.

A. MUSCLE STRETCH (DEEP TENDON) REFLEXES

1. Biceps **n. musculocutaneus C_{5-6}** – pacientas guli arba sėdi, alkūnė 120° kampu, delnas žemyn; gydytojas tvirtai uždeda nykštį ant bicepso sausgyslės ir per jį suduoda plaktuku (→ sulinksta alkūnė):

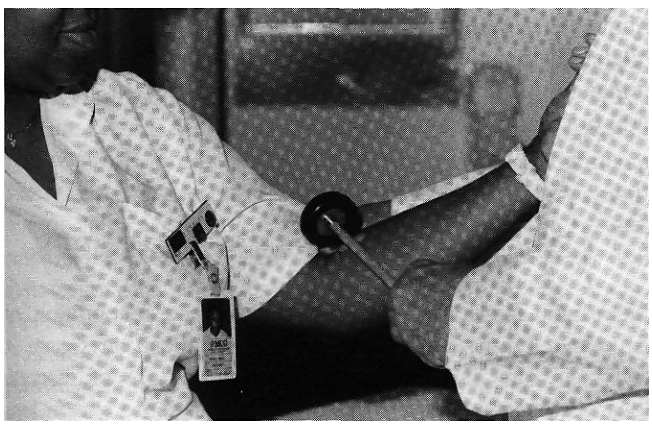

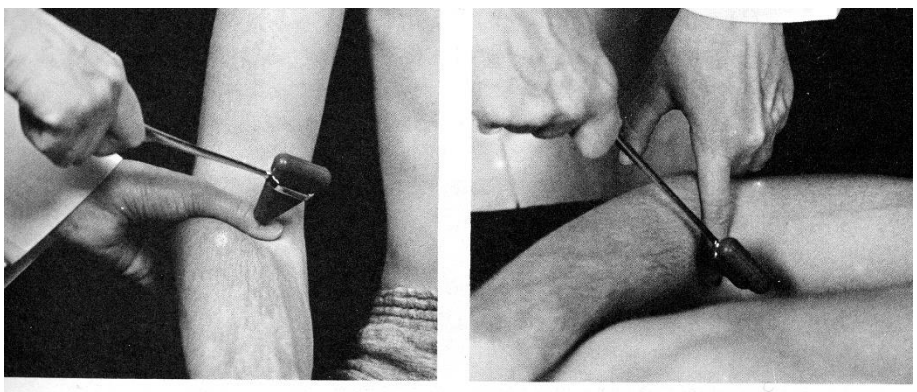

PATIENT SITTING PATIENT LYING DOWN

Arm (DTRs, sensory).avi >>

2. Triceps **n. radialis** C_{7-8} - pacientas guli arba sėdi, alkūnė 90° kampu, dilbis skersai krūtinės, delnas žiūri žemyn; laikant ligoniui už riešo plaktuku aukščiau alkūnės suduodama per tricepso sausgyslę (→ alkūnė išsitiesia);
   - jei pacientas negali atsipalaiduoti, taikomas kitas metodas – žastas abdukuojamas 90° ir liepiama kad dilbis laisvai kabotų (if it were "hung up to dry").

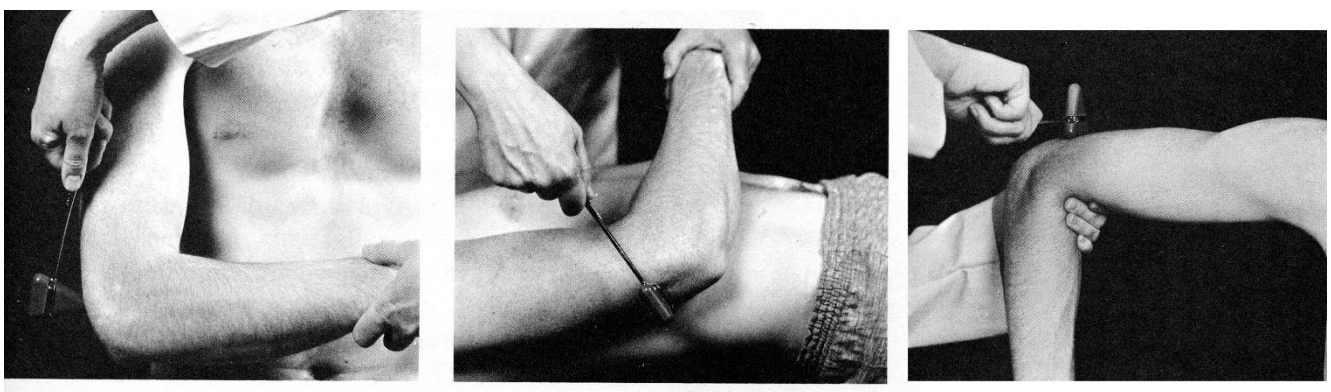

PATIENT SITTING PATIENT LYING DOWN

3. Patellar (knee) **n. femoralis** L_{2-4} - ligonis guli, gydytojas ranka laiko už pakinklių nedaug sulenktus kelius, suduodama per kvadricepso sausgyslę žemiau girnelės (→ susitraukia m. quadriceps femoris).
   - jei pacientas negali atsipalaiduoti, taikomas kitas metodas – laikomas tik tiriamos pusės pakinklis, o ranka remiasi į kitą koją (bet taip sunkiau palyginti abi puses).

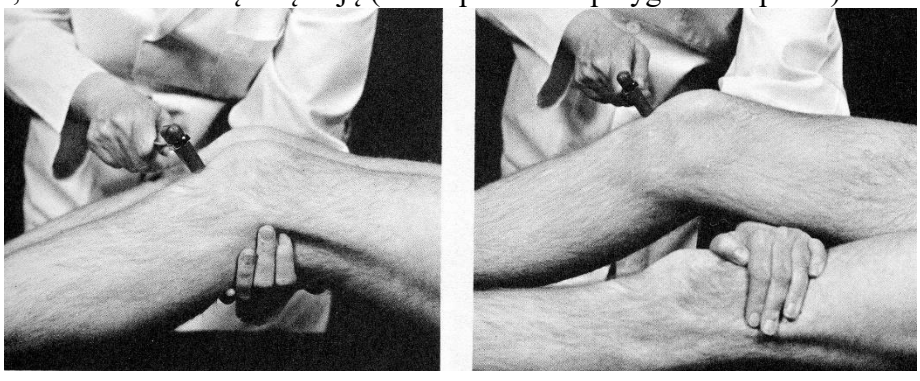

4. Achilles (ankle) **n. tibialis** S_{1-2} - prilaikant už pėdos distalinio galo, suduodama per Achilo sausgyslę (→ pėda susilenkia).

   Stebėk sulėtėjusią relaksaciją (e.g. hypothyroidism) – ji geriausiai išryškėja šio reflekso metu!

   a) ligonis guli ant nugaros tiriamąją pėdą pasukęs į šoną ir uždėjęs ant kitos kojos:

   b) ligonis klūpo ant kėdės krašto.

   c) ligonis sėdi nuleidęs kojas:

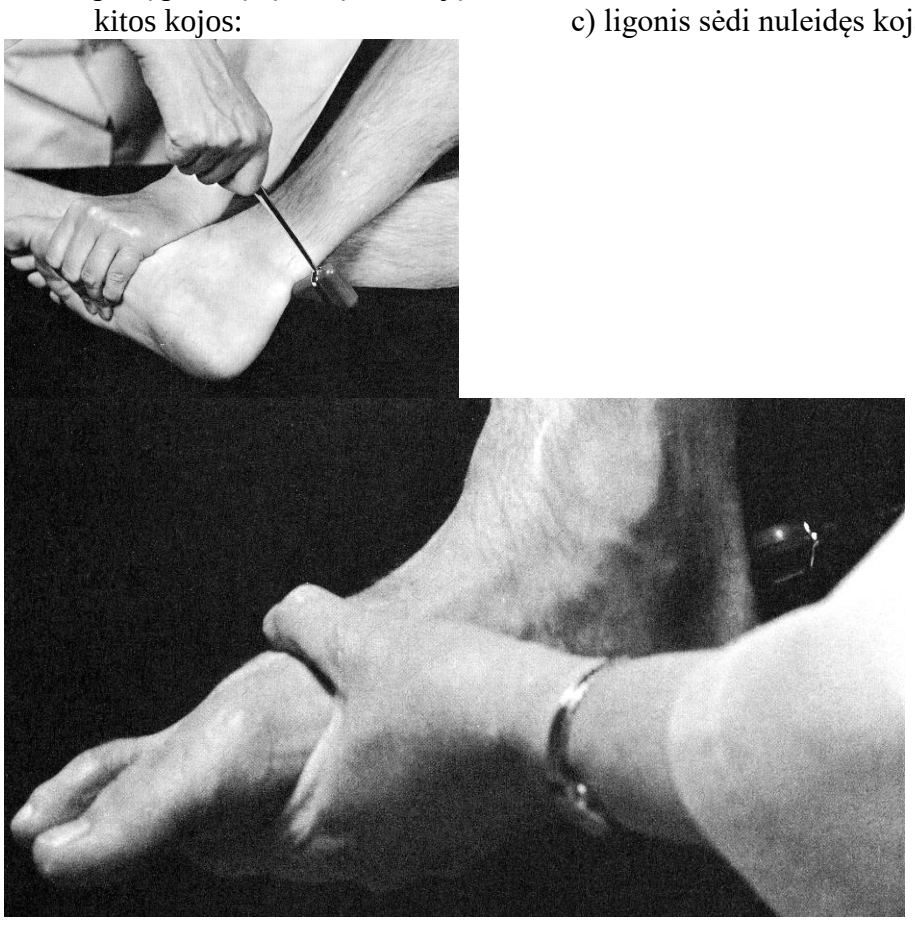

Reflex	Roots	
Ankle jerk	S1	"going from ankle to triceps, roots are numbered consecutively from 1 to 8".
Knee jerk	L2-4	
Biceps	C5-6	
Triceps	C7-8	

5. Jaw jerk **n. trigeminus** (→ žandikaulis pakyla). *see CN5 testing >>*

6. Facial jerk **n. facialis** - examiner stretches skin of patient's nasolabial fold with index and middle finger of one hand and then taps these fingers with reflex hammer (→ reflex contraction in underlying facial muscles).

B. PERIOSTEAL REFLEXES

1. Brachioradialis (s. Supinator) **n. radialis (common)** C_{6-7} - alkūnė truputį sulenkta, delnu žemyn, suduodama per m. brachioradialis sausgyslę ties stipinkaulio yline atauga (→ forearm flexion and supination):

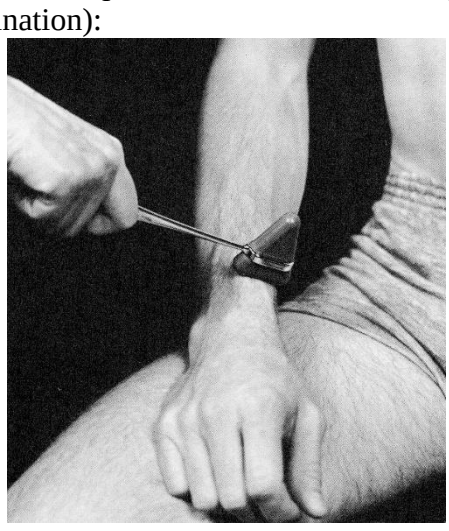

2. Viršantakinis **n. trigeminus** (aferentacija), **n. facialis** (eferentacija) - suduodama į antakio medialinį kraštą (→ akis užsimerkia).
3. Peties-mentės C_{5-6} - ligonis stovi nuleidęs rankas, plaktuku suduodama per vidinį mentės kraštą (→ ranka atsitraukia į šoną ir pasisuka į vidų).

C. JOINT REFLEXES

1. Leri C_{5-6} - suimami I-IV pirštai ir staiga sulenkiami per pamatinius sąnarius, o plaštaka per riešą (→ sulinksta alkūnė).
2. Majerio C_6-Th_1 - III pirštas per pamatinį sąnarį prilenkiamas prie delno (→ nykštys linksta priešingai kitiems pirštams).

D. CUTANEOUS REFLEXES

Must travel through cerebral cortex!

Are noted as present or absent (not graded!).

1. Abdominal upper **Th_{8-10} nn. intercostales**, abdominal lower **Th_{10-12} n. iliohypogastricus, nn. intercostales** - braukiama pagal nervų eigą iš šono vidurinės linijos link, aukščiau ir žemiau bambos (→ susitraukia pilvo raumens segmentas, bamba patempiama link stimulo):
   - may be absent in both UMN and LMN diseases.
   - *multiparity or obesity may mask this reflex* – use your finger to retract umbilicus away from side to be stimulated (feel with your retracting finger for muscular contraction).

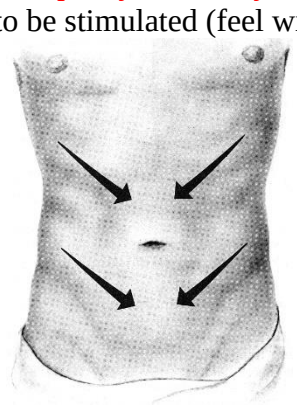

2. Plantar L_5-S_1 - pabraukti pado lateraliniu kraštu nuo kulno aukštyn ir užsukti medialyn (→ pirštai susilenkia).

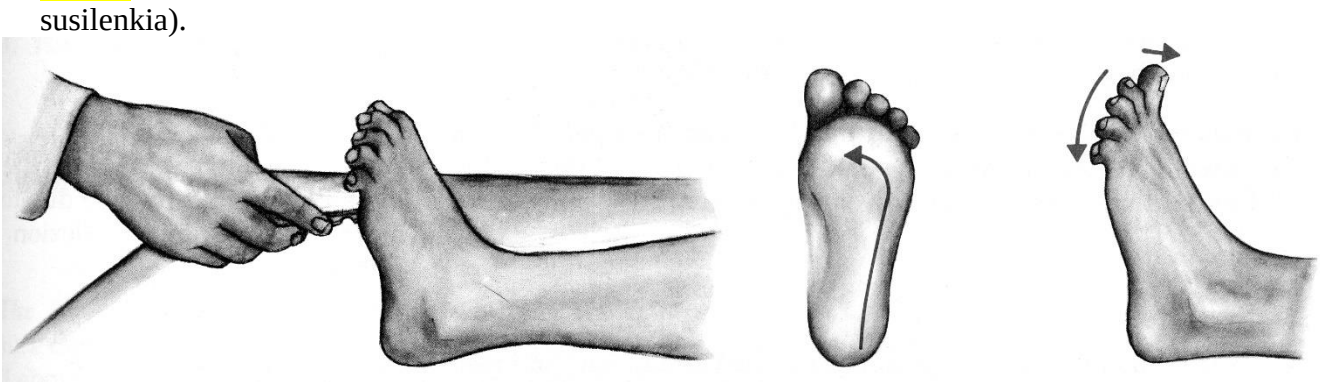

   - jei įvyksta nykščio dorsifleksija ir kitų pirštų išsiskleidimas vėduokle – **BABINSKI response** (UMN disease). *see below >>*
   - some patients withdraw from this stimulus by flexing hip and knee; hold ankle (if necessary) to complete testing (it may be difficult to distinguish withdrawal from Babinski – ***withdrawal is quick; Babinski is slow***!).

3. Cremaster **n. genitofemoralis** L_1 (aferentacija) L_2 (eferentacija) - brūkštelėti vidiniu šlaunies paviršiumi iš viršaus žemyn (→ susitraukia m. cremaster - pakyla sėklidė).
4. Anal wink **n. rectalis inf.** S_{2-4} - bakstelėti į išangės odą (→ susitraukia sfinkteris); taip pat patikrinti sfinkterio tonusą.
5. Bulbocavernosus - squeeze glans penis / clitoris or gently tug urinary catheter (→ pelvic floor musculature contraction felt by finger placed in rectum).

PATHOLOGICAL REFLEXES

A. PYRAMIDAL

- norma ***vaikams iki 2 metų amžiaus***, o iki 6 mėn jie pasireiškia spontaniškai) - nespecifiniai, t.y. nurodo ***pažeidimą bet kurioje kortikospinalinio trakto vietoje***.

1. **FINGER FLEXOR JERKS** (C_7-Th_1):
   1) Starling - gydytojas kairiąja ranka laiko ligonio plaštaką, pasuktą delnu žemyn, o dešiniosios rankos pirštų galais staiga suduoda per ligonio pirštus iš delninės pusės (→ pirštai linksta žemyn). analogas kojose – Rossolimo reflex
   2) Trömner - *modified Starling reflex* - examiner lays fingers of patient's hand on his own and taps his own fingers - sudden stretch on all of patient's fingers (→ reflex flexion of fingers that can be felt by examiner and also observed in thumb as in Hoffman reflex):

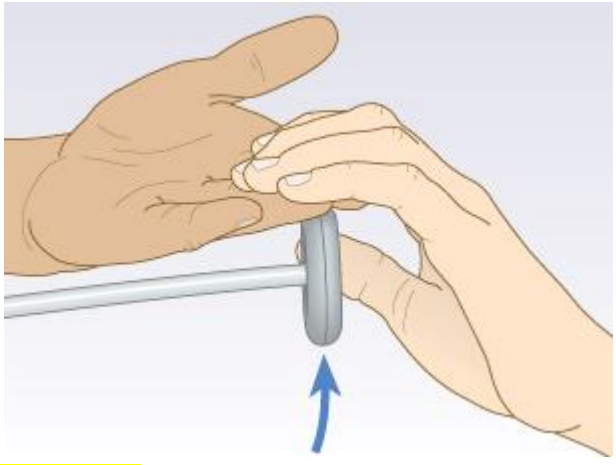

3) Bechterew-Mendel - plaktuku suduoti per plaštakos *nugarinio* paviršiaus lateralinį kraštą (→ pirštai sulinksta).
4) Žukovskio-Kornilovo - plaktuku suduoti per plaštakos *delninio* paviršiaus lateralinį kraštą (→ pirštai sulinksta).
5) Klippel-Vailio - suimti II-V pirštus ir staiga per riešą atlenkti plaštaką (→ nykštys palinksta po plaštaka).
6) Hoffmann (→ reflex flexion of fingers, esp. thumb); found in many normal individuals, but it implies decreased inhibition (esp. if asymmetric!)
   a) middle finger is held between examiner's second and third fingers and distal phalanx is flicked downward by examiner's thumb.
   b) "clicking" fingernail of middle finger with examiner's thumbnail:
   c) gydytojas laiko ligonio III pirštą už vidurinio pirštakaulio, o kitos rankos dviem pirštais spausdamas galinį pirštakaulį, greit nuo jo nuslysta.
   d) place your right index finger under distal interphalangeal joint of patient's middle finger; using your right thumb flick patient's finger downwards:

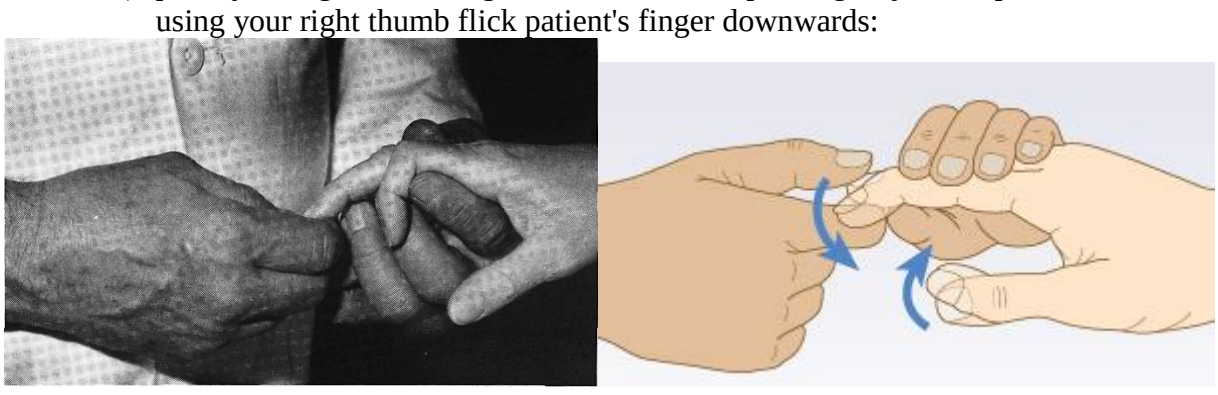

Hoffmann sign:

Grijalva RA "Hoffmann sign: clinical correlation of neurological imaging findings in the cervical spine and brain." Spine (Phila Pa 1976). 2015 Apr

for **cervical cord compression** - 59% sensitivity, 49% specificity, 35% positive predictive value, and 72% negative predictive value.
for **brain pathology** - 71% sensitivity, 33% specificity, 10% positive predictive value, and 95% negative predictive value.

- sensitivity of Hoffman's sign may be increased by examining the patient during multiple full flexion and extension maneuvers of the neck, to a degree that they can comfortably tolerate (dynamic Hoffman's sign).

2. **KOJOS LENKIAMIEJI** (S_{1-2}):

1) Rossolimo - pirštų galais suduoti per ligonio kojos pirštų galus iš apačios (→ pirštai susilenkia).
   analogas rankose – Starling reflex
2) Bechterew-Mendel - plaktuku suduoti per *pėdos* lateralinį kraštą iš viršaus (→ pirštai sulinksta).
3) Žukovskio-Kornilovo - plaktuku suduoti per *pado* lateralinį kraštą (→ pirštai sulinksta).
4) Puusepp - pabraukti adatėle nuo kulno lateraliniu pėdos kraštu (→ V pirštas atsitraukia į šoną).

3. **KOJOS TIESIAMIEJI** (→ nykštys išsitiesia, kiti pirštai išsiskečia vėduokle):

N.B. pathologic reflex response is slower than voluntary withdrawal!

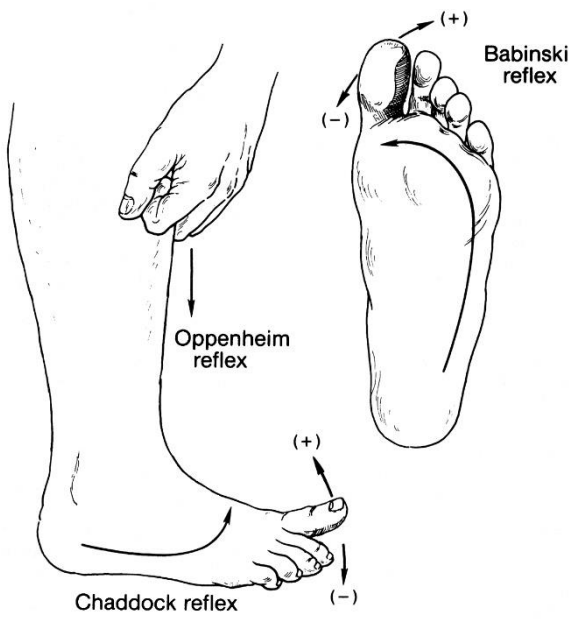

1) Babinski S_1 (aferentacija), L_5-S_2 (eferentacija) – pabraukti lateraliniu pado kraštu nuo kulno aukštyn ir po to užsukti medialyn.
   N.B. lateral sole aspect must be stroked, because medial stimulus may inadvertently induce primitive grasp reflex!
   N.B. Babinski is normal reflex at age ≤ 2 yrs.

Sekantys refleksai (**Babinski's Equivalents**) tikrinami tik, jei [a)]Babinskis neaiškus or [b)]patient is very ticklish (difficult to differentiate spontaneous withdrawal from reflex responses):

2) Oppenheim – running your knuckles down shin (from infrapatellar region toward ankle).
3) Chaddock – irritation of external malleolar skin area (rubbing lateral surface of foot with edge of tongue blade or key from heel to little toe).
4) Schäffer – pinching Achilles tendon (pirštais suspausti Achilo sausgyslės odą).
5) Gordon – pinching calf (pirštais iš šonų suspausti blauzdos raumenis).
6) Bing – pricking dorsum of foot or great toe with pin.
7) Strunsky – pulling little toe laterally away from great toe.
8) Throckmorton – tapping foot dorsum.
9) Williams' – gently squeezing metacarpal bones.

- in setting of forefoot amputation, look for tensor fascia lata contraction when stimulating sole (Brissaud reflex).

3. **AXIAL**

Pectoral (cord compression in the upper cervical spine C2–C4) - elicited by tapping the pectoralis tendon in the deltopectoral groove → adduction and internal rotation of the shoulder.

4. **APSIGYNIMO** (pasireiškia žemiau pažeidimo): badant adata, gnaibant tiriama pėda, po to kylama aukštyn (→ koja išsitiesia arba susilenkia, pėda išsitiesia).

   Marie-Foix-Bechterew - staigiai sulenkti kojų pirštus (→ visos kojos susitraukimas - spinalinis automatizmas).

B. FRONTAL RELEASE signs, s. PRIMITIVE reflexes

- norma ankstyvoje kūdikystėje!
- ETIOLOGY – cortical disinhibition due to lesions of ***frontal lobes*** (esp. ***premotor cortex***) - in dementia, pseudobulbar palsy.

ORAL AUTOMATISMS

1) Sucking - plaktuku suduoti per lūpas arba mentele staigiai ir švelniai pabraukti per lūpas (→ atsiranda čiulpimo judesiai).
2) Snout (straublio) - plaktuku švelniai suduoti per lūpas arba nosies šaknį arba mentele staigiai ir švelniai pabraukti per lūpas (→ lūpos susitraukia ir atsikiša į priekį); facial jerks are usually increased in this situation, and it may not be possible to differentiate between two.
3) "Visual suck" (distancinis oralinis) - artinti plaktuką prie lūpų (→ lūpos atsikiša į priekį).
4) Rooting – stroke with your index finger perioral skin:
   at mouth corners → mouth will open and turn to stimulated side;
   at midline of upper lip → head will retroflex;
   at midline of lower lip → jaw will drop.
5) Buldogo - prisiliesti prie lūpų (→ stipriai sukanda dantis).
6) Palmomental reflex (Marinesku-Radovičiaus) - plaktuko kotu padirginti m. thenar sritį (→ ipsilateraliai susitraukia m. mentalis ir sujuda smakras); etiology - *dementia* (may also be seen in *normal elderly individuals*!).

GRASPING

1) (Tonic) Grasp reflex:
   a) Janiševskio-Bechterevo – divert patient's attention (kalbantis su ligoniu) → plaktuko kotu lengvai pabraukti delnu nuo pirštų link riešo arba suspausti delną tarp I ir II pirštų; if reflex is present, examiner's fingers will be grasped with increasing force; harder examiner tries to extricate his fingers, harder patient grips (patients may literally be lifted off bed and fingers pried open only with great difficulty after examiner has put arm back in resting position).
   b) Denny-Brown – bilateral shaking hands maneuver with both hands held crossed; examiner's hands are gently pulled away providing large tactile stimulus to patient's palms; positive response is gripping of examiner's hands that is persistent and reproducible.

   – may also be unilateral or asymmetrical (reflects unilateral or asymmetrical frontal lobe disease).
2) Magneto - artinant prie delno plaktuką, ligonis iš tolo siekia jo.

OTHER frontal release signs

Glabellar reflex – tapping glabella with finger:
norma: few blinks, then cessation;
frontal damage: continued blinking with repeated tapping.

Environmental dependence – inability to suppress environmental distractions:
1) ***imitation behavior*** - tendency to mimic examiner.
2) ***utilization behavior*** - tendency to inappropriately take up and use instruments around patient.

Paratonia → see p. Mov3 >>

C. NECK TONIC AND LABYRINTH

1) Magnuso-Kleino - pasyviai pasukus ligonio galvą į priešingą hemiplegijai pusę, toje pusėje padidėja *tiesiamųjų* raumenų (ranka išsitiesia), o paralyžuotoje pusėje - *lenkiamųjų* raumenų tonusas (ranka susilenkia).
2) Lėlės - pasyviai lankstant galvą, akys kaip lėlės. see p. S30 >>
3) Šilderio - ligonis stovi užsimerkęs ištiestomis į priekį rankomis. Kai jis staiga pasuka galvą į smegenėlių pažeidimo pusę, į tą pačią pusę nukrypsta abi rankos, o tos pusės ranka dar ir pakyla.
4) Nugręžiamųjų raumenų - ligonis stovi užsimerkęs ištiestomis į priekį delnais aukštyn rankomis. Smegenėlių pažeidimo arba parezės pusėje ranka iš lėto pasisuka delnu žemyn.
5) Labirintiniai - dėl piramidinių laidų pažeidimo vaikštant raumenų tonusas padidėja, o atsigulus sumažėja.
6) Posturaliniai (pažeista corpus striatum):
   pėdos - gulinčiam ant nugaros ligoniui pasyviai lenkiama pėda į viršų (toniškai susitraukia m. tibialis ant. ir pėda toje padėtyje užsifiksuoja);
   blauzdos - gulinčiam ant pilvo ligoniui koja sulenkiama per kelią ir blauzda prispaudžiama prie šlaunies (blauzda toje padėtyje užsifiksuoja).

DIFFERENTIATION OF MOTOR DYSFUNCTIONS

	Appearance	Muscle tone	Voluntary movements (strength)	Coordination	Reflexes		
					Muscle stretch	Plantar	Abdominal
Sensory neuron	normal	↓	normal	normal (eyes open); poor (eyes closed)	0		
Lower motoneuron	atrophy, fasciculations	↓↓↓	0	paralyzed	0		
Upper motoneuron	mild atrophy, Vernike-Mano poza, synkinesia	↑↑↑ "clasp knife"	0	paralyzed	↑ clonus	Babinski	0
Extrapyramidal	tremor at rest	↑ "lead-pipe" / "cogwheel"	normal/↓	slowed	normal		
Cerebellar	intention tremor	↓	normal/↓	poor	swinging	normal	normal

Lesion / Disorder	Feature of coordinated movements
cerebellar	rapid but sloppy or dysmetric
parkinsonism	slow and hypometric
corticospinal tract	slow and clumsy
apraxia	fail to alternate
parietal, subcortical, frontal	motor persistence

DETECTION OF MOTOR MALINGERING

- *reflexes (tendon, superficial) are only truly objective attributes of neurological examination*, since patient cannot voluntarily alter them in most cases (patient's relaxation can sometimes influence state of tendon reflexes).
- sophisticated patient may be able to fake *Babinski sign*, but experienced observer can usually detect fakery.
- ***LA BELLE INDIFFERENCE*** – emotionally indifferent attitude toward severe deficit.
- estimation of MUSCLE STRENGTH depends on patient's cooperation - patient can voluntarily change level of effort, thus producing impression of weakness; most common patterns:
  1) ***sudden collapse*** of limb after initial, often normal effort.
  2) some start to ***tremor*** rather than applying constant pressure as patient tries to simulate less than complete motor function ("misdirection of effort" is one way to describe this behavior).
  3) some simply ***refuse to participate in test***.
  4) when ***abducted arm*** is pushed downward, patient ***bends his trunk*** to that side, giving impression that his arm is being pushed downward when in fact relationship with trunk remains same.

Methods to detect malingered or conversion (hysteric) weakness:

All are really tests of **cooperation** and not true **weakness**! (i.e. they may detect lack of cooperation, but do not fully exclude real weakness – paralyzed patient may not be willing to be tested!)

1) test muscle strength rapidly and simultaneously in arms starting at shoulders and proceeding distally ***as rapidly as possible*** so patient does not have time to think about what his response should be (as result, good side may collapse in unison with bad side after initial symmetrical effort - most easily demonstrated when testing abduction of fingers).
2) if supposedly weak ***limb is dropped***, it may fall at less than speed dictated by gravity, may fall with greater force than expected, or may briefly hover in air before patient realizes that limb should be set down.
3) with patient lying supine, ***place one hand between heel and examining table while testing ability of patient to raise other leg off table***:
   - with full effort heel on table is forced downward to support raising of opposite leg.
   - when full effort is used to raise good leg, one can feel normal downward pressure of "weak" leg.
   - when "weak" leg is supposed to be raised, one may feel very little if any pressure under normal leg, indicating that patient is not trying to raise "weak" leg (in fact, pressure under heel of good leg may decrease - **HOOVER sign**).
4) paralyzed arm that is held limply at side will flail back and forth when ***patient's shoulders are shaken back and forth***; if, instead, "paralyzed" arm is observed to remain tightly held against body, it has normal strength and tone.
5) observe ease with which patient is able to ***roll over and move in bed***.
6) if patient can ***walk***, he exhibits behavior that indicates that he is markedly exaggerating effort to take step and in process displays extraordinary strength and coordination;
   - "weak" limb is dragged along ground and not circumducted as in typical UMN disease.
   - **falling** is common problem and often occurs only in direction of examiner or stretcher where assistants can prevent fall (even two people may have difficulty in supporting patient because patient's efforts are directed toward trying to fall and not toward trying to assist in staying upright).

Key to examination is skilled observation of stereotyped acts! (e.g. casual observation using supposedly paralyzed arm for balance)

COORDINATION TESTS

PSYCHOGENIC / FEIGNED dyscoordination & gait disorders → see p. Mov7 >>

Individual's orientation in space depends on four inputs:

1) visual
2) vestibular
3) proprioceptive
4) cutaneous exteroceptors (touch and pressure)

1. Limb ataxia (atliekama - atsimerkus, užsimerkus*):

*atsimerkus ***rega kompensuoja*** *propriocepcinius* deficitus; *smegenėlių* pažeidimo simptomams ***rega įtakos neturi***!

1) **finger-nose**:
   - patient's outstretched arm in horizontal position;
   - ask to touch your index finger and then his nose alternately several times (move your finger about so that patient has to alter directions and extend his arm fully to reach it - **finger-chase test**);

     "Can you please touch your finger to my finger and then to your nose"

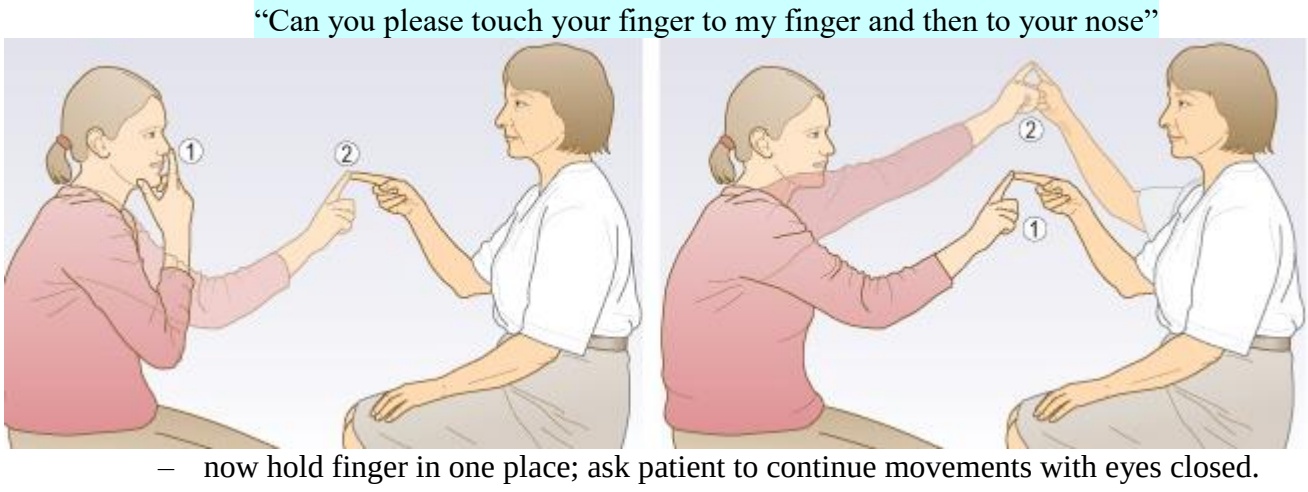

   - now hold finger in one place; ask patient to continue movements with eyes closed.
2) **pro šalį pataikymo simptomas (point-to-point)**
3) **past-pointing** – test of ***vestibular & cerebellar*** integrity: patient, seated in *revolving chair*, is rotated* to right 10 times with eyes closed; then with arm held horizontal, right index finger is brought in touch with tip of examiner's finger; patient is asked to bring arm vertically downward and up again (or vertically upward and down again) to reach examiner's finger;
   a) *normal vestibular apparatus* - finger will be brought down several inches to right of examiner's finger (reverse is true on rotation to left).
   b) some *vestibular disorders* - past-pointing occurs without rotation.
   c) *cerebellar disease* - finger will overshoot point.

   *test may also be used in connection with *caloric stimulation*.
4) **heel-to-shin** – patient is supine; head is tilted so that visual control is possible;
   - ask to place heel (not arch!) on opposite knee: run down shin to big toe, then back;
   - kinetic tremor is specifically observed when patient holds heel on knee for few seconds before sliding down anterior tibial surface.

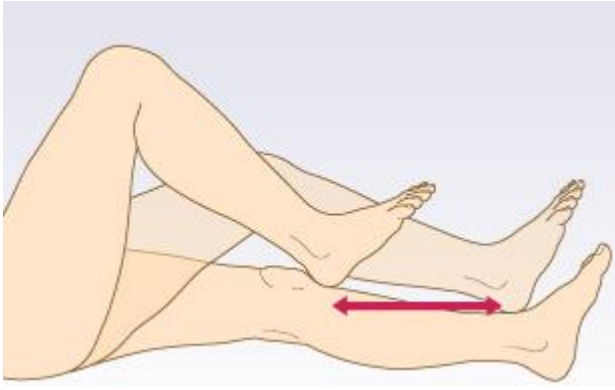

5) **vaikščioti viena linija (heel-to-toe)**

Paresis gali imituoti smegenėlių ataksiją ir intencinį tremorą (e.g. weakness can produce wavering when patient puts finger to nose) - H: examine coordination in finger and hand movements:

a) repetitive tapping of forefinger against flexor crease of thumb.
b) rapid alternating movements of hands.

Pyramidal and ***extrapyramidal*** lesions slow rate of movement, but accuracy is unaffected, whereas in ***cerebellar*** disease, rate may be normal, but accuracy is impaired and rhythm is erratic.

2. Postural ataxia:

a) *stovint* **loštis atgal** (suglaustomis kojomis ir nuleistomis rankomis) → nesilenkia keliai ir griūva atbulas;
b) *gulint* **atsisėsti** (sukryžiuotomis rankomis) → kyla kojos ir negali atsisėsti.
c) stand behind patient and give **brisk pull on shoulders** (pull test); patients should be warned and instructed to resist this postural threat (in several movement disorders, patients will take several steps backward or even fall).

3. Dysdiadochokinesia (in cerebellar disease movements are slow, jerky, awkward, with rhythm breaks when direction of movement must change):

a) užsimerkus ir ištiesus rankas į priekį greitai **pronuoti ir supinuoti dilbius**.
b) su nykščio galu greitai **paliesti kitų tos rankos pirštų galus**.
c) **plekšnoti su ranka** sau per koją kiek galima greičiau.

4. Dysmetria:

1) **STEWART-HOLMES sign (s. rebound phenomenon)** - inability to check movement when passive resistance is suddenly released:
   a) ligonis laiko ties krūtine sulenktą per alkūnę ir suspaustą į kumštį ranką; gydytojas, stovi priešais, patraukia ranką į save ir paleidžia (ligonis trinkteli sau į krūtinę).
   b) ask patient to stretch arms out in front and maintain this position; push patient's wrist quickly downward and observe returning movement.
2) **signe de la prehension** (ask to move hand to object, coincidently shaping hand in anticipation of object, and finally closing of fingers to formulate grasp) - cerebellar subjects open their fingers excessively wide in anticipation of object and close their fingers with undue force grasping object.
3) deda stiklinę su trenksmu
4) nesujungia dviejų taškų linija

Lesion in cerebellar HEMISPHERE → dyscoordination of ***ipsilateral extremities***;
Lesion in cerebellar VERMIS → dyscoordination of ***trunk***.

N.B. smegenėlių neįmanoma testuoti *nesąmoningam* ar *paralyžuotam* pacientui!

5. **ROMBERG test** - rankos ištiestos į priekį, delnais į viršų*, ligonį prilaikyti iš užpakalio:

1) pėdos greta
2) pėdos vienoje linijoje (tandem) - **tandem (s. sharpened) ROMBERG test** - required to reveal abnormalities in younger patients.
3) ant vienos kojos

*in *MILD HEMIPARESIS* or *IPSILATERAL CEREBELLAR LESION*, pakenktoje pusėje ranka pradeda lėtai pronuoti (**PRONATOR DRIFT**), nusvyra žemyn, linksta pirštai ir alkūnė:
*in *PROPRIORECEPTION LOSS* - upward drift (overcompensation), often with hand rotating internally.
*in *VESTIBULAR DISORDERS*, abi rankos nukrypsta į vieną pusę; can be accentuated by asking patient move extended arms up and down.

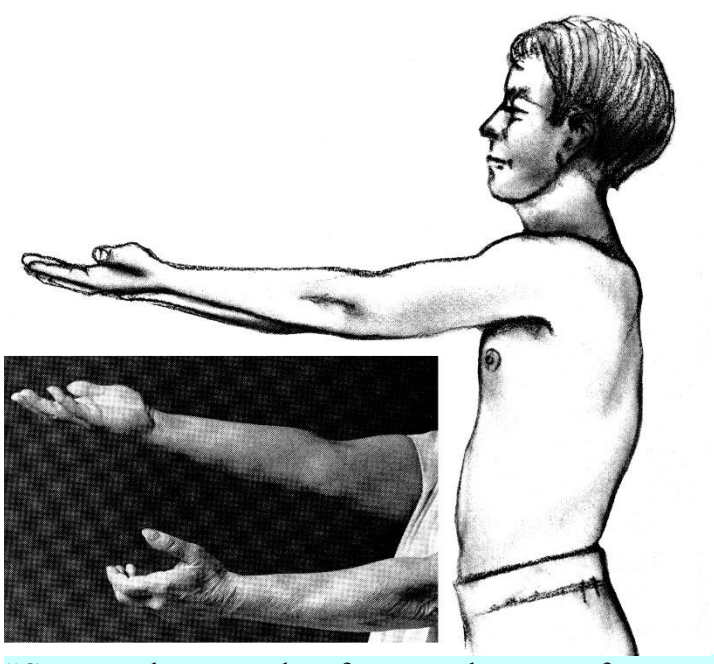

"Can you please stand up for me and get your feet together. Can you please close your eyes, don't worry I will assist you if you fall"

Positive Romberg sign - jei griūna tik užsimerkęs (sutrikusi propriorecepcinė impulsacija – ***fasciculi gracilis et cuneatus***);
smegenėlių ataksija - griūna nepriklausomai nuo regėjimo.

N.B. most useful test to quantify balance is **eyes-closed tandem Romberg test** – išjungiama tiek rega, tiek proprioreceptcija – lieka "pasikliauti" tik vestibuliniu aparatu;
- no patient with ***bilateral vestibular loss*** can stand for 6 seconds.
- patients with ***chronic unilateral vestibular loss*** show very little ataxia - can perform eyes-closed tandem Romberg test.

Lesion site	Romberg test		
	eyes-open	eyes-closed	eyes-closed tandem
fasc. gracilis et cuneatus			
smegenėlių			
vestibular			

Vestibular disorders lead to ***directional*** instability toward side of affected vestibular organ (vs. **other neurologic disorders** – lead to ***nondirectional*** instability / ataxia).

CRANIAL NERVE EXAMINATION

Abnormality of one cranial nerve requires meticulous scrutiny of adjacent nerves!

CN1 (NN. OLFACTORII)

- is each nasal passage open? – compress one nose side and ask patient to sniff through other.
- ar nesutrikusi uoslė? (gal serga sloga, vartoja kokainą?).
- **BERNSTEIN kvapų rinkinys** - tiriama užsimerkus, kiekvieną pusę atskirai.
  - uoslės tyrimui netinka medžiagos, kurios stimuliuoja *n. trigeminus* nociceptorius (e.g. alcohol, ammonia) ar *skonio receptorius*.
    N.B. šios medžiagos tinka nustatyti simuliuojančius uoslės netekimą!
  - tinkami kvapai: tobacco, vanilla, coffee, chocolate, soap, orange peel.
- **unilateral testing** - seal contralateral naris using piece of Microfoam tape cut to fit its borders; patient is instructed to sniff stimulus normally and to exhale through mouth.

Most widely used test is University of Pennsylvania Smell Identification Test (UPSIT).
- can be self-administered in 10-15 minutes in waiting room.
- four booklets containing 10 odorants apiece; stimuli are embedded in 10-50 µm diameter microencapsulated crystals located on "scratch and sniff" strips near bottom of each page.
- above each strip is multiple choice question with four response alternatives.
- patient is required to choose answer, even if none seems appropriate or no odor is perceived (i.e. test is *forced-choice*) - this helps to encourage patient to carefully sample each stimulus and provides means of detecting malingering (since chance performance is 10 out of 40, very low scores reflect avoidance, and hence recognition, of correct answer).
- six categories: ***normosmia, mild microsmia, moderate microsmia, severe microsmia, anosmia, probable malingering***.
- *test reliability is high* (test-retest Pearson *r*s > 0.90).

CN2, 3, 4, 6 (N. OPTICUS, N. OCULOMOTORIUS, N. TROCHLEARIS, N. ABDUCENS)

→ see p. D1eye >>

CN5 (N. TRIGEMINUS)

SENSORIKA

Jutimai (skriningui su adatėle ar vata*; jei reikia – vata (adatėlė) ir temperatūra):

*pacientas užsimerkęs ir parodo su pirštu, kurioje vietoje buvo paliestas veidas

1) *šakų inervacijos srityse*:
[riba su C_2 – linea intertragica, einanti per vertex; angulus mandibulae - jau C_{2-3}]
If face sensation is lost, **angle of jaw** should be examined - this area (innervated by C_2, should be spared when problem is isolated trigeminal deficit)!

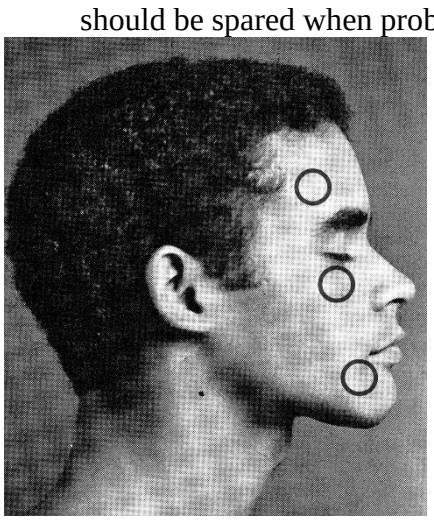

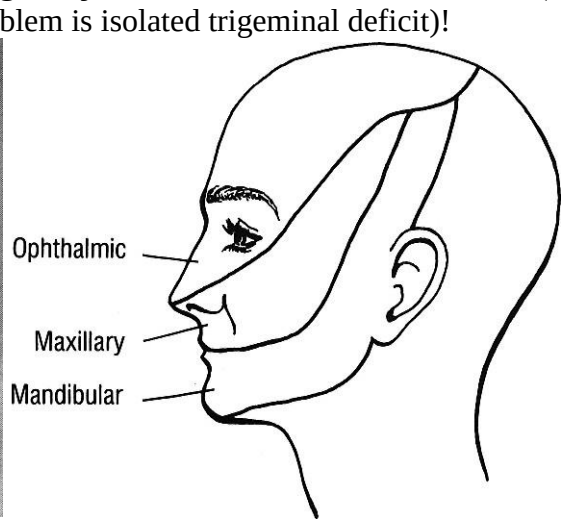

2) *Zelderio zonose* (tik skausmo ir t-ros jutimas - nucl. tractus spinalis CN5):

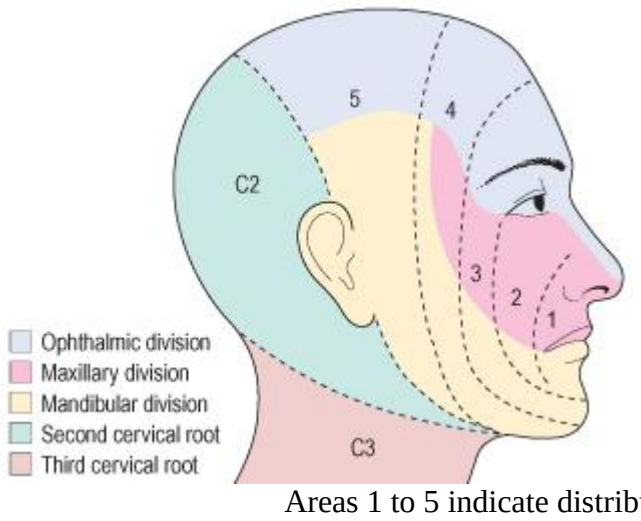

Areas 1 to 5 indicate distribution of pain fibres in nucl. tractus spinalis CN5 (1 = pons; 5 = upper cervical cord).

3) touch sensation on *anterior 2/3 of tongue*.

4) *afferent parts of reflexes*:

N. ophthalmicus – ***corneal blink reflex*** ($CN5_1$ → CN7): patient looks up and away from you; gently depress the lower eyelid; approach from other side, avoiding eyelashes, touch lightly lateral edge of cornea (not conjunctiva!) with fine wisp of damp cotton (gal neužsimerkia dėl CN7 paralyžiaus ar dažnai dėvimų kontaktinių linzių?).

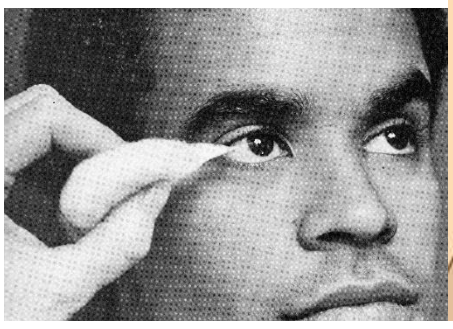
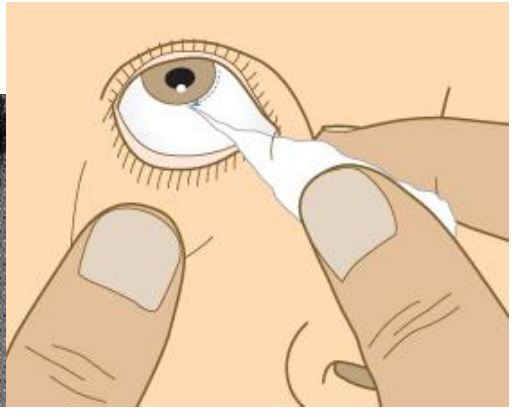

N. maxillaris – ***sneeze reflex*** (CN5$_2$ → reticular formation).

N. mandibularis – ***jaw-jerk reflex*** (CN5$_3$ sensory → CN5$_3$ motor):

a) apatinis žandikaulis laisvai nukaręs, uždėjus mentelę ant dantų ir už galo laikant, per ją suduodama plaktuku.
b) ask patient to let his mouth hang loosely (closed and jaw relaxed); place forefinger in midline between lower lip and chin; percuss your finger with tendon hammer:

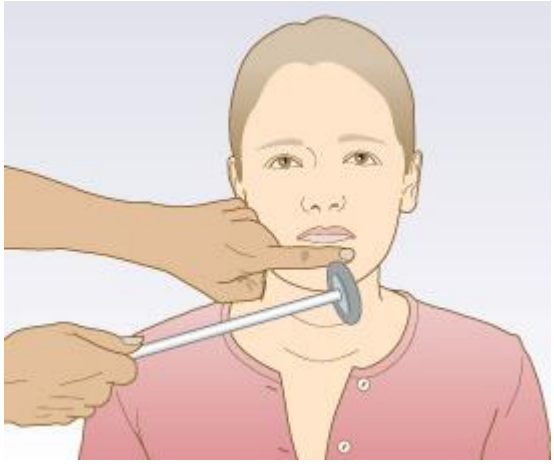

lesions *distal to ganglion* - highly focal, circumscribed deficit within *one division / subdivision*;
***ganglion* lesions** - ipsilateral *hemifacial* sensory loss*;
lesions of *individual trigeminal nuclei* (brain stem) - *dissociated sensory loss* (pain, temperature, and light touch sensory modalities are differentially affected).

**hemifacial* sensory loss:
a) *abruptly stops* at midline - suspect nonorganic causes!
b) *subtle gradation* from affected to normal side.

further identification of malingering / hysterical patients - testing ***vibratory sensation on frontal bone*** - physiological impossibility of differences in vibratory sensation when applying tuning fork to the same albeit "right" or "left" bone.

Infant child - sensory function is documented by facial grimacing from pinprick (away from eye) or by stimulating nostril with cotton tip.

<u>Skausmingumas</u> šakų išėjimo vietose (trigger points) (*trigeminal neuralgia*, *postherpetic neuralgia*) - spausti su pirštais:

a) virš antakių - *foramen supraorbitale*
b) fossa canina - *foramen infraorbitale*
c) smakras - *foramen mentale*

MOTOR - **<u>kramtomųjų raumenų f-ja</u>**:

- ***sukanda dantis*** („Clench teeth") - pridėti rankas prie *m. masseter*, po to *m. temporalis* – bulk and symmetry:

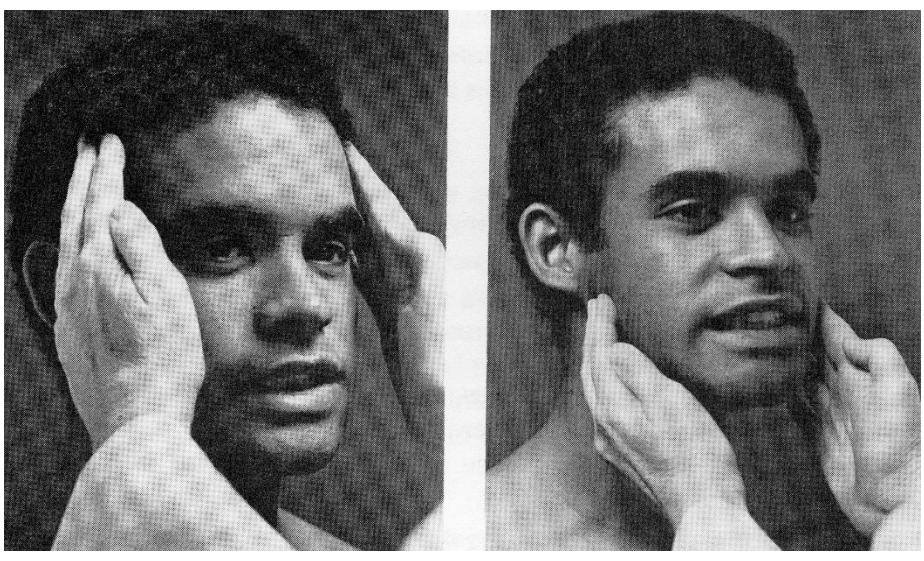

- ***stengiasi išsižioti esant pasipriešinimui*** (mandibula nukryps į nusilpusio *m. pterygoideus* pusę - periferinis CN5 paralyžius; centrinis - mandibula refleksas↑);
  if it is difficult to open mouth against resistance, some degree of CN7 weakness is likely!
- **jaw jerk reflex**. *see above >>*

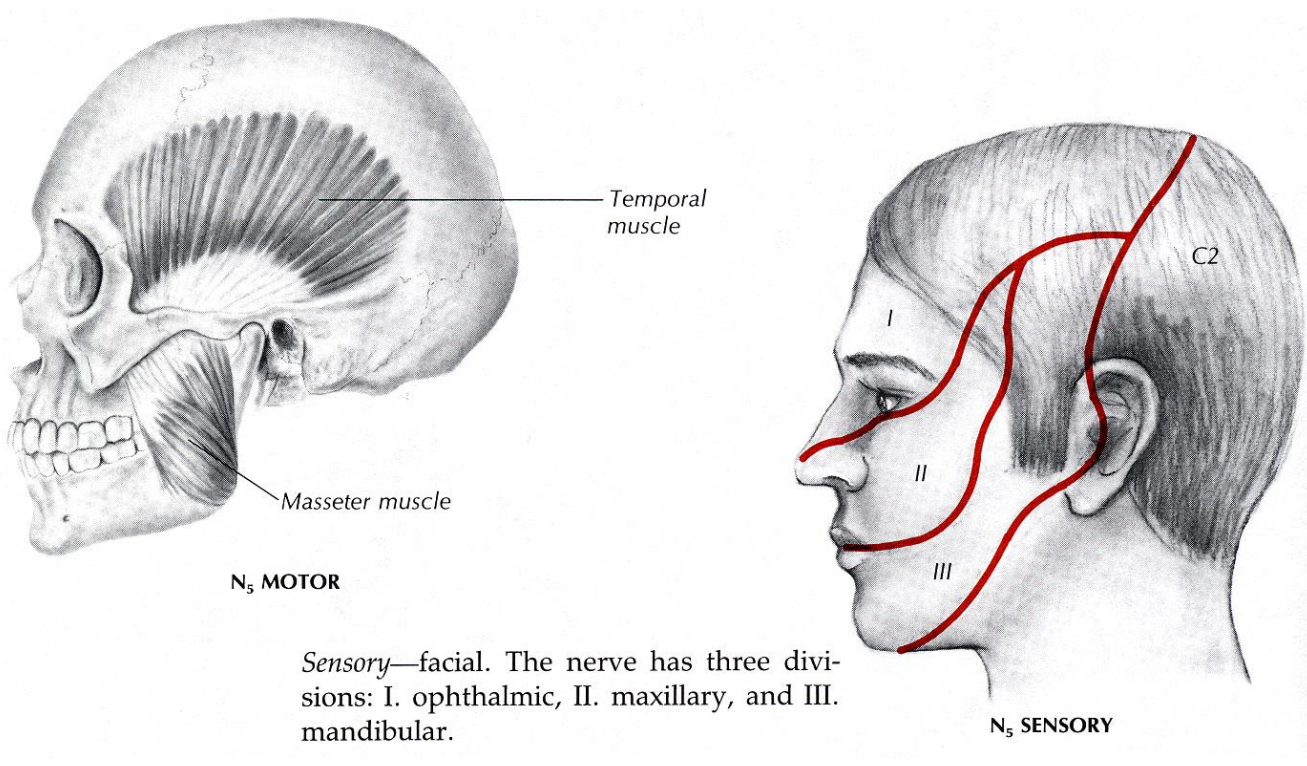

Sensory—facial. The nerve has three divisions: I. ophthalmic, II. maxillary, and III. mandibular.

CN7 (N. FACIALIS)

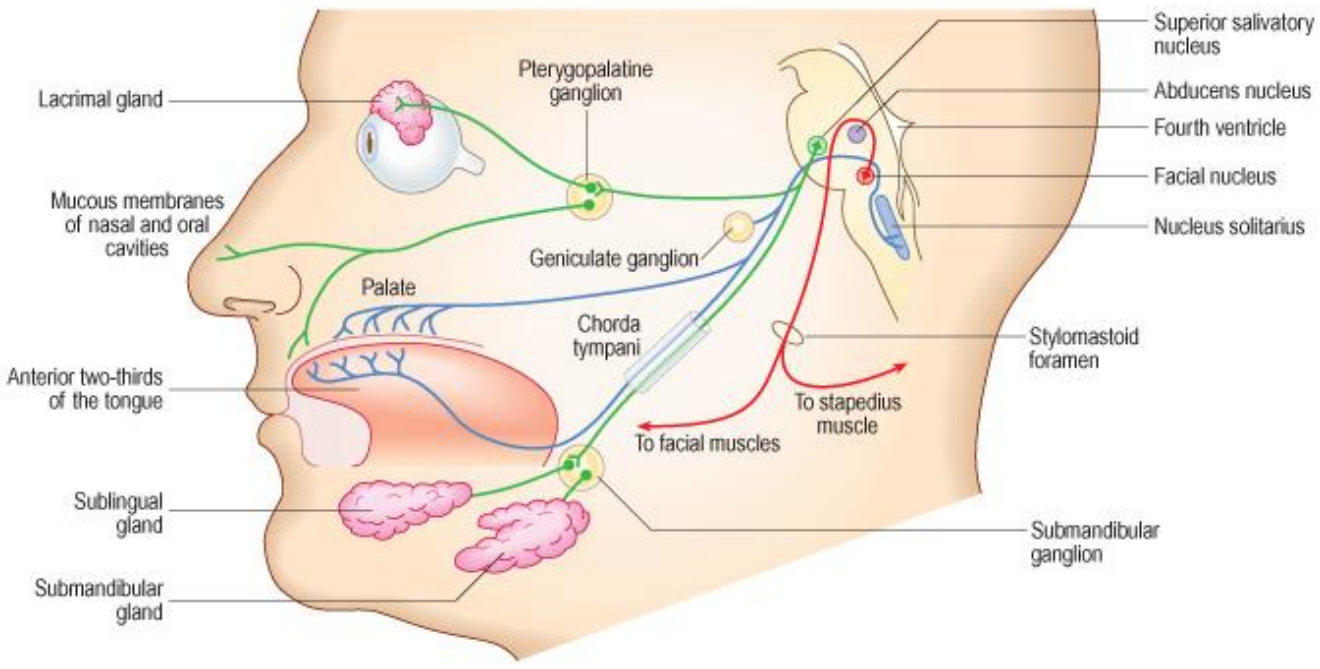

motor; sensory; parasympathetic

MOTOR (simetriškumas! + upper face vs. lower face!) - demonstrate yourself and then asking patient to mimic:

1) **frown** (wrinkle) **forehead, raise eyebrows** (or look up above his head)
2) **close eyes tightly** so that you cannot open them (test muscle strength by trying to open them by retracting lower lid); "Screw your eyes tightly shut and stop me from opening them"
   – slowed blinking.
   – **BELL phenomenon** - upward and outward rolling of globe when eyelid closure is attempted (negalint užsimerkti, obuolys refleksiškai nukrypsta link ašarų liaukos – ragenos apsauga).
   – testing for eyelid position → see p. D1eye >>

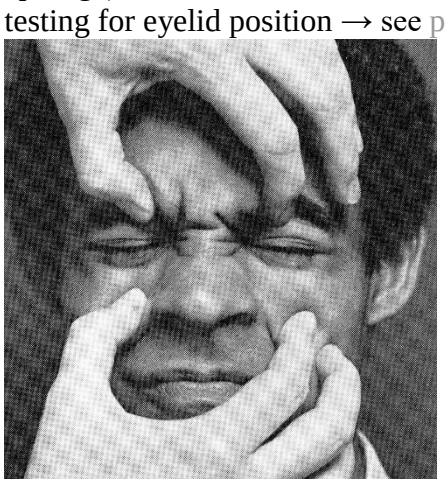

3) **bare teeth, smile, puff out cheeks, pašvilpti**
   "Blow out your cheeks with your mouth closed"
   – flattening of nasolabial groove, loss of facial wrinkles.
   – pronounce **LABIAL SOUNDS** (*dizartrija*) – M, B, P.
   "Say 'baby hippopotamus'"

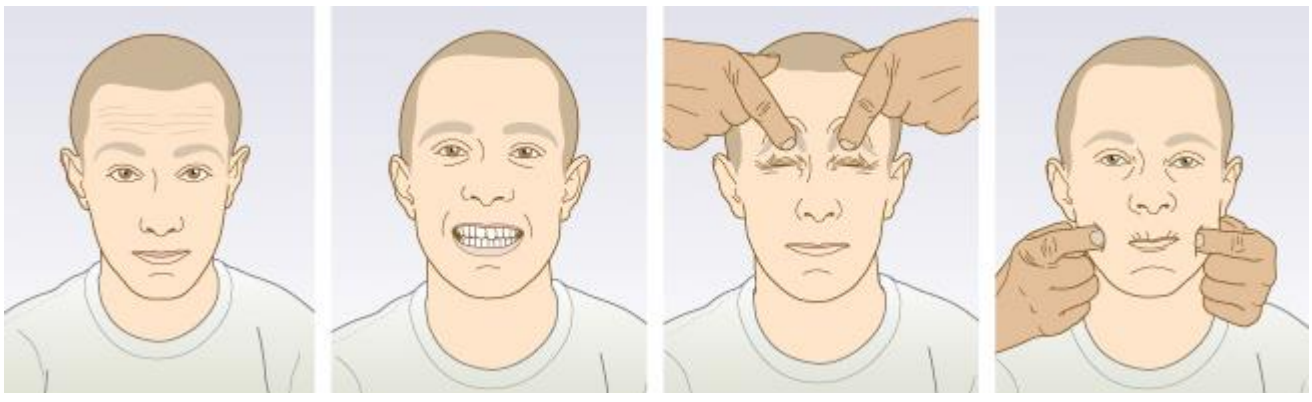

- detailed examination of peripheral branches:
  1) TEMPORAL - raise eyebrows, wrinkle brow;
  2) ZYGOMATIC - close eyes, ***corneal blink reflex***;
  3) BUCCAL - smile, show teeth, puff out cheeks;
  4) MANDIBULAR - pout, purse lips;
  5) CERVICAL - sneer.
- do not confuse *transferred contralateral motion* with weak motion of involved side (H: holding skin of uninvolved side against facial skeleton, midfacial motion from contralateral side can be minimized).
- do not confuse active eye closure with normal, *gravity-assisted passive eyelid closure*.
- check preservation of ***emotional facial expressions*** (e.g. surprise, pain).
- **CHVOSTEK sign** – plaktuku / pirštu nestipriai sudavus tarp skruosto lanko ir lūpos kampo (just anterior to auditory meatus), toje pusėje trukteli burnos, nosies, voko raumenys (facial irritability in tetany).
- HYPERACUSIS (may be detected with vibrating tuning fork held next to ear) → objective acoustic reflex testing.

PARASYMPATHETIC - burnos džiūvimas, ašarų sekrecija.
SCHIRMER test:
– standard sterile filter paper strips are folded into shape of hook and placed into each lower conjunctival fornix.
– after 5 minutes, degree of wetting is measured and compared between sides.

unilateral reduction > 30% of total amount of lacrimation of both eyes or **bilateral** tearing < 15-25 mm is considered abnormal.

SENSORY - skonio jutimas liežuvio priekiniais 2/3.
- patient must not to eat / smoke for several hours before testing.
- before each test solutions are applied, mouth is rinsed with DISTILLED WATER.
- *to eliminate olfaction*, patients should pinch their nose or hold their breath during testing.
- cotton-tipped applicators moistened in appropriate solution are placed on lateral margin of protruded (!) tongue halfway back from tip - ligonis parodo kortelę su skonio užrašu: **salt** (NaCl), **sweet** (sugar), **bitter** (quinine), **sour** (lemon or vinegar), **unknown**, **without taste**.
  N.B. instruct patient not to speak during test!
- each side is tested separately.

CN8 (N. VESTIBULOCOCHLEARIS)

→ see p. D1ear >>

CN 9-10

- warn patient that you are going to test his **gag reflex** (CN9 → CN10): tactile stimulation of walls of pharynx (CN9) or posterior tongue, faucial pillars (CN10) - use blunt object (e.g. tongue blade);

apply stimulus to both sides in turn → symmetrical contraction and elevation of pharynx and tongue retraction.

N.B. *bilateral absence* of gag reflex may be normal (esp. in elderly, smokers)!

- **skonio jutimas** liežuvio užp.1/3 – CN9
- **kalba** – CN10:
  - PALATAL SOUNDS ("nasal speech" - inability to close nasal passage by palate elevation during phonation, allowing air to escape into and resonate within nasal cavity) - *dysarthria*;
  - HOARSENESS (hoarse, breathy voice with reduced volume) – *dysphonia* (→ perform *LARYNGOSCOPY*) .
- gomurio lankų ir uvula **padėtys** (ramybėje ir tariant "a" – liežuvėlis nukrypsta į sveiką pusę, sveikoje pusėje pakyla velum palati) – CN10.
- ask to **puff out cheeks with lips tightly closed** → look / feel for air escaping from nose.
- **rijimas** (ryti vandenį, duoną – DYSPHAGIA - liquids escape into nasal cavity) – CN10
- **pulsas** (bilateral CN10 damage → TACHIKARDIJA).
- **kvėpavimas** (bilateral CN10 damage → DYSPNEA, gręsianti asfiksija); in unresponsive, intubated patient, suctioning endotracheal tube should ***trigger coughing***.
- **carotid sinus reflex**: carotid artery massage → bradycardia (CN9 → CN10).

  N.B. carotid artery massage is impractical, unreliable, and potentially dangerous! (risk of asystole or ventricular arrhythmia)
- **oculocardiac reflex (ASCHNER reflex)**: pressure upon eyeball 20-30 sec → slight bradycardia (CN5 → CN10).

Heart rate is influenced by numerous factors - testing reflexes is not reliable!

CN10 palsy on left side (soft palate deviates toward healthy side during phonation):

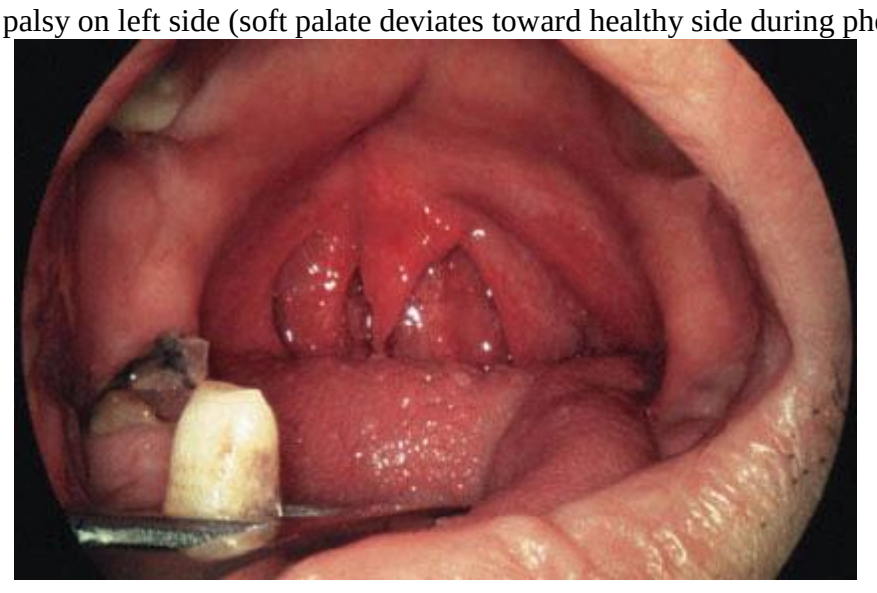

CN11 (N. ACCESSORIUS)

M. sternocleidomastoideus

- face patient - inspect sternocleidomastoid muscles for wasting / hypertrophy and palpate them to assess their bulk.
- turn chin completely toward one shoulder (against resistance!) – **contralateral** *m. sternocleidomastoideus (sternal head)*.

  N.B. examiner must press against patient's cheek rather than mandible (← this would also depend on lateral pterygoid muscle)!
- flex neck while examiner exerts firm pressure on forehead - **bilateral** *m. sternocleidomastoideus*.



M. trapezius

- stand behind patient - inspect trapezius muscle for wasting or asymmetry.
- elevate or shrug shoulders and maintain this movement against resistance (!) – rostral *m. trapezius*.
- extend arms forward and horizontally (winging of scapula?) – rostral *m. trapezius*.

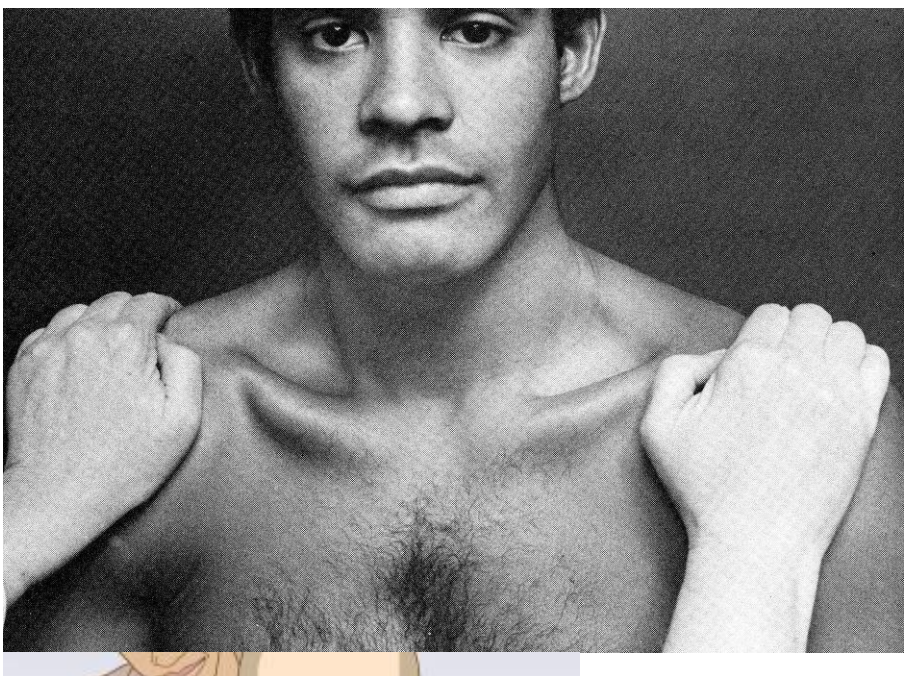

CN12 (N. HYPOGLOSSUS)

- liežuvio ***atrofija*** (palpate; ryškiausia pakraščiuose ir gale) ir ***fascikuliacijos***; percuss with hammer (for ***myotonia***).
- liežuvio padėtis:

  BURNOJE (pasislinkęs į sveiką pusę – intaktiškas *m. styloglossus*).

  IŠKIŠTO (nukrypsta į paralyžuotą pusę – intaktiškas *m. genioglossus*); *jei neaišku ar nukrypsta*:

  a) pridėti liežuvį prie viršutinės lūpos (bet gali klaidinti prie CN7 parezės)

b) sulyginti liežuvio raphe su centriniu tarpdančiu.

- speed and range of motion - wiggle tongue rapidly from side to side, point tip upward and downward.
  "Stick out your tongue. Place it on upper lip, move it side to side"
- strength of motion - **press tongue into cheek** – examiner feels from outside mouth and compares strength symmetry on both sides.
- **LINGUAL SOUNDS** (*dysarthria*) – T, D, L. "Say 'yellow lorry'"
- **DYSPHAGIA** (initial stage of swallowing).

Infant child – pinch nostrils; this will produce reflex mouth opening and tongue tip raising (in CN12 paresis, tongue tip will deviate toward affected side).

CEREBROVASCULAR - AUTONOMIC NS EXAMINATION

PUPIL & OPHTHALMOSCOPY

→ see p. D1eye >>

LACRIMAL SECRETION

→ *see above* >>

CARDIOVASCULAR SYSTEM

1. PALPACIJA (švelni!):
   1) **a. temporalis superficialis** (just in front of ear) - enlargement or tenderness?
   2) **a. carotis** pulse

2. AUSKULTACIJA (with bell-type stethoscope):
   1) pradedama nuo ***aortos vožtuvo*** → ***a. subclavia*** (above and below clavicle) – kad ekskliuduoti aortos vožtuvo ūžesių transmisiją į a. carotis.
   2) kaklo auskultacija (galva pasukta į priešingą pusę) - auskultuoti:
      a) už *m. sternocleidomastoideus* (a. vertebralis)
      b) prieš *m. sternocleidomastoideus*, kylant iki už angle of mandible (a. carotis com. bifurkacija - cart. thyroidea viršutinis kraštas, 3 cm below angle of mandible).
   3) smilkinių
   4) processus mastoideus
   5) akių

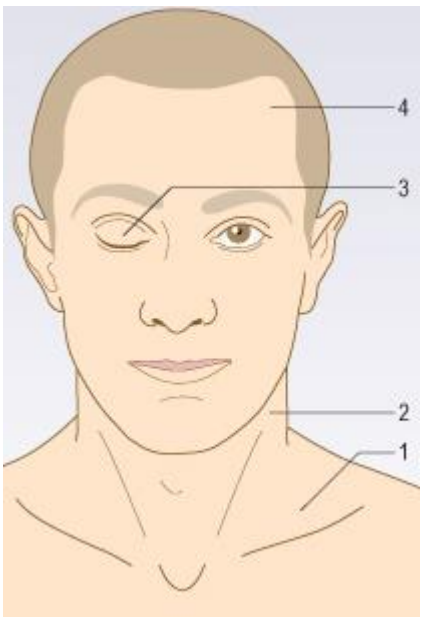

Ūžesių karotidinėje zonoje difkė:

a) **arterijos stenozė** - ūžesys girdimas tik ties arterija sistolės metu ir yra high-pitched (ūžesys vadinamas **bruit**);
b) radiacija nuo **AoV stenozės** - ūžesys sistolinis, stipriausias in upper precordium ir plinta į kaklą silpnėdamas (ūžesys vadinamas **murmur**);
c) **normali kraujo turbulencija** juguliarinėse venose - dažnas vaikams, girdimas pastoviai (šiek tiek stipresnis diastolės metu), low-pitched, geriau girdimas vertikalioje padėtyje, išnyksta užspaudus juguliarinę veną (ūžesys vadinamas **venous hum**); venous hum gali kilti ir labai vaskuliarizuotoje strumoje.

3. Aritmijos, pulsas **Valsalva mėginio** metu (lack of bradycardia-tachycardia?).

4. **AKS** abiejose (!) rankose (test for painless aortic dissection as cause of stroke!).
   - Cushing response (to ICP↑) – hypertension, bradycardia.

5. **Orthostatic vital signs**:
   – stovintis ligonis palengva atsigula;
     normal **clinostatic reflex** - per pirmąsias 15-20 sek pulsas sulėtėja 4-6 tvinksniais, o AKS sumažėja 5-10 mmHg.
   – dažniausiai skriningas pradedamas nuo to, kad gulintis ligonis (pamatavus AKS ir pulsą*) palengva pasodinamas ir, jei neatsiranda simptomų, palengva atsistoja ir pastovi 3 minutes (or just sits up with legs dangling for 5 minutes);
     normal **orthostatic reflex** - ***pulsas*** padažnėja < 10 k/min, ***sistolinis AKS*** šiek tiek sumažėja [< 10 mmHg], o ***diastolinis AKS*** nepakinta ar padidėja < 20 mmHg.
     jei atsiranda bet kokie simptomai (svaigimas, dusulys, krūtinės skausmas), pacientą reikia tuoj pat atgal paguldyti.
     *jei yra tachikardija ir AKS↓, ortostatinis mėginys neatliekamas

Orthostatic hypotension - reproducible fall in systolic BP > 20 mmHg or in diastolic BP > 10 mmHg (+ elevation in pulse > 20 beats/min) within 3 minutes of adopting erect position and sustained for at least 3 min (vs. sluggish baroreflex responses in elderly – BP restores to normal); in **severe orthostatic intolerance**, monitor length of time patient can stand in place before he experiences symptoms (severe orthostatic hypotension → "standing time" < 30 seconds).

If reflex tachycardia is present, *hypovolemia* should be excluded! (only *orthostatic* hypotension - blood volume deficit 20 - 40%; systolic BP < 90 mmHg in *supine* position - blood volume deficit ≥ 40%).

If no reflex tachycardia – consider *autonomic dysfunction*.

6. **Oculocardiac (Aschner) reflex** *see above* >>

7. **Carotid sinus reflex** *see above* >>

8. Skausmingi vegetaciniai **Virbrairo-Markelovo taškai**:

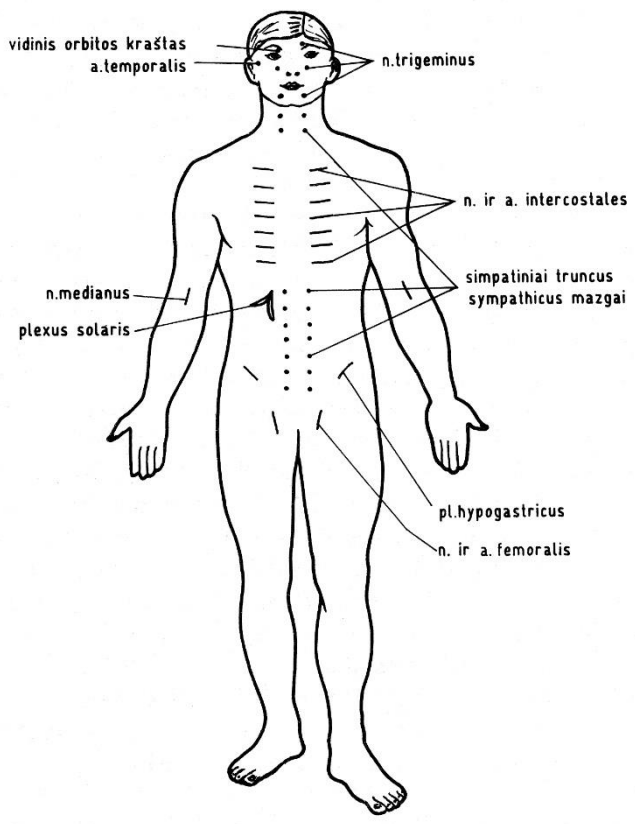

SKIN

1. **Dermografizmas** - buku daiktu ar adatėle braukiant per krūtinės, pilvo odą (normoje kelias sek baltas, po to raudonas nepakilęs pėdsakas).

2. **Loss of sweating** - lightly draw dorsal surface of forefinger (or spoon) up torso skin (starting below expected level of lesion and stroking upward); finger slides easily over smooth dry skin below lesion but sticks momentarily as it meets normal moist skin at upper border of lesion.
   – look also for asymmetrical patterns of **skin temperature** or **color**.

BLADDER & ANUS

1. Ability to initiate and interrupt **micturition voluntarily**.
2. **Bulbocavernosus** and **anal** reflexes.
3. **Scrotal** and **internal anal** reflexes.
4. **Palpation / percussion** of bladder (abnormal bladder distention?).

PERIPHERAL NS EXAMINATION

see also MOTOR EXAMINATION (above) >>

Tiriant periferinę NS, svarbu diferencijuoti – pakenkimas turi **SEGMENTAL*** (dermatome, myotome, sclerotome) ar **PERIPHERAL NERVE** distribution!!! *see p. PN1 >> (radiculopathy)

TINEL'S sign: percussion along course of nerve → paresthesias in nerve distribution.

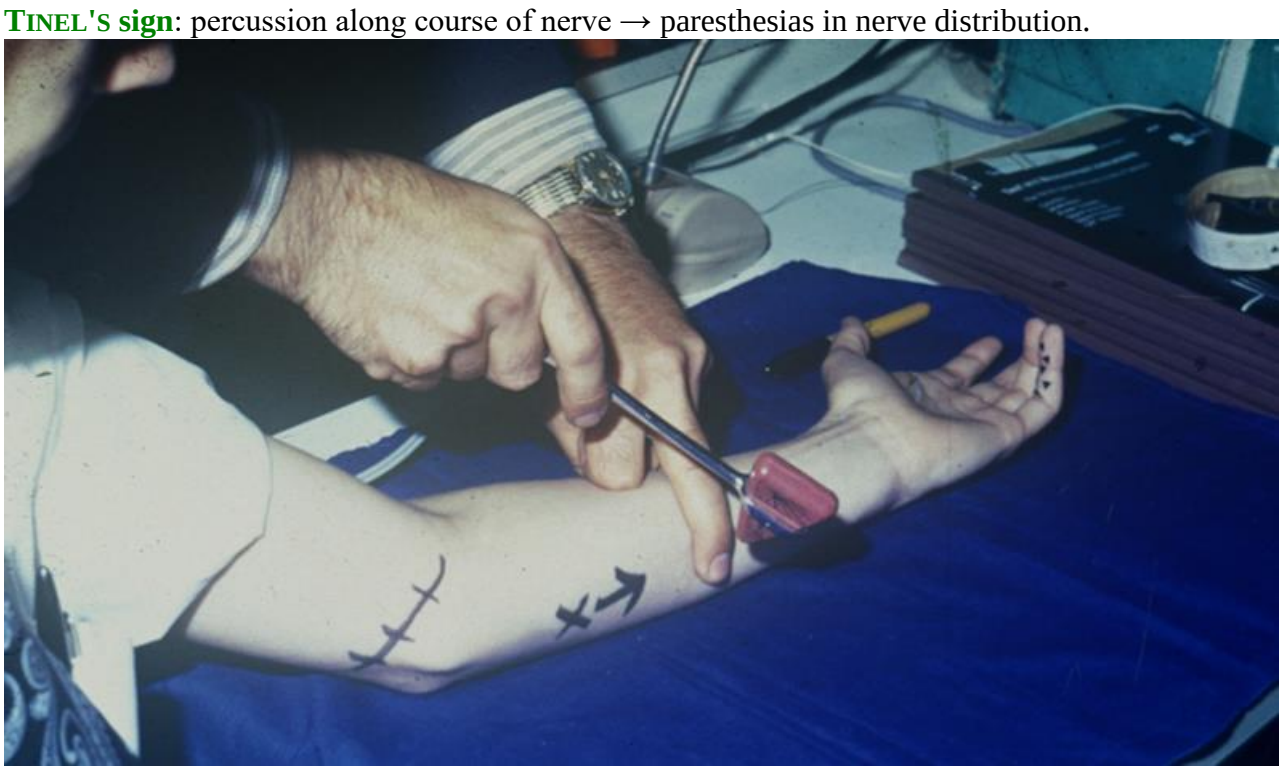

CERVICAL ROOTS

C4

Pain: Top of shoulder, radiating to medial scapula.
Sensory Loss: Supraclavicular fossa.
Motor Signs: Flattening or flabbiness of rhomboid palpated through trapezius as the patient "pulls the shoulders back like a Marine."

C5

Pain: Lateral shoulder and arm.
Sensory Loss: Skin over deltoid muscles.
Motor Signs: Supraspinatus, infraspinatus, deltoid, biceps, brachioradialis. Depressed biceps reflex.

C6

Pain: Radiating from neck to radial side of forearm and thumb.
Sensory Loss: Distal thumb.
Motor Signs: Supraspinatus, infraspinatus, deltoid, biceps, brachioradialis, *and* triceps. Depressed biceps *and* triceps reflexes.

C7

Pain: Radiating from neck to the hand.
Sensory Loss: Middle finger and midpalm.
Motor Signs: Triceps, wrist extension, wrist flexion. Depressed triceps reflex.

> ***Clinician Beware!*** Carpal tunnel syndrome is a common cause of pain in the upper extremity. The pain of carpal tunnel syndrome may exactly mimic the pain of lower cervical root involvement and may be mistaken for a radicular syndrome. If there is no definite weakness or sensory loss proximal to the wrist, consider carpal tunnel syndrome!

C8

Pain: Radiating from neck down ulnar side of arm and forearm toward little finger.
Sensory Loss: Ulnar forearm and little finger.
Motor Signs: Small muscles of the hand regardless of peripheral nerve innervation. Ipsilateral Horner's syndrome defines the lesion as very proximal; on the spinal cord, or in proximal nerve roots within centimeters of the spinal column.

BRACHIAL PLEXUS

Su rankos nykščiu galima pratestuoti visus tris nervus:

ekstenzija – N.RADIALIS (m. extensor pollicis longus et brevis).

opozicija – N.MEDIANUS (m. opponens pollicis).

addukcija – N.ULNARIS (m. adductor policis).

abdukcija – N.RADIALIS (m. abductor pollicis longus) + N.MEDIANUS (m. abductor pollicis brevis).

fleksija – N.ULNARIS (m. flexor pollicis brevis, deep head) + N.MEDIANUS (m. flexor pollicis longus et brevis, superficial head).

	Hand intrinsics	Abductor pollicis brevis
C8 radiculopathy	+	+
Ulnar neuropathy	+	
Median neuropathy		+

DORSAL SCAPULAR NERVE (C4-5)

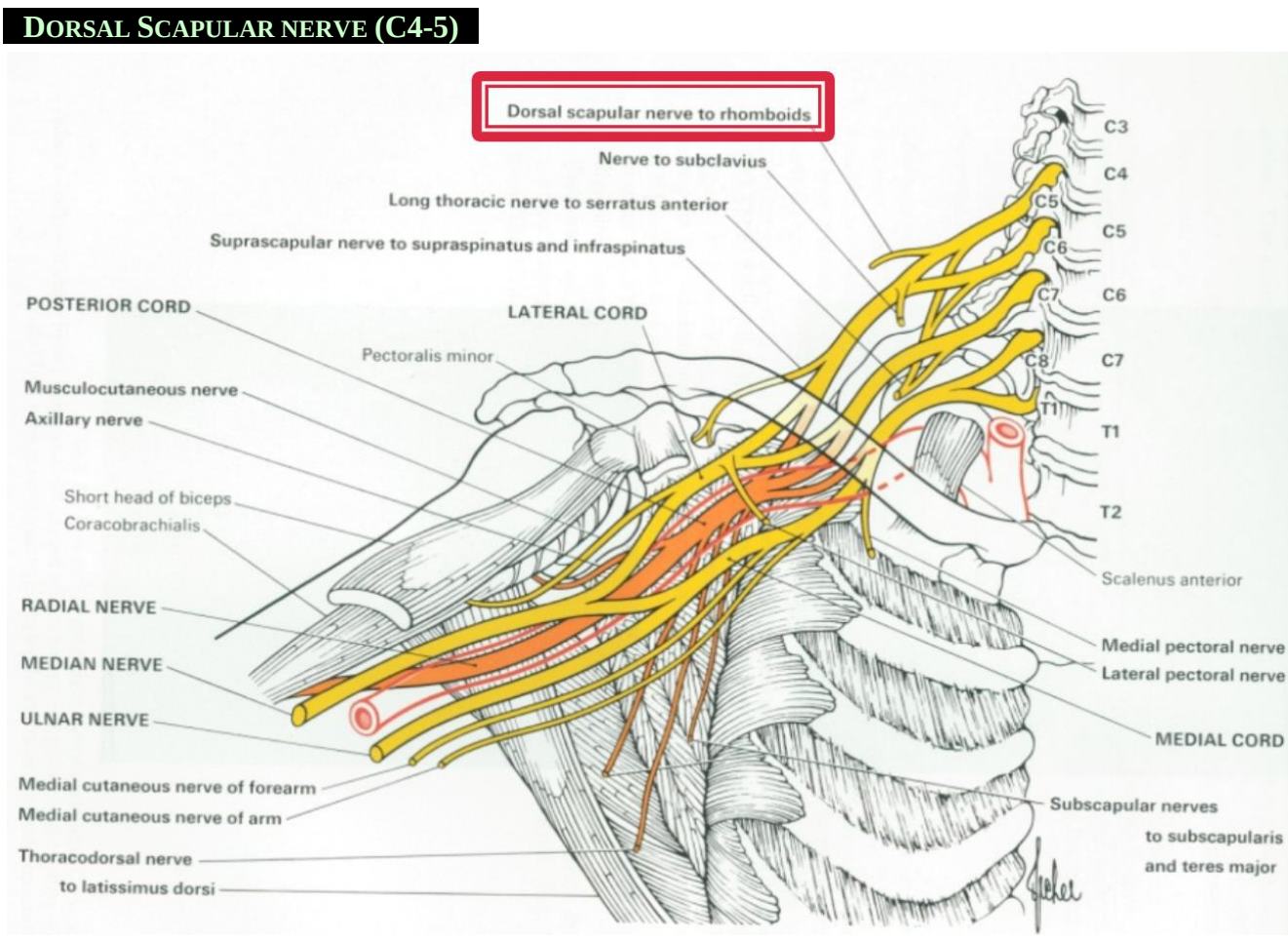

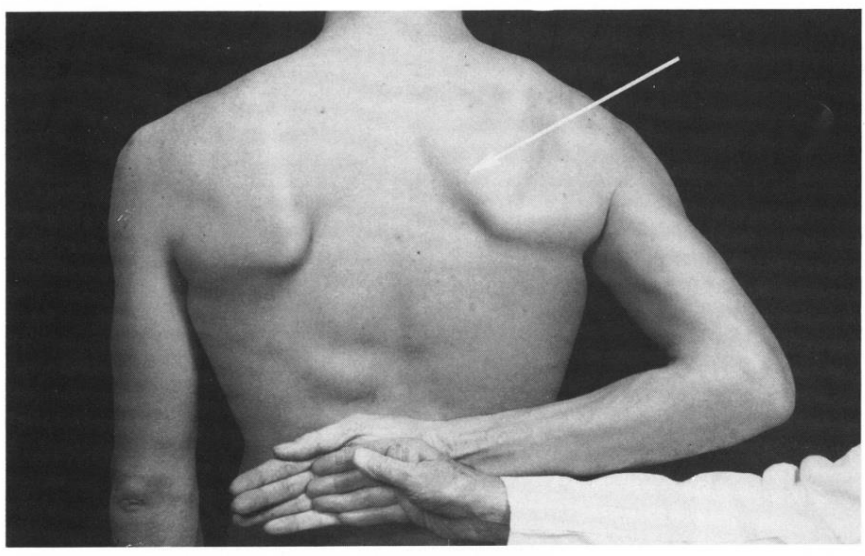

Fig. 4 Rhomboids (Dorsal scapular nerve; C4, C5)
The patient is pressing the palm of his hand backwards against the examiner's hand. *Arrow:* the muscle bellies can be felt and sometimes seen.

LONG THORACIC NERVE (C5-7)

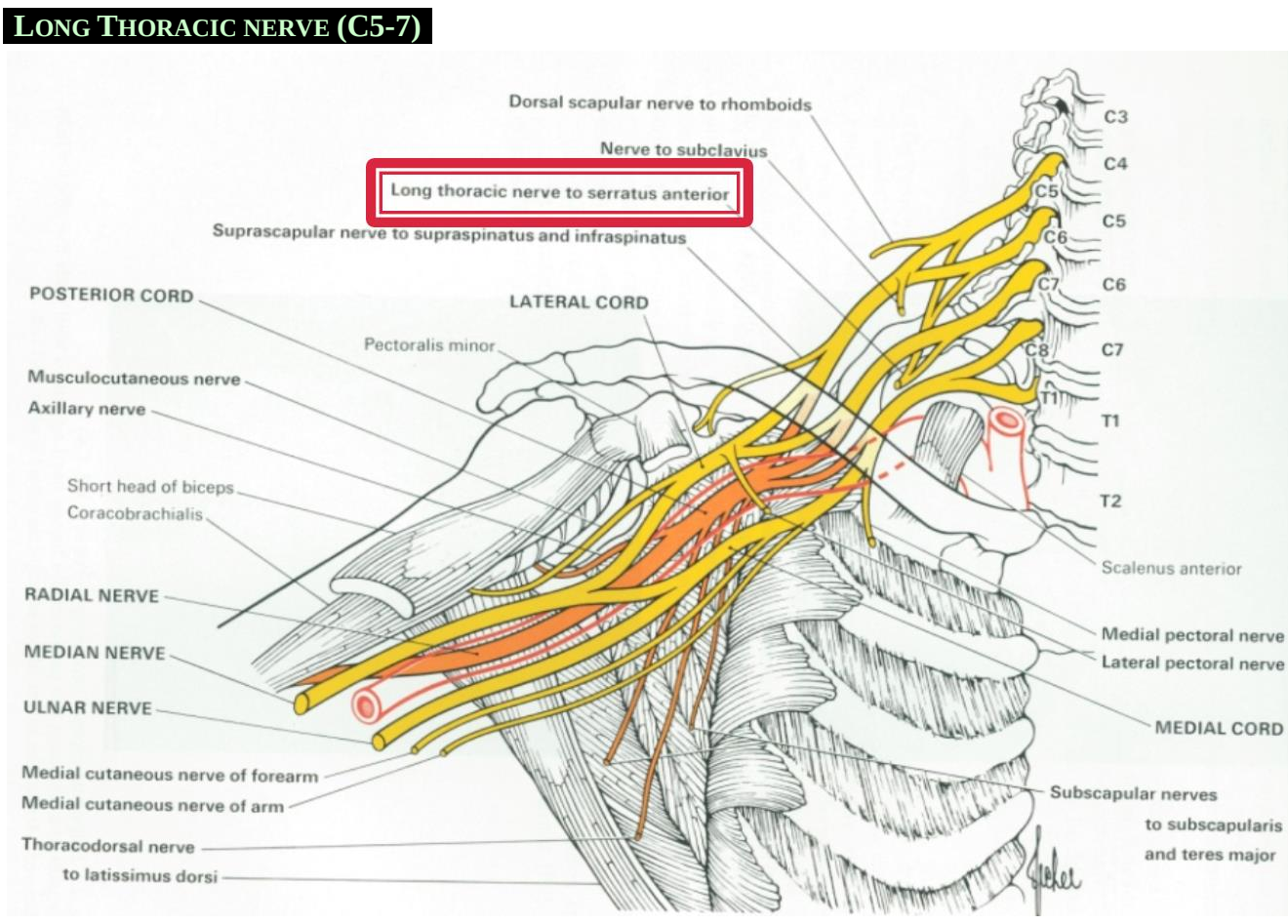

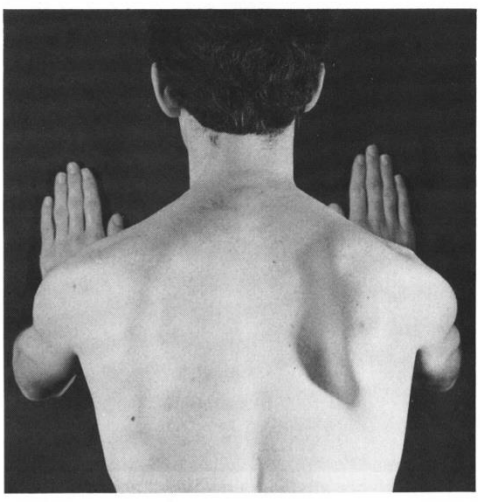

Fig. 5 Serratus anterior (Long thoracic nerve; C5, C6, C7)
The patient is pushing against a wall as in Fig. 2. The right serratus anterior is paralysed and there is winging of the scapula.

- *m. serratus anterior* – "**winged scapula**" (inferior tip of scapula juts backward and medially) – išryškėja, kai:
    a) pacientas ranka bando pastumti į priekį nejudantį objektą (pvz. sieną).
    b) paciento abdukuotą žastą lėtai spaudžiame žemyn link korpuso (pacientas tam priešinasi):

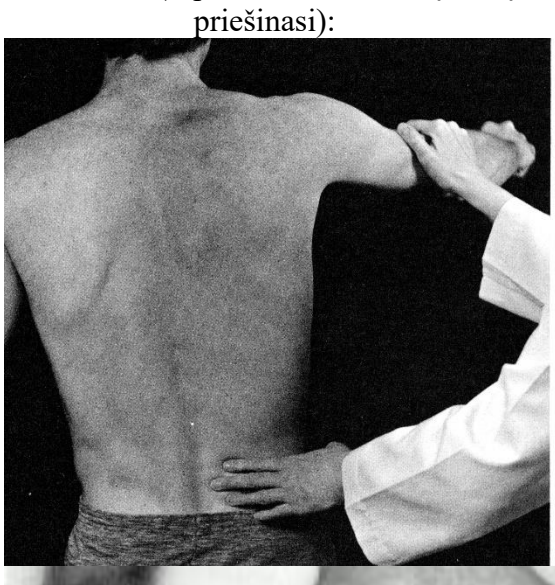

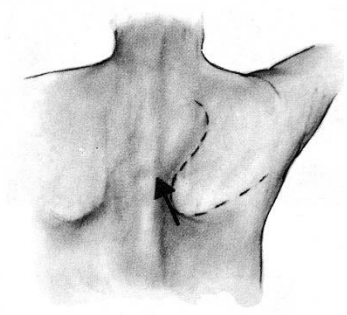

'Winging' of left scapula:

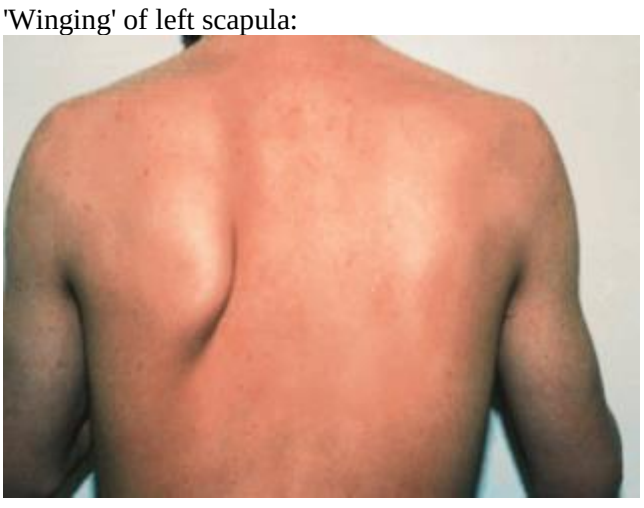

Winging is usually absent when arm is held at side!

LATERAL PECTORAL NERVE (C5-6)

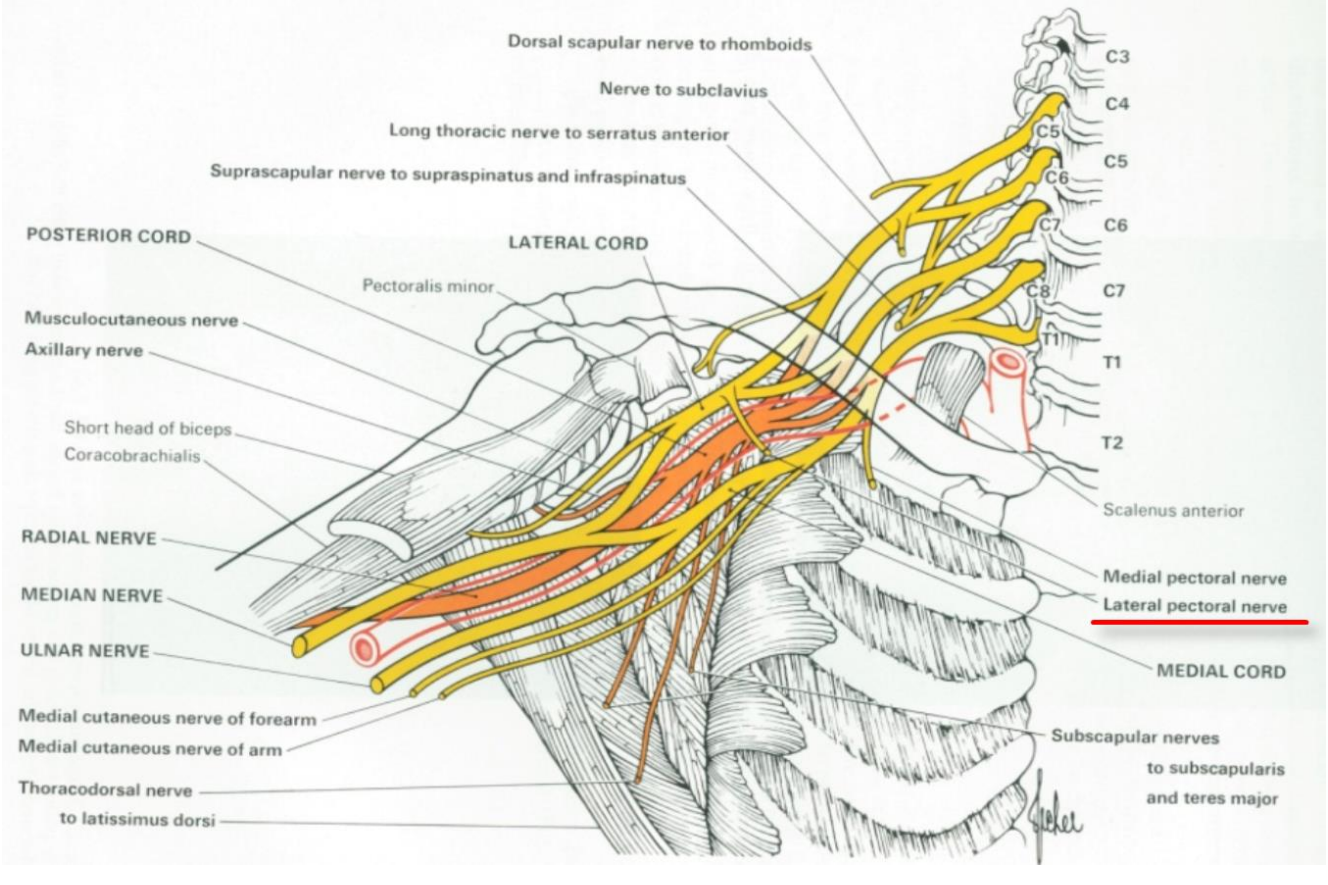



Fig. 6 Pectoralis Major: Clavicular Head (Lateral pectoral nerve; **C5,** C6)
The upper arm is above the horizontal and the patient is pushing forward against the examiner's hand. *Arrow:* the clavicular head of pectoralis major can be seen and felt.

MEDIAL PECTORAL NERVE (C6-7)

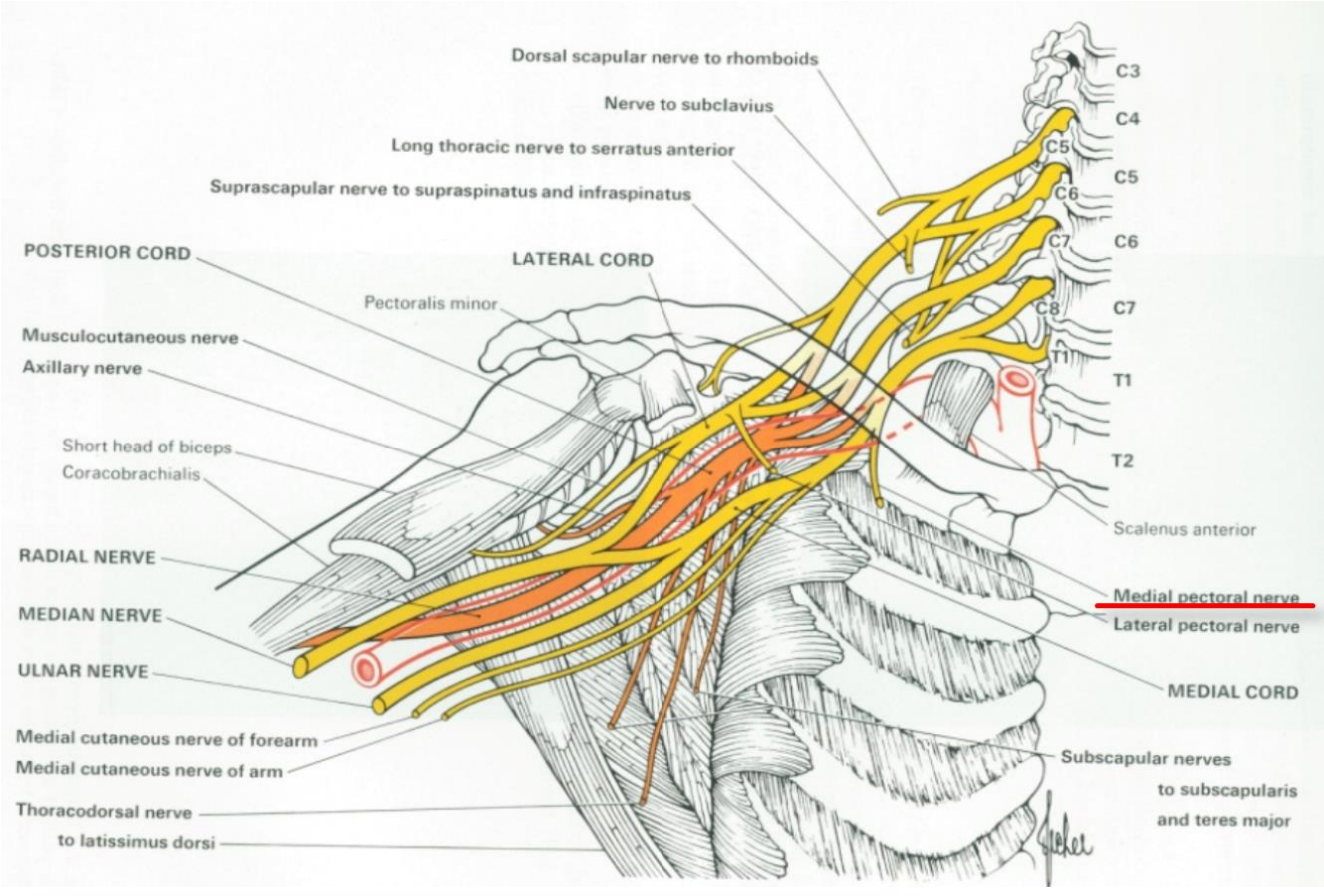

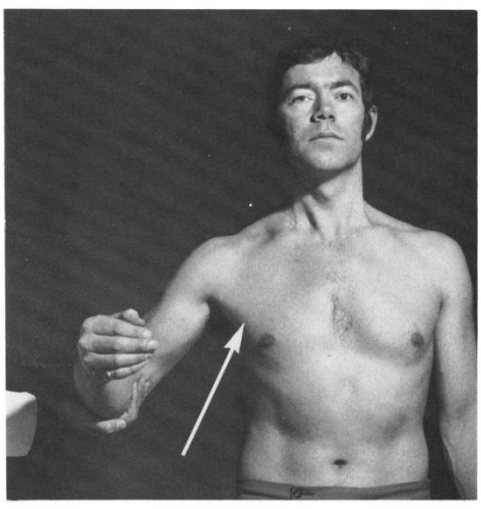

Fig. 7 Pectoralis Major: Sternocostal Head (Lateral and medial pectoral nerves; C6, **C7,** C8)
The patient is adducting the upper arm against resistance. *Arrow:* the sterno-costal head can be seen and felt.

SUPRASCAPULAR NERVE (C5-6)

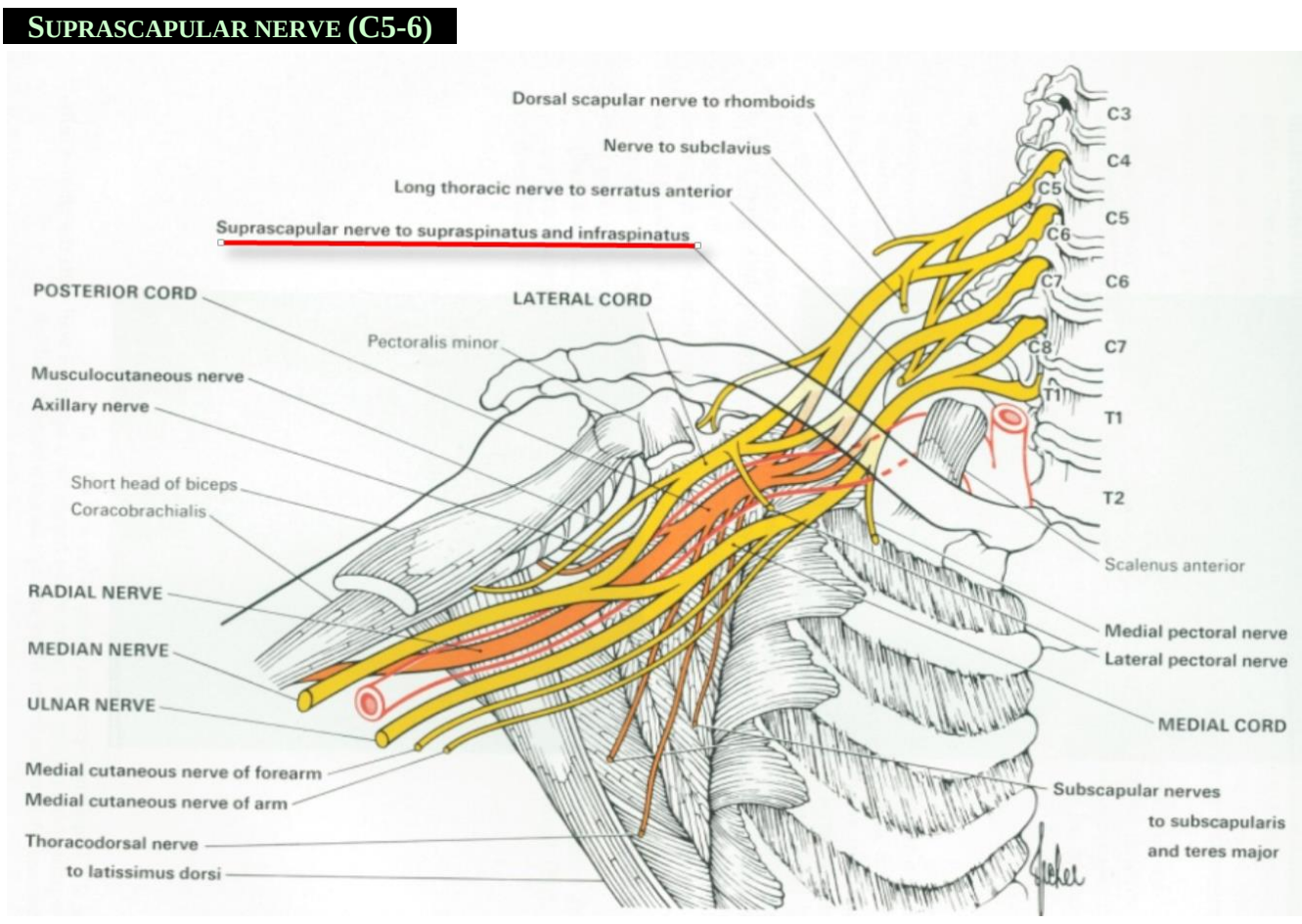

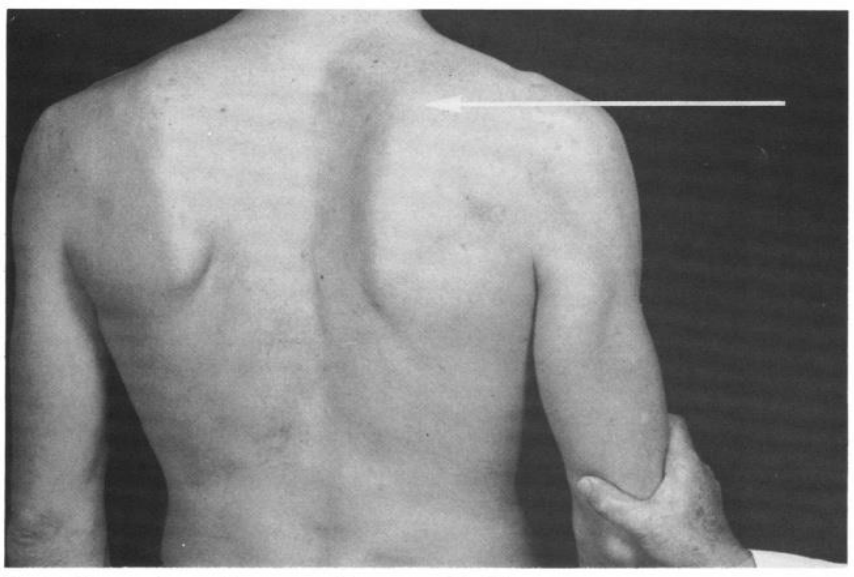

Fig. 8 Supraspinatus (Suprascapular nerve; **C5,** C6)
The patient is abducting the upper arm against resistance. *Arrow:* the muscle belly can be felt and sometimes seen.

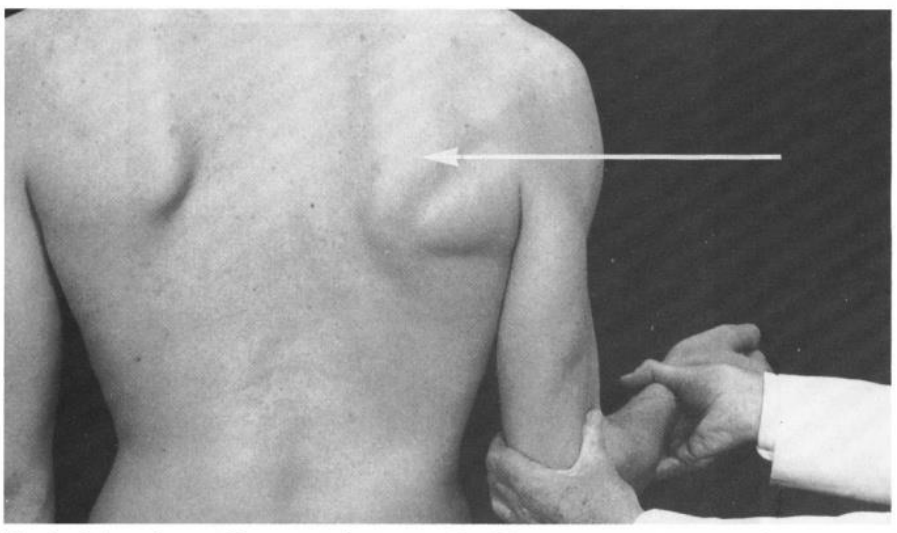

Fig. 9 Infraspinatus (Suprascapular nerve; **C5,** C6)
The patient is externally rotating the upper arm at the shoulder against resistance. The examiner's right hand is resisting the movement and supporting the forearm with the elbow at a right angle; his left hand is supporting the elbow and preventing abduction of the arm. *Arrow:* the muscle belly can be seen and felt.

THORACODORSAL NERVE (C6-8)

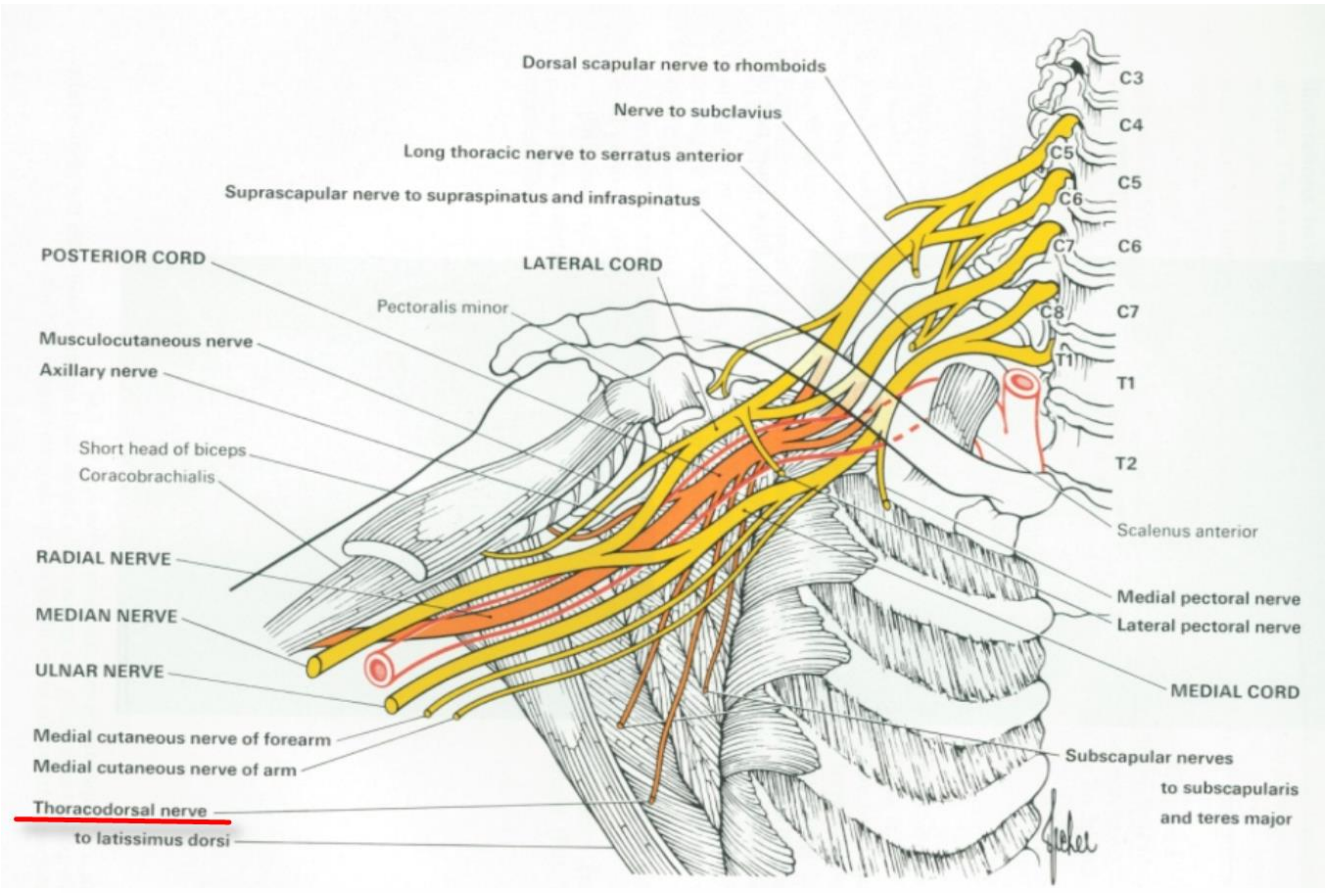



Fig. 6 Pectoralis Major: Clavicular Head (Lateral pectoral nerve; **C5,** C6)
The upper arm is above the horizontal and the patient is pushing forward against the examiner's hand. *Arrow:* the clavicular head of pectoralis major can be seen and felt.

SUBSCAPULAR NERVE (C5-7)

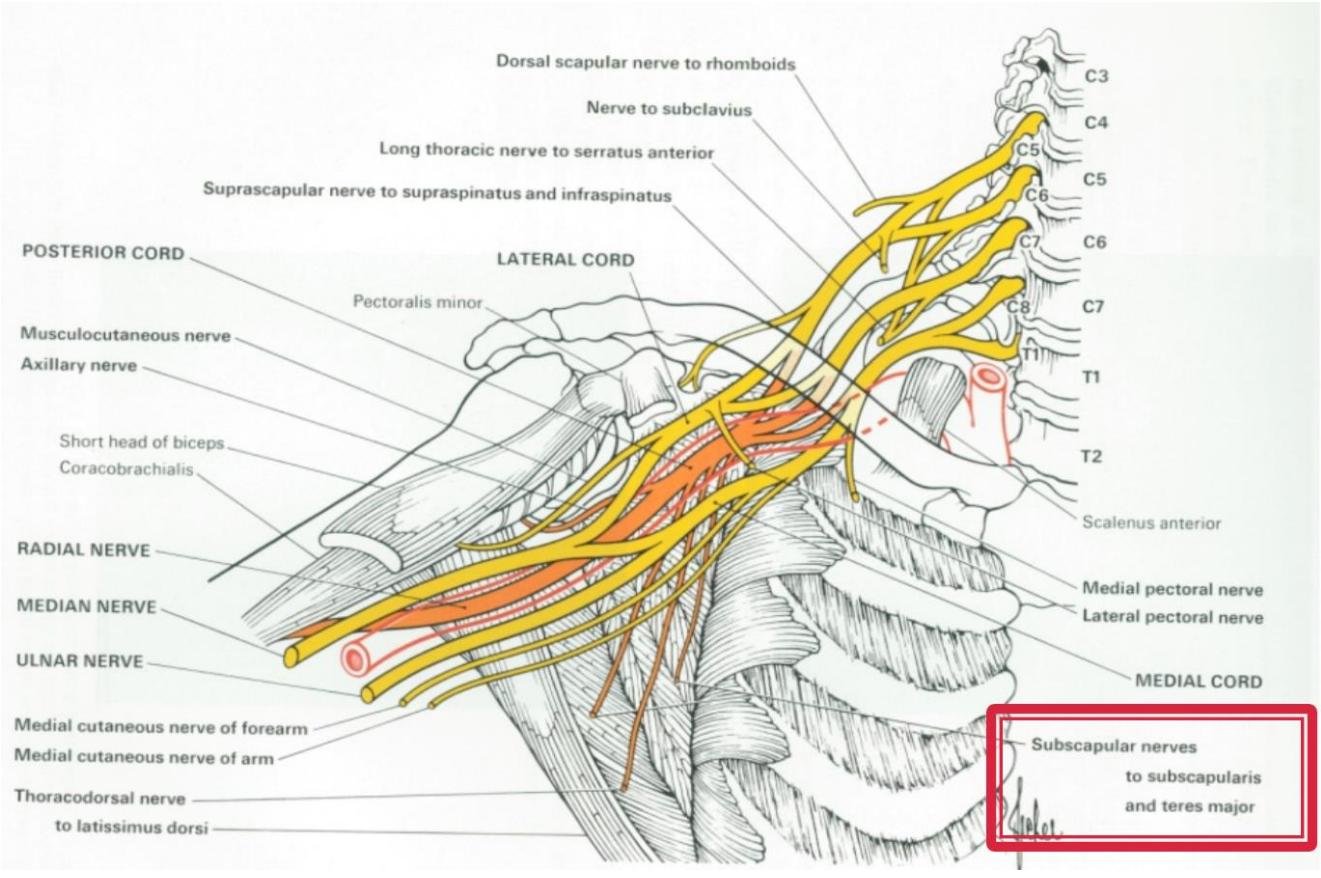

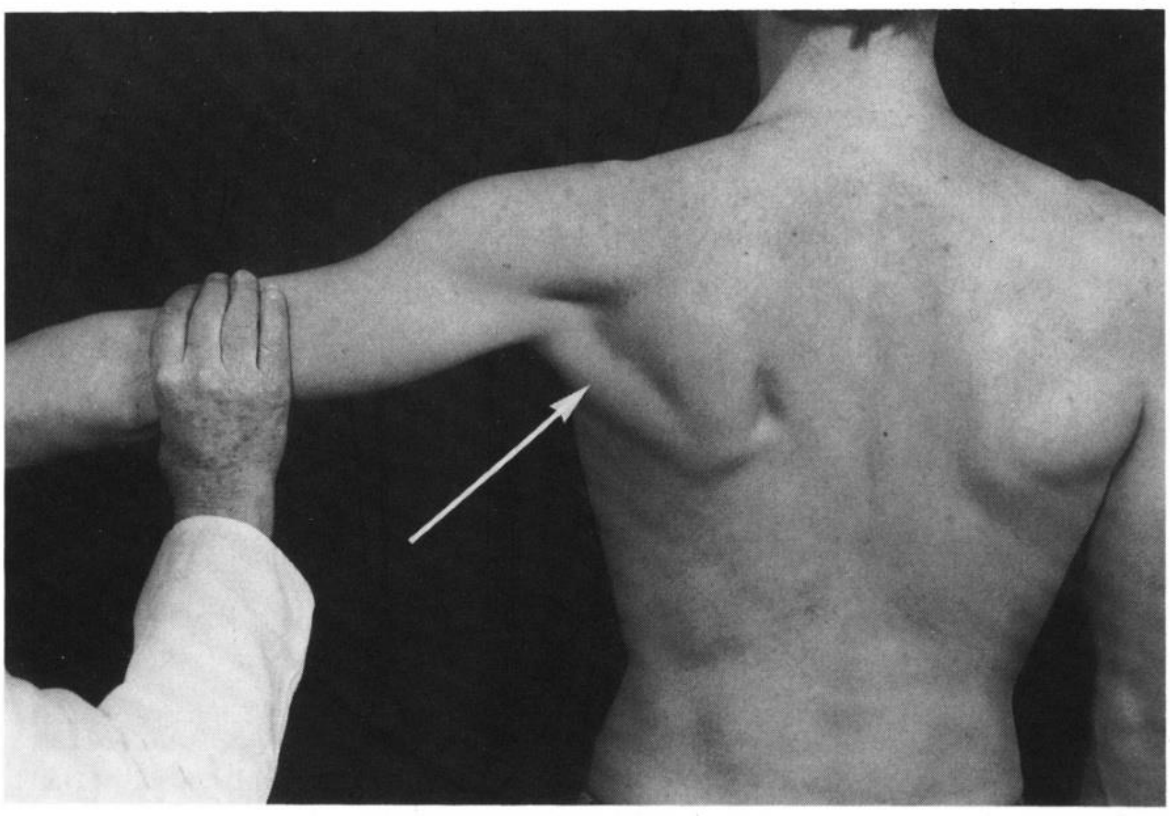

Fig. 12 Teres Major (Subscapular nerve; C5, C6, C7)
The patient is adducting the elevated upper arm against resistance. *Arrow:* the muscle belly can be seen and felt.

MUSCULOCUTANEOUS NERVE (C5-6)

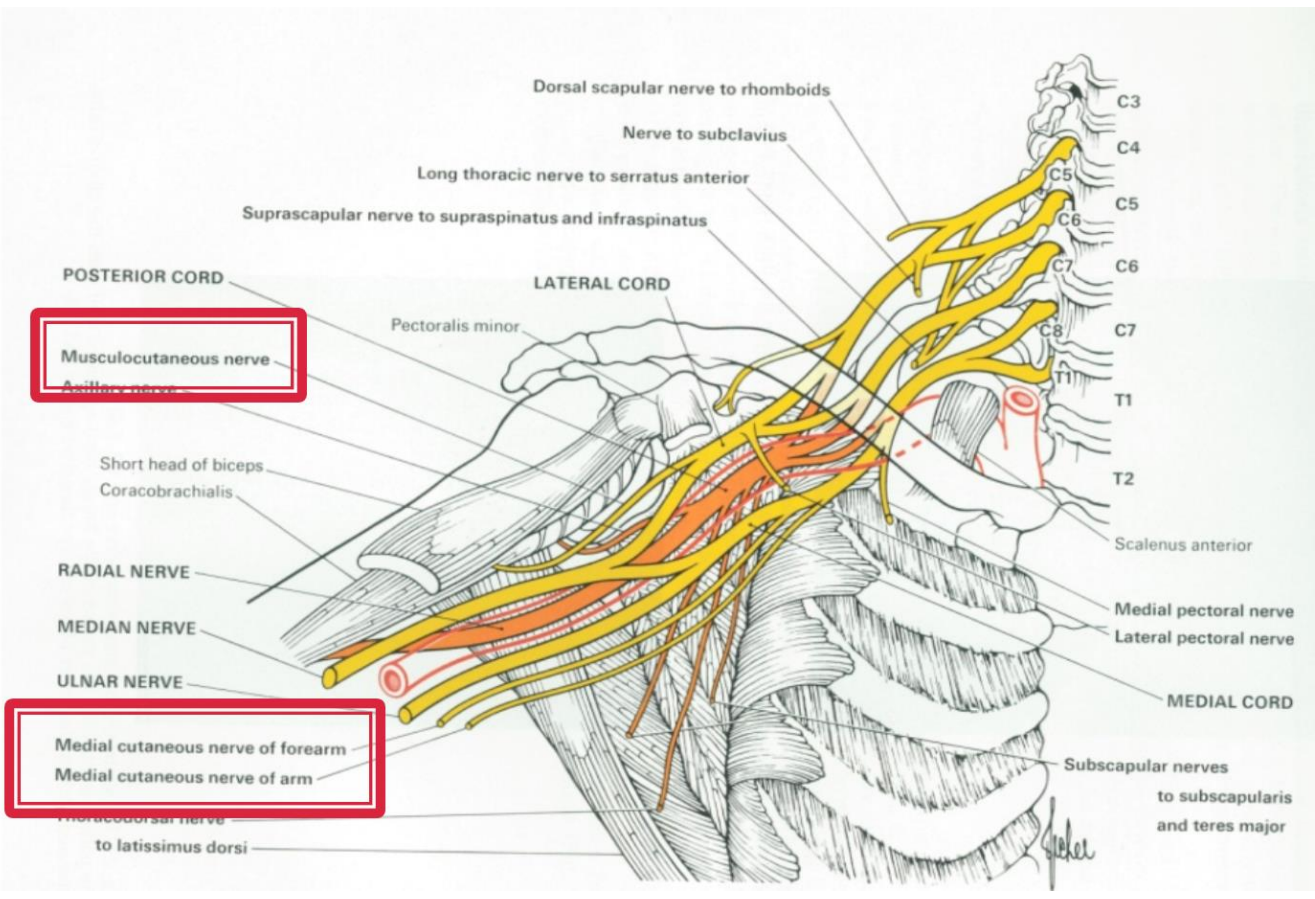

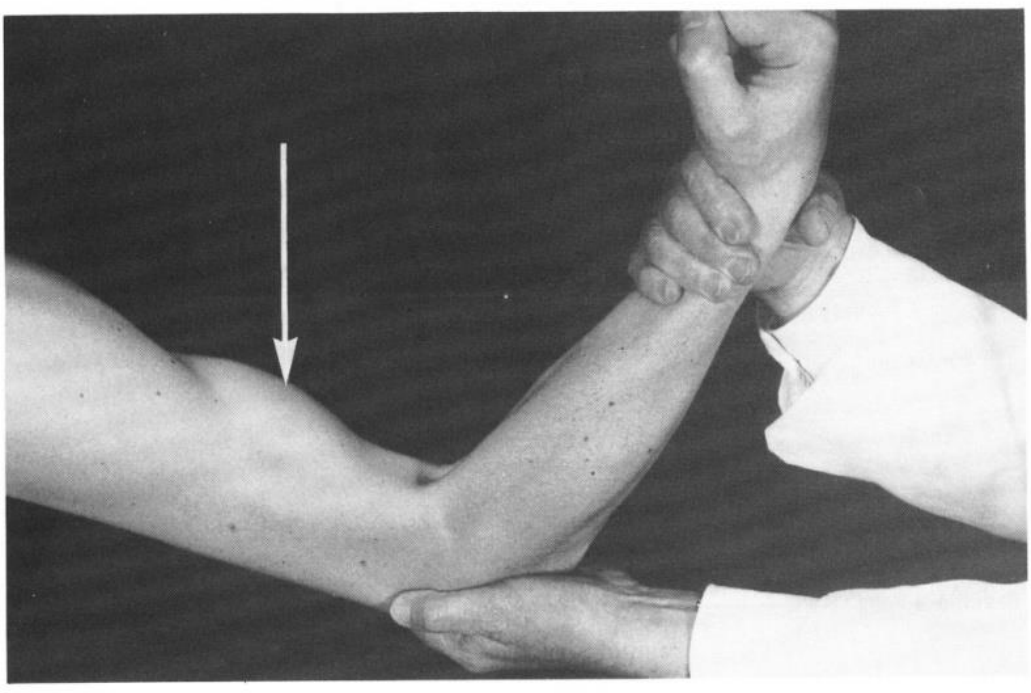

Fig. 14 Biceps (Musculocutaneous nerve; C5, C6)
The patient is flexing the supinated forearm against resistance. *Arrow:* the muscle belly can be seen and felt.

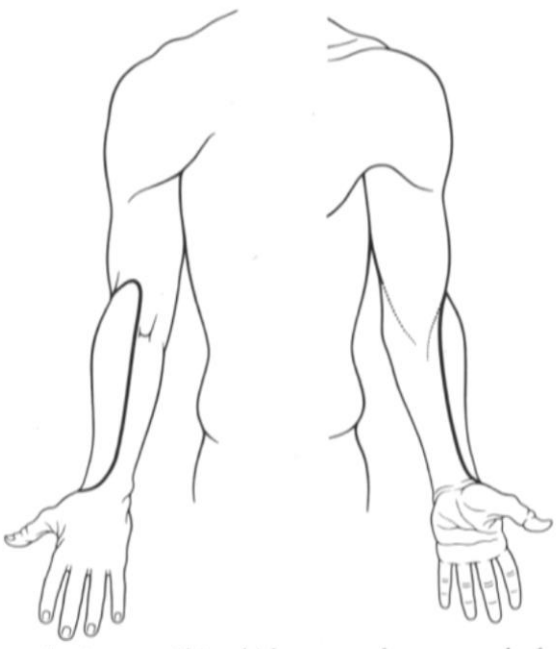

Fig. 73 The approximate area within which sensory changes may be found in lesions of the musculocutaneous nerve. (The distribution of the lateral cutaneous nerve of the forearm.)

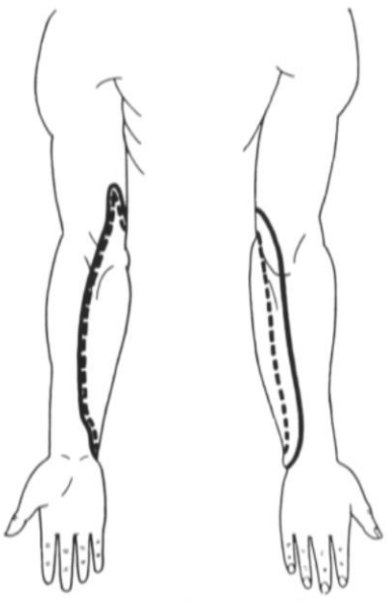

Fig. 74 The approximate area within which sensory changes may be found in lesions of the medical cutaneous nerve of the forearm. Light touch, continuous line; pin-prick, dotted line.

AXILLARY NERVE (C5-6)

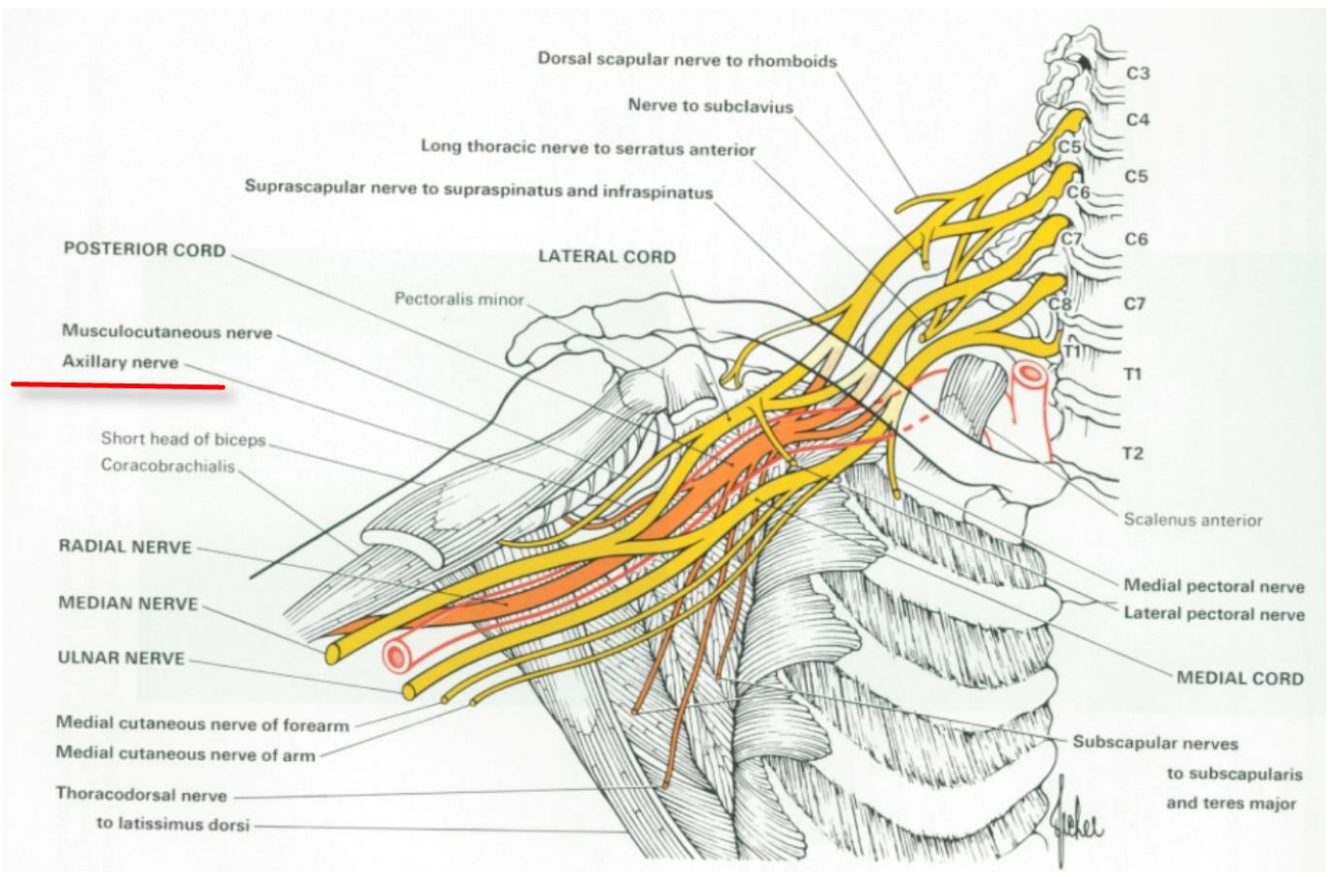

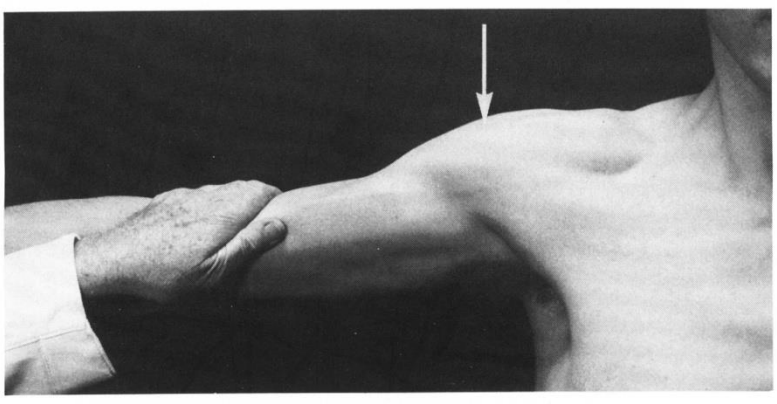

Fig. 16 Deltoid (Axillary nerve; **C5,** C6)
The patient is abducting the upper arm against resistance. *Arrow:* the anterior and middle fibres of the muscle can be seen and felt.

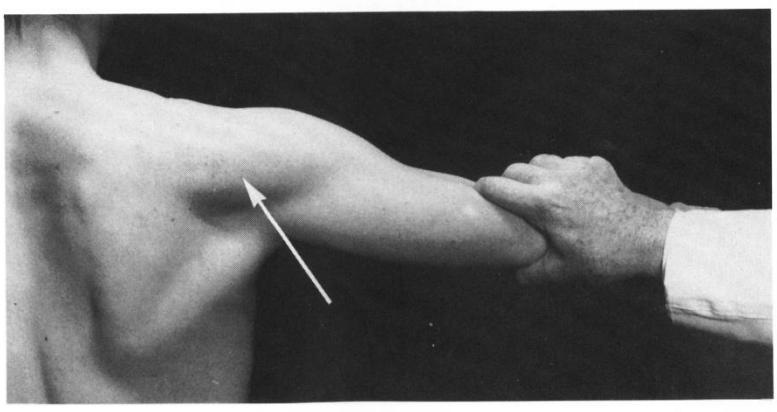

Fig. 17 Deltoid (Axillary nerve; **C5,** C6)
The patient is retracting the abducted upper arm against resistance. *Arrow:* the posterior fibres of deltoid can be seen and felt.

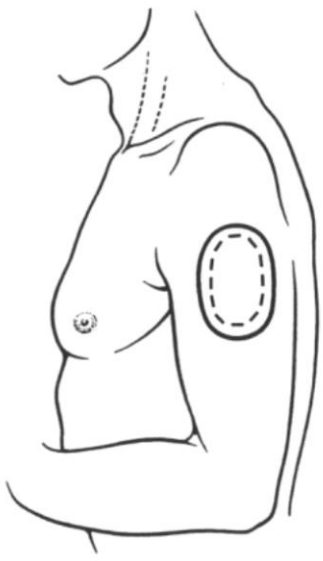

Fig. 70 The approximate area within which sensory changes may be found in lesions of the axillary nerve. Light touch, continuous line; pin-prick, dotted line.

ULNAR NERVE (C7-TH1)

1. Motor – interossei (pirštų lenkimas per pamatinius sąnarius, pirštų išskėtimas ir suglaudimas), nykščio addukcija: see p. PN5 >>
   a) hypothenar, mm. interossei atrofija (nesuima lapo popieriaus tarp ištiestų III ir IV pirštų – *mm. interossei dorsalis III et palmaris III* silpnumas).
      bando tiesti pirštus – bet tiesiasi tik MP ("**grifo ranka**" – neišsitiesia pirštai) - **"claw hand" (main en griffe)** - III-V fingers hyperextended at MCP joints (paralysed *mm. interossei* and *mm. lumbricales ulnares*)*
      * "claw hand" occurs only in lesions at wrist level
      bando gniaužti pirštus – bet lenkiasi tik pirštų galiukai at IP joints ("**grifas gali laikytis už uolos**") - intact m. flexor digitorum profundus

   b) nesuima ištiestais I ir II pirštais lapo popieriaus (nykštį addukuojant prie II piršto) - *m. adductor pollicis* silpnumas.
      FROMENT prehensile thumb sign (signe du journal) - when sheet of paper, grasped between thumb and index finger, is pulled → proximal phalanx of thumb is extended, and distal phalanx is flexed.

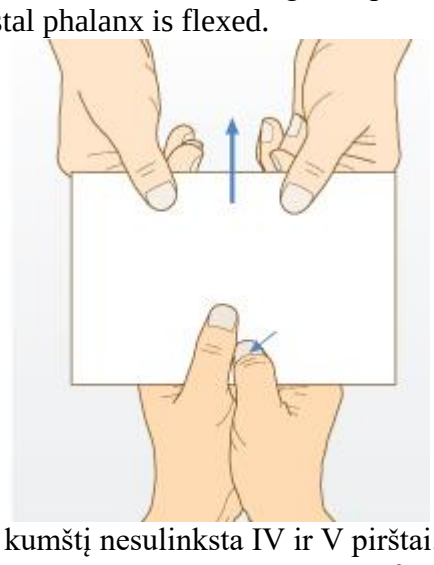

   c) gniaužiant kumštį nesulinksta IV ir V pirštai.
   d) test *interossei*: ask patient to hold sheet of light card between fully extended little and ring fingers:

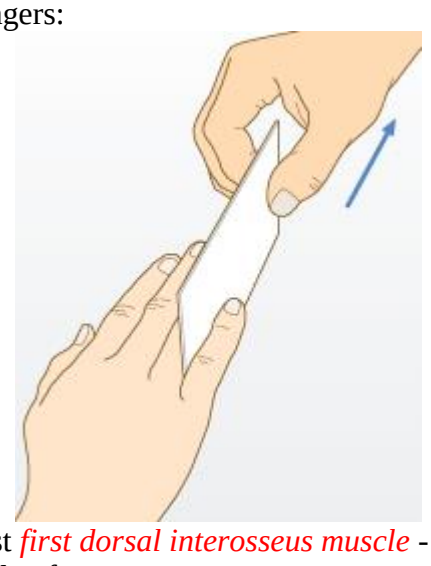

   e) test *first dorsal interosseus muscle* - negali padaryti sprigto; ask patient to abduct extended index finger against resistance:

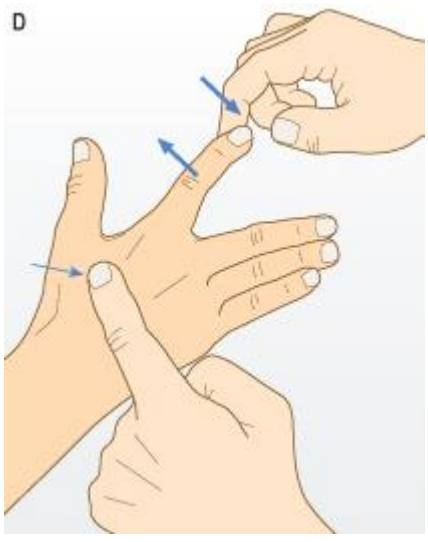

2. Sensory – skriningui testuok **palmar tip of 5th finger**.

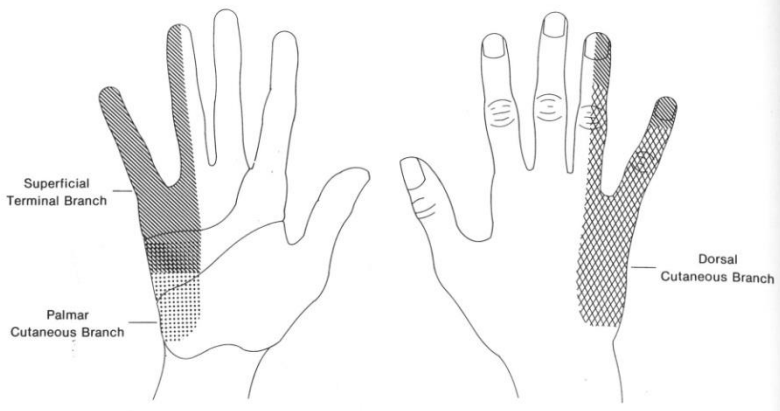

FIG. 10.5. Cutaneous distribution of the three sensory branches of the ulnar nerve. (From Stewart, ref. 12, with permission.)

Proximal Ulnar nerve

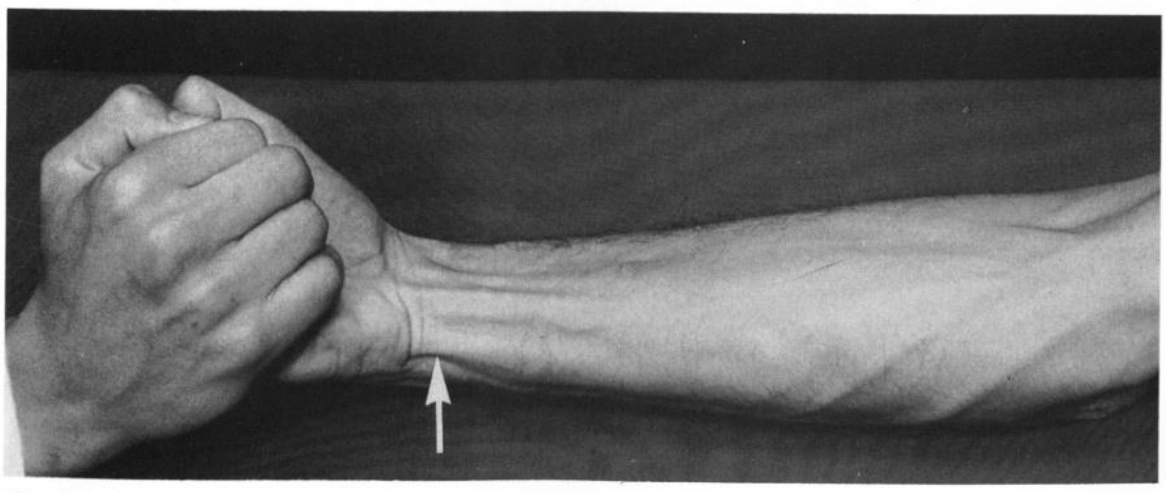

Fig. 38 Flexor Carpi Ulnaris (Ulnar nerve; C7, **C8**, T1)
The patient is flexing and adducting the hand at the wrist against resistance. *Arrow:* the tendon can be seen and felt.

Fig. 39 Flexor Digitorum Profundus III and IV (Ulnar nerve; C7, **C8**)
The patient is flexing the distal interphalangeal joint against resistance while the middle phalanx is fixed.

Distal Ulnar nerve

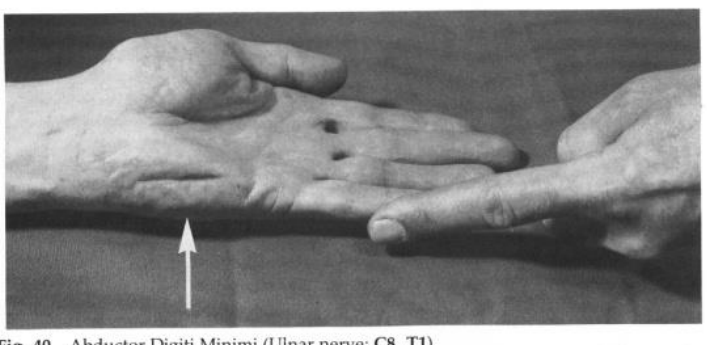

Fig. 40 Abductor Digiti Minimi (Ulnar nerve; **C8, T1**)
The back of the hand and fingers are flat upon the table. The patient is abducting the little finger against resistance. *Arrow:* the muscle belly can be felt and seen.

Fig. 41 Flexor Digiti Minimi (Ulnar nerve; C8, **T1**)
The patient is flexing the little finger at the metacarpophalangeal joint against resistance with the interphalangeal joints held extended.

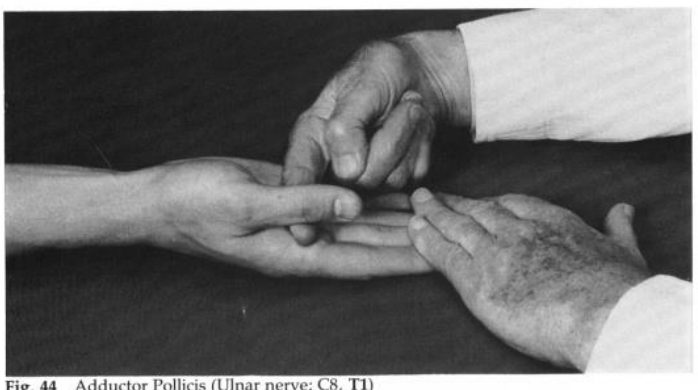

Fig. 44 Adductor Pollicis (Ulnar nerve; C8, **T1**)
The patient is adducting the thumb at right angles to the palm against the resistance of the examiner's finger.

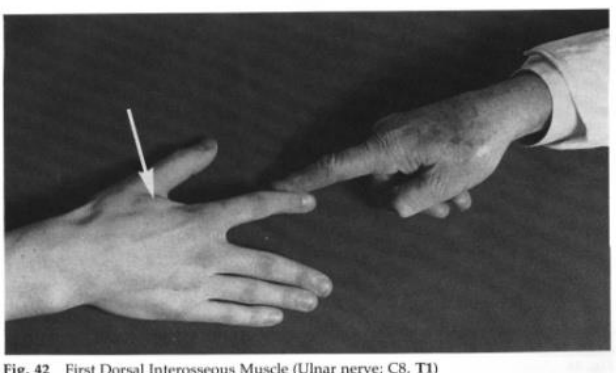

Fig. 42 First Dorsal Interosseous Muscle (Ulnar nerve; C8, **T1**)
The palm and fingers are flat upon a table. The patient is abducting the index finger against resistance. *Arrow:* the muscle belly can be felt and usually seen.

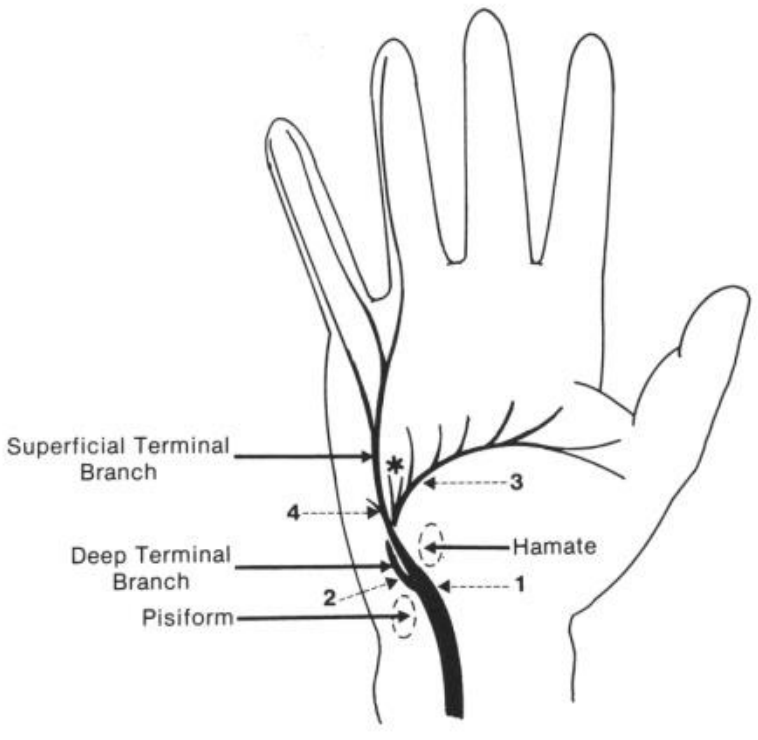

FIG. 10.4. Palmar aspect of the right hand, showing the course and branching of the distal ulnar nerve. The *asterisk* denotes the branches to the hypothenar muscles (abductor, opponens, and flexor digiti minimi muscles). The *numbers* refer to the four main sites of ulnar nerve lesions in the wrist and hand.

MEDIAN NERVE (C6-T1)

1. Sensory (± causalgy) – screen with **palmar tip of 2nd finger**.

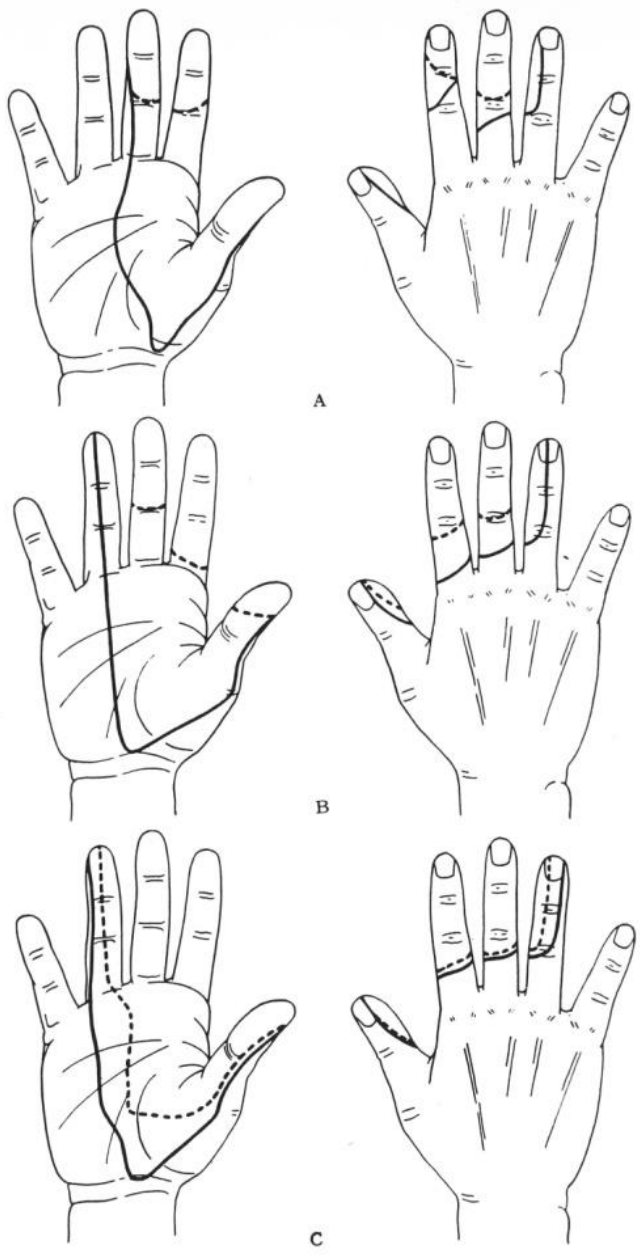

Fig. 75 The approximate areas within which sensory changes may be found in lesions of the median nerve. A = small area, B = average area, and C = large area. Light touch, continuous line; pin-prick, dotted line. Immediately after complete division of the median nerve, the insensitive area on the palm of the hand may be somewhat larger than is shown. (Modified from Head and Sherren (1905) *Brain*, **28**, 116.)

2. Motor - pronacija, I-III pirštų sulenkimas ir pilnas ištiesimas, nykščio opozicija: see p. PN5 >>
   a) thenar atrofija.
   b) **"hand of benediction"**.
   c) nesuima I ir II pirštų galais lapo popieriaus; liepk I ir II pirštais padaryti "O" raidę ir neleisti pratempti siūlo tarp šių pirštų.
   d) gniaužiant kumštį nelinksta I-III.
   e) test abduction: place hand flat, palm up, on table; ask patient to abduct thumb (vertical movement up from palm) and to hold it in that position against resistance:

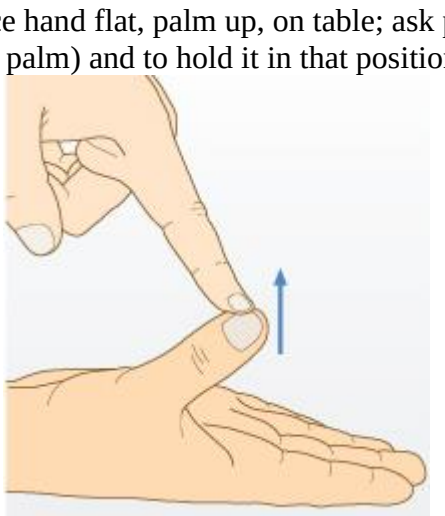

   f) test opposition: ask patient to touch tip of little finger and keep it there against resistance:

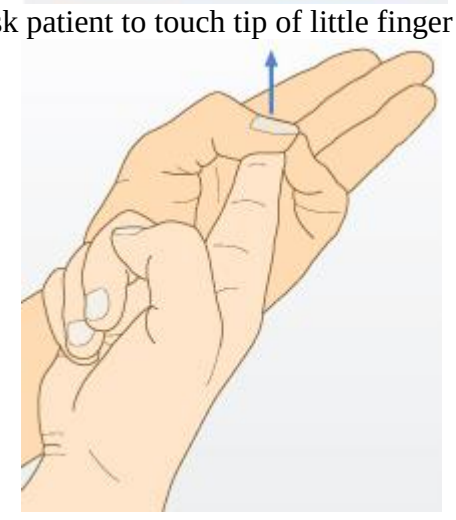

Proximal Median nerve (C6-7)

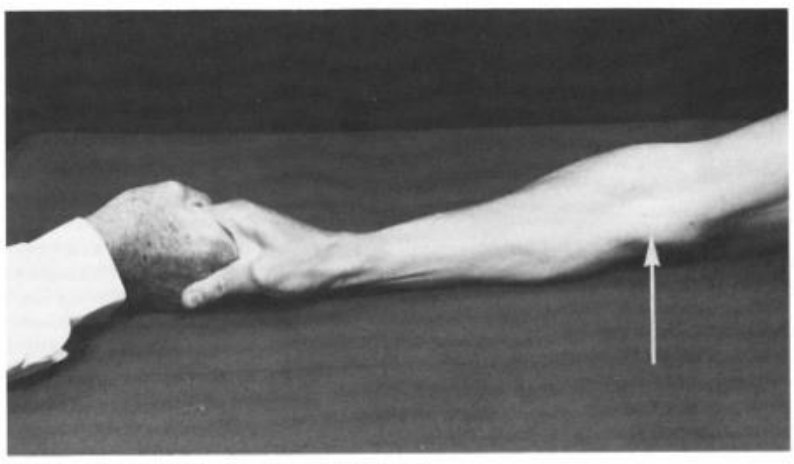

Fig. 28 Pronator Teres (Median nerve; C6, C7)
The patient is pronating the forearm against resistance. *Arrow:* the muscle belly can be felt and sometimes seen.

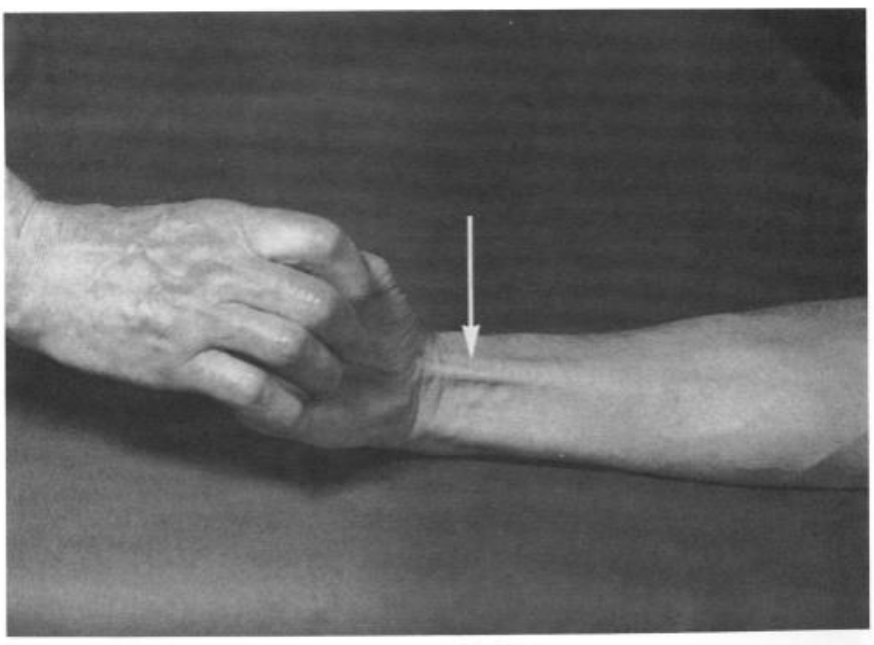

Fig. 29 Flexor Carpi Radialis (Median nerve; C6, C7)
The patient is flexing and abducting the hand at the wrist against resistance.
Arrow: the tendon can be seen and felt.

Fig. 30 Flexor Digitorum Superficialis (Median nerve; C7, **C8,** T1)
The patient is flexing the finger at the proximal interphalangeal joint against resistance with the proximal phalanx fixed. This test does not eliminate the possibility of flexion at the proximal interphalangeal joint being produced by flexor digitorum profundus.

Anterior Interosseus branch (C7-8)

Fig. 31 Flexor Digitorum Profundus I and II (Anterior interosseous nerve; C7, **C8**)
The patient is flexing the distal phalanx of the index finger against resistance with the middle phalanx fixed.

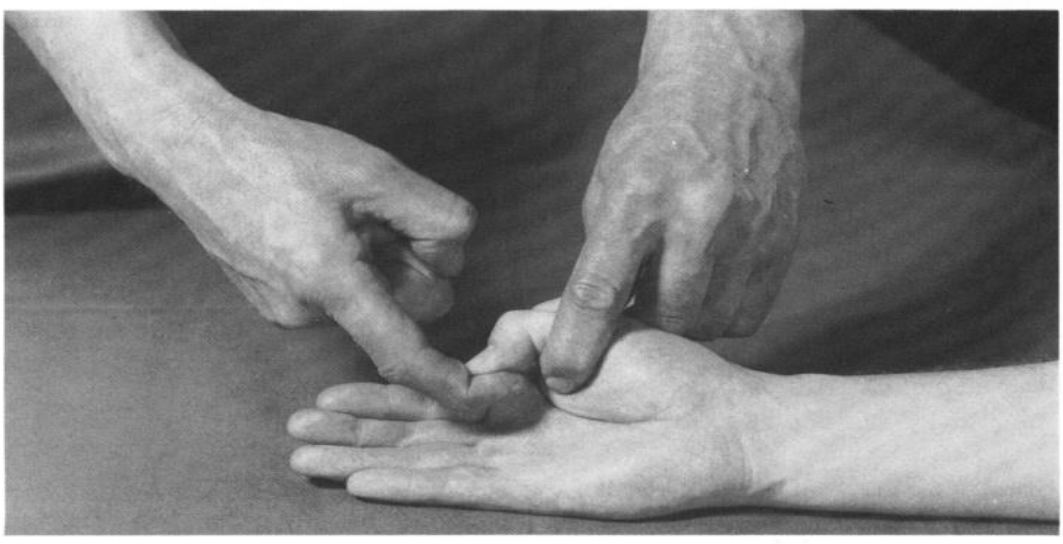

Fig. 32 Flexor Pollicis Longus (Anterior interosseous nerve; C7, **C8**)
The patient is flexing the distal phalanx of the thumb against resistance while the proximal phalanx is fixed.

Distal Median nerve (C8-T1)

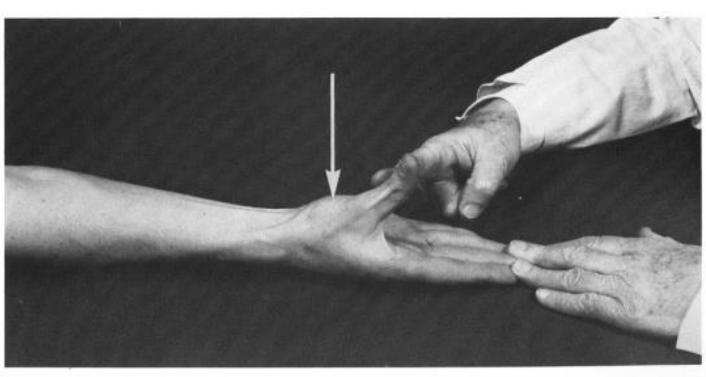

Fig. 33 Abductor Pollicis Brevis (Median nerve; C8, **T1**)
The patient is abducting the thumb at right angles to the palm against resistance.

Fig. 34 Opponens Pollicis (Median nerve; C8, **T1**)
The patient is touching the base of the little finger with the thumb against resistance.

Fig. 35 1st Lumbrical-Interosseous Muscle (Median and ulnar nerves; C8, **T1**)
The patient is extending the finger at the proximal interphalangeal joint against resistance with the metacarpophalangeal joint hyperextended and fixed.

RADIAL NERVE (C6-8)

1. Sensory (no pain) – screen with **dorsal aspect of skin web between 1st and 2nd fingers**.

Fig. 71 The approximate area within which sensory changes may be found in high lesions of the radial nerve (above the origin of the posterior cutaneous nerves of the arm and forearm). The average area is usually considerably smaller, and absence of sensory changes has been recorded.

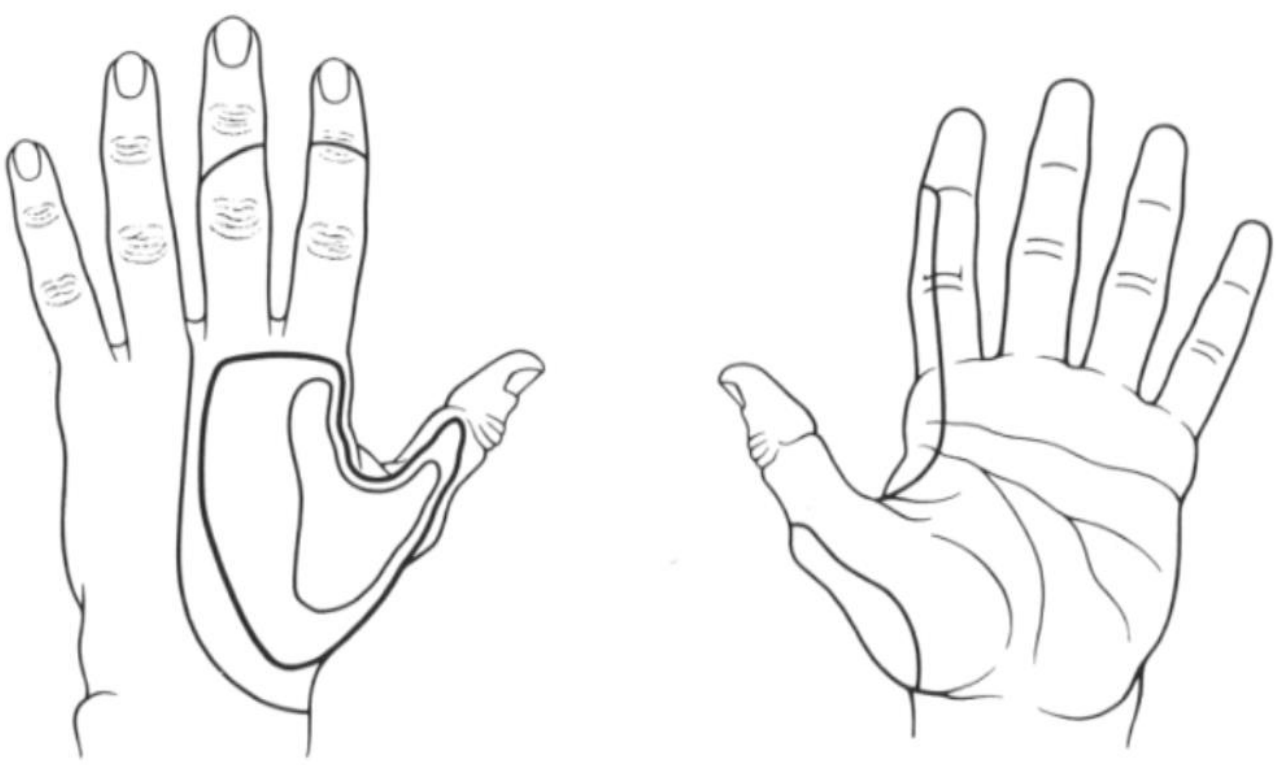

Fig. 72 The approximate area within which sensory changes may be found in lesions of the radial nerve above the elbow joint and below the origin of the posterior cutaneous nerve of the forearm. (The distribution of the superficial terminal branch of the radial nerve.) Heavy line, average area; light lines, small and large areas.

2. Motor – extension in all arm joints, supination: see p. PN5 >>
   a) **"wrist drop"**
   b) triceps reflex↓
   c) triceps strength↓

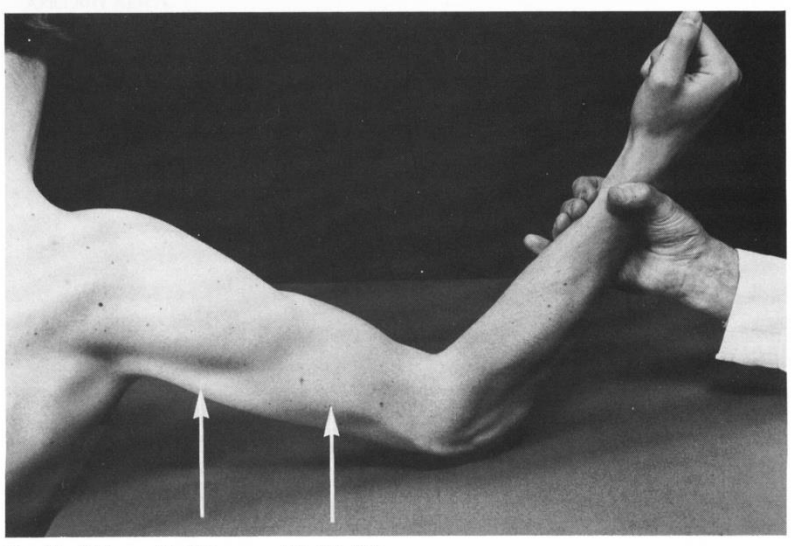

Fig. 18 Triceps (Radial nerve; C6, **C7**, C8)
The patient is extending the forearm at the elbow against resistance. The elbow is supported on a table. *Arrows:* the long and lateral heads of the muscle can be seen and felt.

   d) ask to flex elbow to 90° and pronate wrist; support wrist with your hand and ask patient to extend fingers and then extend wrist (when assessing finger extension watch MCP joints as extension of IP joints can also be produced by interossei and lumbrical muscles supplied by median and ulnar nerves):

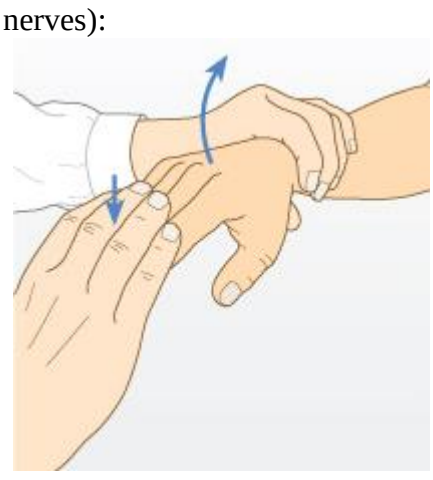

   e) brachioradialis↓

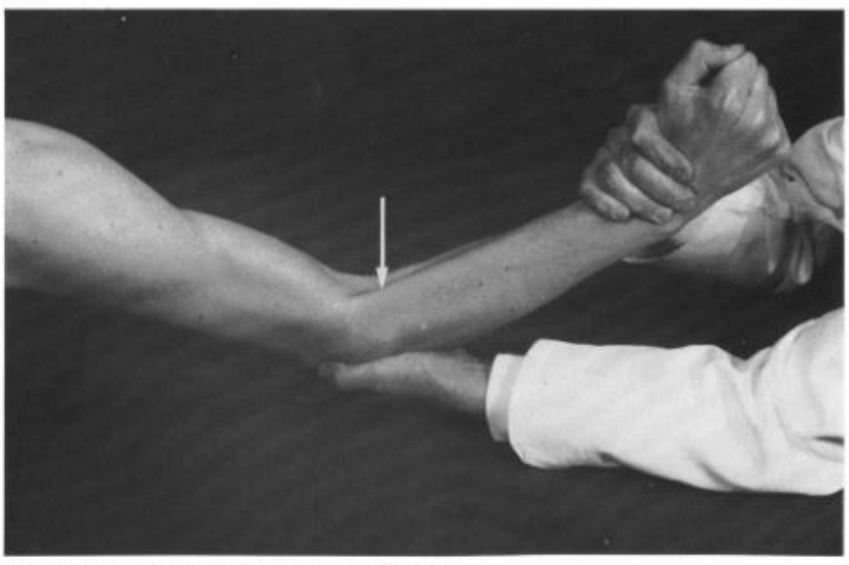

Fig. 19 Brachioradialis (Radial nerve; C5, **C6**)
The patient is flexing the forearm against resistance with the forearm midway between pronation and supination. *Arrow:* the muscle belly can be seen and felt.

f) supination↓

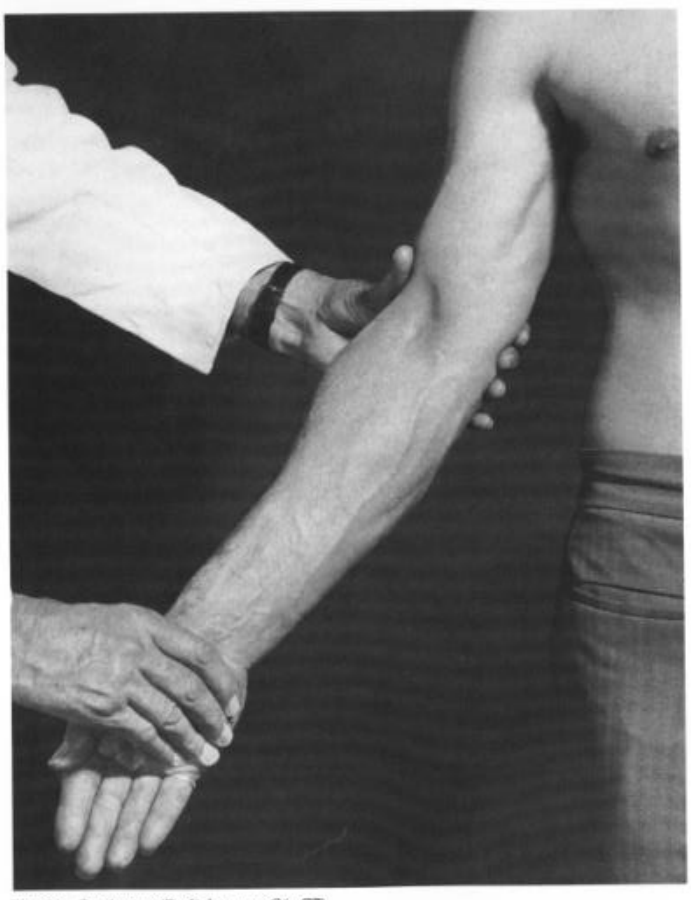

Fig. 21 Supinator (Radial nerve; C6, C7)
The patient is supinating the forearm against resistance with the forearm extended at the elbow.

g) extensor carpi radialis↓

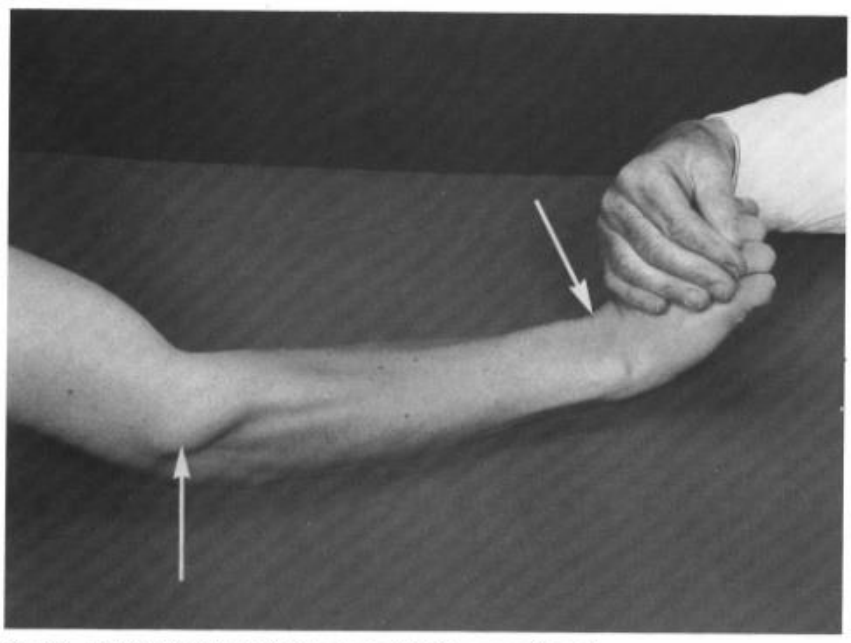

Fig. 20 Extensor Carpi Radialis Longus (Radial nerve; C5, **C6**)
The patient is extending and abducting the hand at the wrist against resistance.
Arrows: the muscle belly and tendon can be felt and usually seen.

<u>Posterior interosseus branch</u>

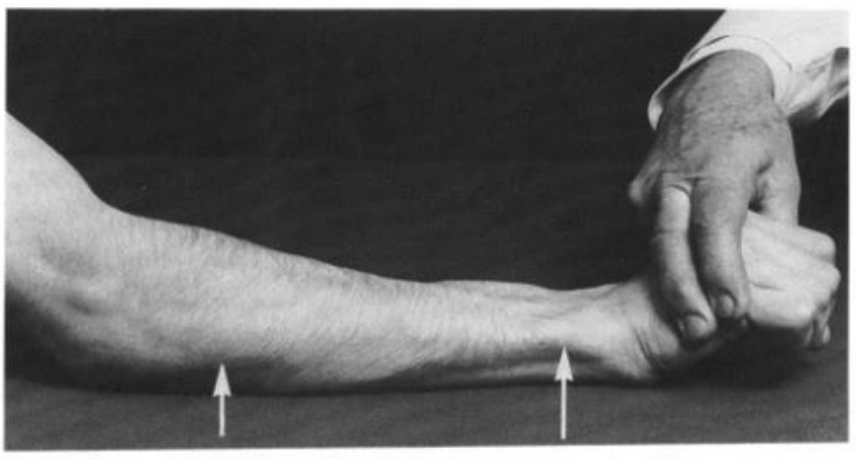

Fig. 22 Extensor Carpi Ulnaris (Posterior interosseous nerve; **C7**, C8)
The patient is extending and adducting the hand at the wrist against resistance.
Arrows: the muscle belly and the tendon can be seen and felt.

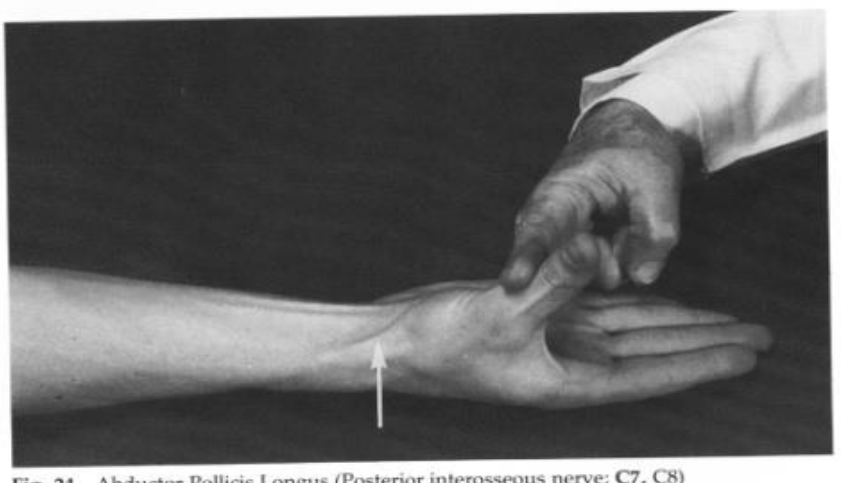

Fig. 24 Abductor Pollicis Longus (Posterior interosseous nerve; **C7**, C8)
The patient is abducting the thumb at the carpo-metacarpal joint in a plane at right angles to the palm. *Arrow:* the tendon can be seen and felt anterior and closely adjacent to the tendon of extensor pollicis brevis (**cf.** Fig. 26).

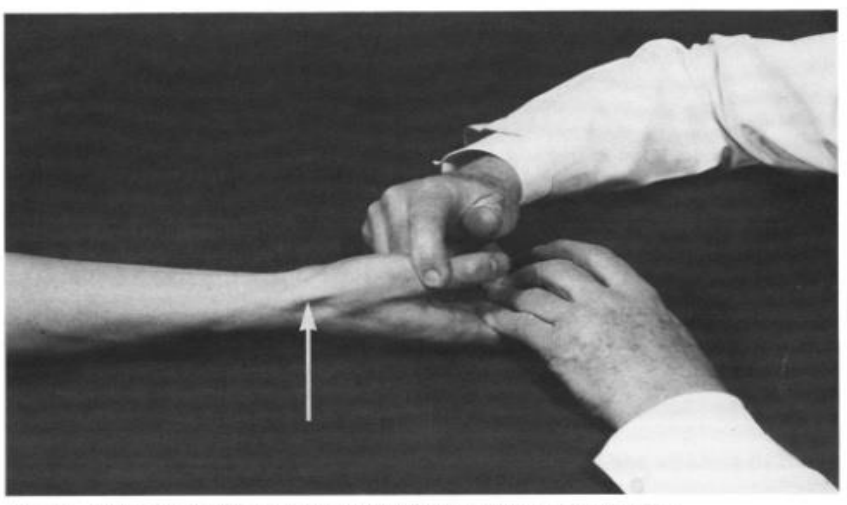

Fig. 26 Extensor Pollicis Brevis (Posterior interosseous nerve; **C7**, C8)
The patient is extending the thumb at the metacarpophalangeal joint against resistance.
Arrow: the tendon can be seen and felt (**cf.** Fig. 24).

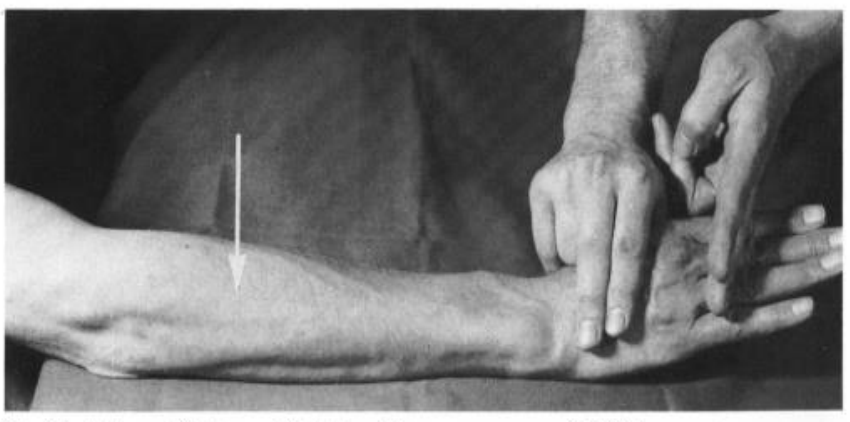

Fig. 23 Extensor Digitorum (Posterior interosseous nerve; **C7**, C8)
The patient's hand is firmly supported by the examiner's right hand. Extension at the metacarpophalangeal joints is maintained against the resistance of the fingers of the examiner's left hand. *Arrow:* the muscle belly can be seen and felt.

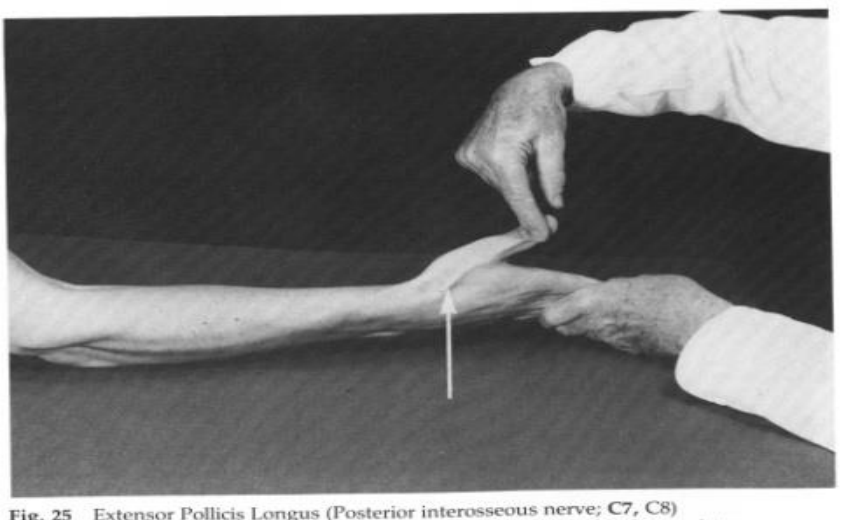

Fig. 25 Extensor Pollicis Longus (Posterior interosseous nerve; **C7**, C8)
The patient is extending the thumb at the interphalangeal joint against resistance.
Arrow: the tendon can be seen and felt.

LUMBOSACRAL PLEXUS

Quickest screening for lumbosacral radiculopathy:

knee-jerk (L4)
great toe dorsiflexion (L5)
ankle-jerk (S1)

N. ISCHIADICUS

L_5 & S_1 root stretch tests – jei yra L_5 ar S_1 *root compression*, atsiranda SCIATICA:

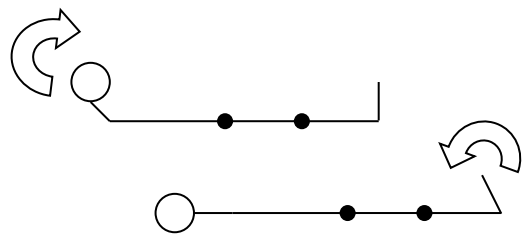

1) **NÉRI** (normoje diskomfortas sprande)

2) **SICARD** (normoje diskomfortas blauzdos užpakalyje, pakinklyje)

3) **LASÈGUE sign, s. straight-leg raising test** – lift foot to flex hip passively with knee kept straight - ask where discomfort is (normoje diskomfortas šlaunies fleksoriuose - hamstring tightness; in nerve compression burning pain goes in to foot);

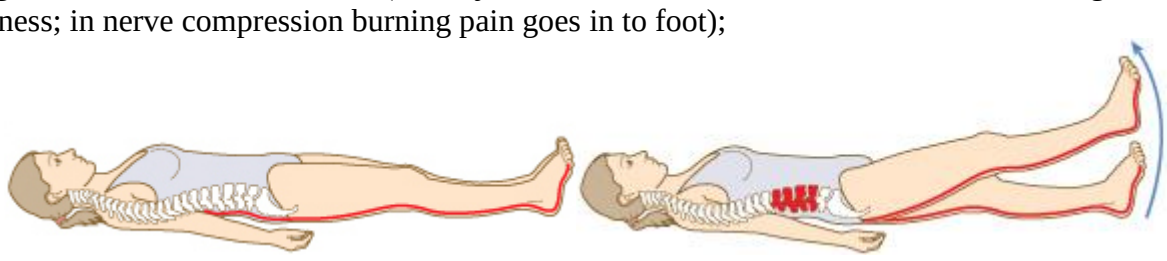

- if pain is not present at 70-80° of straight leg raising, dorsiflex foot to elicit pain (this maneuver stretches sciatic nerve).

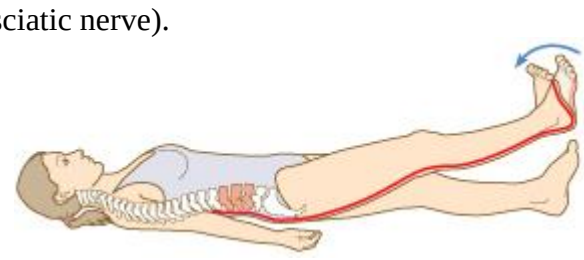

- ar pacientas nesimuliuoja (functional overlay) - **distracting (s. flip) test**: patient sitting on examination table, examine knee reflexes, and then extend knee, as if to examine ankle jerk (if patients have root compression, they will lean back and grimace to relieve discomfort):

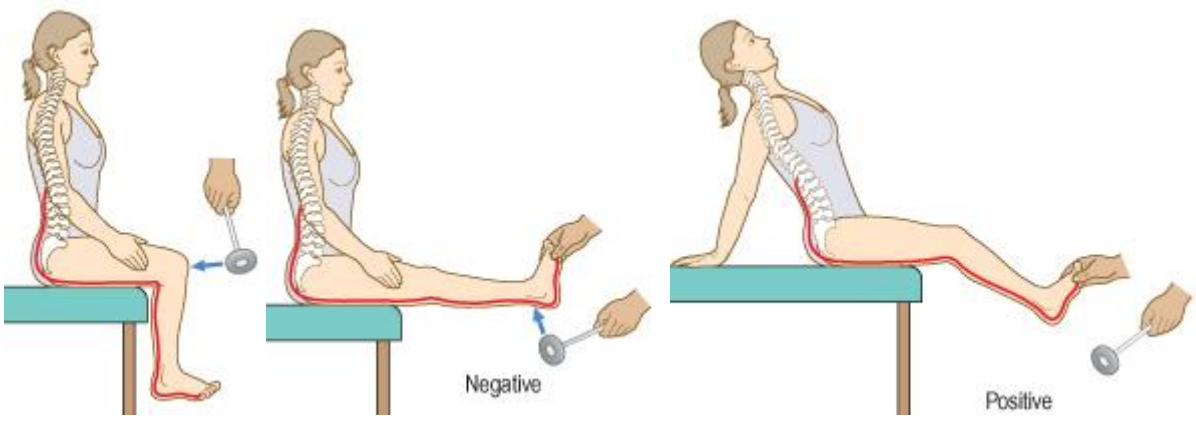

4) **Crossed Lasègue (Bechterew) sign** - atliekant sveikos pusės Lasègue, kitoje pusėje atsiranda SCIATICA.

5) **KROLIO** - sėdantis, susilenkia keliai.

6) diagnostiniai provokaciniai testai (*PIRIFORMIS SYNDROME* diagnostikai):
   – **FREIBERG maneuver**: forceful internal rotation of extended thigh.
   – **PACE maneuver**: abduction of thigh in sitting patient.
   – **BEATTY maneuver**: patient lies on unaffected side, affected leg is placed behind unaffected leg with bent knee on table → rise knee.
   – **MIRKIN test**: patient stands with knee straight → patient slowly bends forward and examiner presses piriformis.

Motor - knee flexors + all muscles bellow knee.

Sensory

Skausmingi **Valė taškai** - plica glutealis viduryje, fossa poplitea, capitulum fibulae užpakalyje, malleolus lateralis.

N. FEMORALIS

L_{2-4} root stretch tests – positive if skauda kirkšnį, šlaunies priekį:

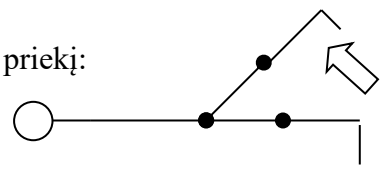

1. **Reverse straight-leg raising (WASSERMANN) test**:

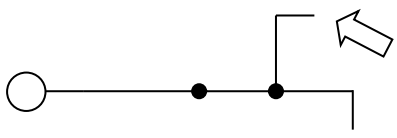

2. **STRÜMPELL- MACKEVIČIAUS**:

3. **COMBINATION** - patient lying prone flex knee and then extend hip:

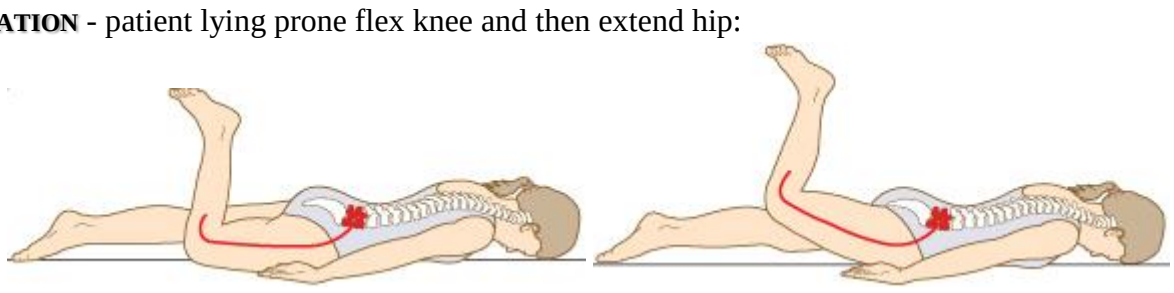

Motor - lenkimas per klubą, tiesimas per kelį:
   a) sunku lipti laiptais ar į kalną
   b) patellar reflex↓
   c) einant meta koją į priekį

- when patient stands erect, leg is held stiffly extended by contraction of tensor fasciae femoris and gracilis; walking on level ground is possible as long as leg can be kept extended, but if slightest flexion occurs, patient sinks down on suddenly flexed knee.

N. TIBIALIS

1. Tibial nerve stretch test: flex hip to 90° → extend knee - in this position the tibial nerve 'bowstrings' across popliteal fossa → press over either of hamstring tendons, and then over nerve in middle of fossa; test is positive if pain occurs when nerve is pressed, but not hamstring tendons:

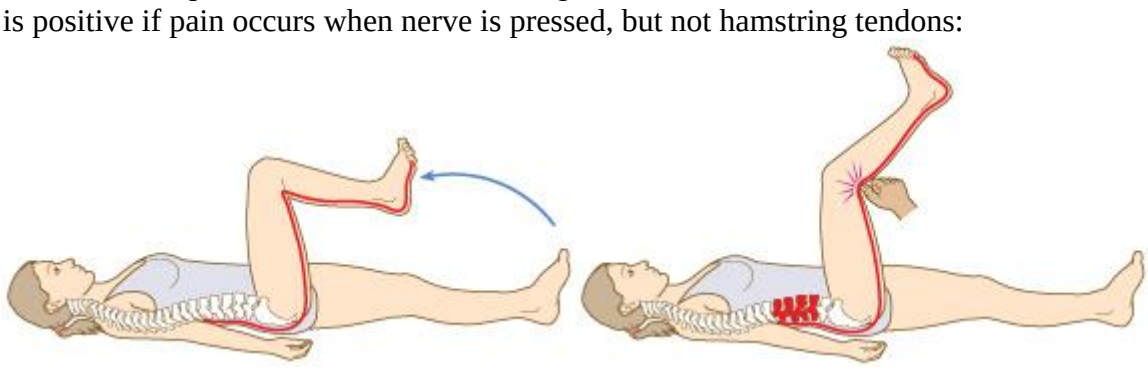

2. Motor - pėdos ir pirštų lenkimas, pėdos sukimas į vidų:
   a) nepasistiebia ant pirštų
   b) Achilo reflex↓
   c) pes valgus

3. Sensory - blauzdos posteromedialinis ir apatinis, pėdos dorsolateralinis ir plantarinis paviršiai.

N. PERONEUS

1. Motor - pėdos ir pirštų ekstenzija, pėdos sukimas į išorę (eversija/abdukcija):
   a) "foot slap" - "steppage gait" (pes equinovarus)
   b) nepastovi ant kulnų

2. Sensory – blauzdos anterolateralinis, pėdos dorsomedialinis paviršiai.

MENTAL STATUS EXAMINATION (MSE)

As quick screen - ask patient to draw clock with hands at set time (e.g. 10 min before 2:00) - very informative regarding cognitive status, visuospatial deficits, ability to comprehend and execute instructions in logical sequence, and presence or absence of perseveration.

Any suspicion of cognitive decline → always perform complete **MINI-MENTAL STATUS EXAMINATION**! see p. D2 >> or p. D3 >>

N.B. Mini-Mental Status examinations exclude questions concerning mood, abnormal mental experiences, form of thinking.

More complete examination is **NEUROPSYCHOLOGICAL TESTING**. see p. D12 >>

- make patient **physically comfortable** and (if possible) **mentally at ease**; otherwise, obtained information may reflect artifacts of interaction.
- special introduction - "I have listened to your lungs and heart. To study how your brain is working, I have a series of questions that I ask of every patient" - it ***obviates any patient's fear*** that he has been singled out for test because something is amiss.
- avoid saying, "some of these questions are very easy" (if individual cannot answer them, he may feel truly inadequate).
- paprašyti artimųjų, draugų, slaugytojų palyginti dabartinį statusą su ankstesniais.
- pirmiausia ištiriama eilės tvarka:
  1. **Level of consciousness**
  2. **Primary sensory systems** (visual, auditory, tactile, proprioceptive)
  3. **Effector systems** (basic motor, vocal, praxis).
  4. **Attention & vigilance**
  5. **Orientation**
  6. **Language**

  – jei šios funkcijos sutrikę, tolimesnis mental status tyrimas bus netikslus!

1. CONSCIOUSNESS

a) **alert** - awake, aware, interacting, responsive to stimuli.
b) **lethargic, obtunded** - can be roused but does not maintain arousal.
c) **stuporous** - can be roused slightly with intense stimulation.
d) **comatose** - cannot be roused, even with painful stimuli.
e) ***fluctuating*** mental state (varies during day course).

Examination → see p. S30 >>

2. ATTENTION & VIGILANCE

1) **observing** if patient is ***task oriented*** while taking history and conducting examination ("distracted" patient - attention shifts from one stimulus to another).

2) **DIGIT SPAN (forward and reversed) test** - measures attention of < 10-second duration.

37
416
5318
26593
614783
9362514

- examiner should intone numbers, without inflection, at rate of one number per second.
- numbers should be read from prepared list to ensure smooth delivery.
- ability to ***reverse*** digits requires more concentration than forward repetition.
- if this test is repeated to evaluate clinical progress, numbers should be changed daily.

Normal score:
for ADULTS 5-7 digits forward and 5 digits reversed.
for ELDERLY 5 digits forward and 3-4 digits reversed.

3) **CPT (continuous performance testing)** - measures vigilance (concentration) of ≈ 1-minute duration.

LPTEAAICT
DALAANIAB
FSAMRCOAD
PAKLAYJYO
EABAAEFMU
SAHEVARAT

- examiner reads letters aloud, with uninflected and monotonous delivery, at rate of one letter per second.
- patient is asked to ***tap with finger*** (or pencil) whenever "A" is read aloud from list of letters.
- normal adult usually makes no errors on this test.

3. ORIENTATION

1. **Orientation to time**: "What is today's date?" "Month?" "Day of the week?" "Year?".
2. **Orientation to place**: "Where are you now?" "What state are you in?" "County?" "City?" "What is the name of this place?".
3. **Orientation to person**: "What is your name?", "Names of relatives and professional personnel", identify which finger has been stimulated by examiner under visual guidance, and in absence of visual input (***Finger Localization Test***).
   N.B. loss of orientation to person as isolated symptom suggests malingering!

"A & O x 3" = alert and oriented to time, place, and person

4. LANGUAGE

Ask for HANDEDNESS! (which hand patient uses to write, eat, and throw a ball)

Six main parts of language examination:

1) ***SPONTANEOUS*** speech (fluent/nonfluent); e.g. words per minute (in English, normal is 50-150), phrase length (≥ 4 words per phrase).
   fluent - lesion is *posterior*;
   nonfluent - lesion is *anterior*.

2) auditory ***COMPREHENSION***:
   a) ***conversation*** - ordinary conversation probes patient's ability to understand questions;
   b) ***commands*** - series of single or multistep commands;
   c) ***yes and no answers*** (e.g. "are the lights on in this room?");
   d) ***pointing*** - ask to point to window, door, and ceiling in specific sequence; requires limited motor response (interference with apraxia).

   N.B. don't give nonverbal clues!

3) ***REPEATING*** words, phrases – ask patient to repeat "no if's, and's, or but's" and other grammatically intricate sentences - listen for word substitutions [verbal paraphasias], phonemic substitutions [literal paraphasias], and neologisms [new word formation].

4) ***NAMING, word list generation***:
   a) ask to name objects, body parts, colors, geometrical figures.
   b) ask to generate list of as many animals as possible in minute (normal subjects can list 18 ± 6 animals per minute without cueing).
   c) automatizuota kalba - suskaičiuoti iki 10.

5) ***READING aloud*** and for ***comprehension*** (ask fifth-grade level questions from text); sample text:

> *The helicopter is a most unusual aircraft. It can rise straight up, descend straight down, fly forward, or fly backward. It can also fly very slowly and even remain in one place while in midair. These special flying features of the helicopter make it valuable in search and rescue missions because it has the ability to take off and land in a small amount of space.*

6) ***WRITING*** to ***dictation***, to ***command*** (e.g. "describe your job"), ***copying***.
   If patient can *read and write* with no errors, aphasia is not present! (may be mute!)

Quick screen:
1. Listen to **spontaneous speech** – fluency, appropriateness of content, incorrect words (*paraphasias*), nonsense words (*neologisms*).
2. Show common object (e.g. coin or pen) and ask its **name**.
3. Give simple three-stage command for **comprehension** (e.g. "Pick up piece of paper, fold it in half and place it under the book"); it is essential to give no visual clues (best to give instruction from behind patient's head).
4. Ask patient to **repeat** simple sentence (e.g. "Today is Tuesday").
5. Ask patient to **read** passage from newspaper.
6. Ask patient to **write** sentence.

Papildomai stebima:

PROSODY (kalbos melodija, emociniai atspalviai)

ASSOCIATED SIGNS (visual field defects, hemisensory, hemimotor loss, praxis, memory)

APHASIA	Verbal output	Compre-hension	Repetition	Naming	Reading aloud / comprehension	Associated signs
Broca	**nonfluent**	normal	impaired	marginally impaired	poor / good	RHP (esp. lower face)
Wernicke	fluent (paraphasic)	**impaired**	impaired	impaired	poor / poor	± RHH
Conduction	fluent (paraphasic)	normal	**impaired**	impaired (paraphasic)	poor / good	± RHS
Global	**nonfluent**	**impaired**	**impaired**	**impaired**	poor / poor	RHP, RHS, RHH
Anomic	fluent	normal	normal	**impaired**	variable	-
Transcortical:						
MOTOR	nonfluent	normal	**normal**	impaired	poor / good	RHP
SENSORY	fluent	impaired	**normal**	impaired	poor / poor	± RHH
MIXED	nonfluent	impaired	**normal**	impaired	poor / poor	RHP, RHS

RHP – right hemiparesis
RHS – right hemisensory deficit
RHH – right homonymous hemianopia

5. MEMORY

> first goal is to ascertain that memory impairment is not **secondary** to specific perceptual, motor, cognitive disability or broad impairment of mental status – todėl prieš tai būtinai ištiriama ***sensory & motor systems, attention, vigilance***.

a) **IMMEDIATE memory** (S. **WORKING memory, ATTENTION**) – žr. *DIGIT SPAN TEST* (attention testing).

b) **LONG-TERM memory** (S. **RECENT memory, SHORT-TERM memory** in standard neurological usage, **LEARNING**)

   1) remember and later recall (e.g. after 3-5 minutes) **4 words** that are diverse semantically and phonetically (e.g. shovel, yellow, anger, sofa).
      - warn patient that memory will be tested for information.
      - have patient *immediately repeat* words or name objects - to rule out attentional, perceptual, and linguistic bases for any later memory failure.
      - delay must be filled with activity (e.g. counting); otherwise, patient may quietly rehearse words!
      - normal ADULT recalls all 4 words; recall of 3 words is normal in ELDERLY; recall ≤ 2 words suggests **ANTEROGRADE AMNESIA**.

   2) ask for **events of the day** – make sure that you can check answers against other sources (distinguish confabulations): today's weather, today's appointment time in clinic, medications & laboratory tests taken during day.

c) **REMOTE memory** (S. **LONG-TERM memory** in standard neurological usage, **INTELLIGENCE**) – ask patients to recall:
   1) details of own medical history
   2) past personal facts (birthdays, anniversaries, names of schools attended, jobs held)
   3) historical facts (e.g. names of the last six presidents or wars).
   - evaluates possibility of **RETROGRADE AMNESIA**.

6. PRAXIS

- examine both *right* and *left* arms; when one arm is weak (or has another motor disorder), nonparetic limb should be tested.
- **same items** should be used for all subtests (e.g. nail, screwdriver, and hammer).
- use commands requiring to cross patient's midline (e.g. su dešine ranka paliesti kairę ausį).
- notice whether patient can ***discriminate between well and poorly performed tests***.

1. **IMITATION test** - ask to imitate examiner performing gestures.

2. **PANTOMIME-TO-COMMAND test** - request to pantomime to verbal command:
   1) **transitive gestures** (i.e. using tool and instrument), e.g. "Show me how you would use bread knife to cut slice of bread"
      N.B. instruct patient not to use body part as tool but instead pantomime tool use.
   2) **intransitive gestures** (i.e. communicative gestures such as waving good-bye)
   3) perform task that requires ***several sequential motor acts*** (e.g. making a sandwich)

3. Allow patient to see and hold *actual tools / objects* and **ask to demonstrate how to use tool / object**.

4. Whether patient can **match tools with objects** on which they operate (e.g. given partially driven nail, will he select hammer?).

5. Whether patient can **develop tools to solve mechanical problems**.

   Ask patient to put on pyjama top or dressing gown, one sleeve of which has been pulled inside out.

7. CONSTRUCTIONAL (GRAPHOMOTOR) ABILITY

- ability to ***copy / draw 2- or 3-dimensional shapes***:

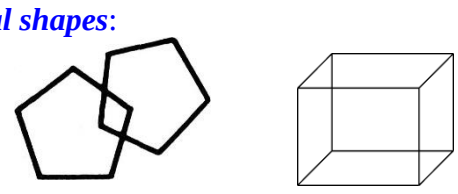

- patient must copy on blank unlined paper sheet.
- excellent screening test - involves visual, perceptual, analytic, motor functions.

8. FUND OF INFORMATION / VOCABULARY

Evaluation - bright, average, dull, overtly retarded, demented.

N.B. always consider patient's cultural and educational background!

I. Patient is asked questions that assess his **store of knowledge or general information.**

How many minutes are in an hour?
What is the function of the kidneys?
What we do celebrate on the 4th of July?
What is the capital of Greece?
What is hieroglyphic?
How many miles lie between San Francisco and New York?
Who wrote "Paradise Lost?"

II. **Vocabulary** (best indicator of intelligence!) - ask patient to give meaning of following words (or to use each word in sentence):

Apple [obuolys]	Microscope [mikroskopas]
Donkey [asilas]	Stanza [posmas, strofa]
Diamond [deimantas]	Guillotine [giljotina]
Nuisance [nemalonumas]	Plural [daugiskaita]
Join [susijungti]	Seclude [atskirti, izoliuoti]
Fur [kailis]	Spangle [blizgutis, blizgalas]
Shilling [šilingas]	Recede [atsitraukti]
Bacon [puskiaulio mėsa]	Affliction [sielvartas]
Tint [atspalvis]	Chattel [kilnojamasis turtas]
Armory [heraldika]	Dilatory [delsiantis]
Fable [pasakėčia, mitas]	Flout [nepaisymas]
Nitroglycerine [nitroglicerinas]	Amanuensis [sekretorius *(rašantis diktuojamą tekstą)*]

- average intelligence – must define 8-16 words.

9. CALCULATIONS

- ability to perform mental arithmetic (e.g. **SERIAL SEVENS** - ask patient to begin with 100 and count backward by 7; stop after five subtractions (93, 86, 79, 72, 65).

- if patient cannot complete serial 7s, try **serial 3s**, or just **counting backwards** (in this case, any error is failure).
- performance is highly correlated with concentration, intelligence, and education.

10. ABSTRACT THINKING

1. **Similarities** - patient is asked to identify ***essential relation between word pairs*** (e.g. turnip and cauliflower, chair and table, painting and symphony).

2. **Comprehension, s. proverb interpretation** (depends on cultural, intellectual, and educational background!) - ask patient to ***explain proverbs***:

   "Rome was not built in a day";
   "A bird in the hand is worth two in the bush";
   "Birds of a feather flock together";
   "A rolling stone gathers no moss";
   "An apple falls near its tree."

   - **bad score** – for *concrete* response (e.g. it took a long time to build Rome);
     intermediate score – for *partial abstract* response (e.g. don't do things too fast);
     best score – for *most abstract* response (e.g. it takes time to do things well).

11. CONCEPTUAL ABILITY

- patient is asked to ***complete series of letter and number sequences*** that are printed on card:

(a)	A C E G _____	(I)
(b)	1 4 7 10 _____	(13)
(c)	AZ BY CX D _____	(W)
(d)	Hydrangea	763047168
	Jewel	49823
	Hat	_____ (any three-digit numeral)

12. JUDGMENT

- patient's understanding of ***what he has done or will do in various situations***.
- possible questions include:

  "What would you do if you:
  smelled smoke in your apartment?"
  saw a fire coming out from a paper basket?"
  found a self addressed envelop on the street"
  had severe chest pain while you were alone at home?"
  saw a 2-year-old child playing at the end of a pier?"

13. INSIGHT (NOSOGNOSIA)

- patient's ***awareness of significance of her symptoms and illness***:
  1) understanding degree of illness
  2) understanding need for help, hospitalization, agree to management plan

- if conversation with patient suggests that there may be problem with insight, patient is asked whether anything is wrong with his / her health.

14. GENERAL BEHAVIOR AND APPEARANCE

1. Is patient **clothing & grooming** appropriate?
2. **Psychomotor activity, facial expression, position, gait**: normal, agitated, hyperactive, hypoactive, repetitive acts, tics.
3. **Interview behavior**: hostile, angry outbursts, cooperative, evasive, impulsive, irritable, passive, apathetic, withdrawn, silly, helpless, unconcerned, euphoric, demanding, negativistic.

15. THOUGHT

Thought "PROCESS" (s. FORM of though, MECHANICS of thinking) for definitions → see p. Psy5 >>

1. **Reduced content**, incomplete sentences
2. **Circumstantiality**
3. **Tangentiality**
4. **Derailment**
5. **Clang associations**
6. **Blocking**
7. **Flight of ideas**
8. **Confabulation**
9. **Echolalia**, **perseveration**, **verbigeration**.
10. **Word salad**, **neologisms**

Thought CONTENT - ask open-ended question, such as, "What's on your mind?".

for definitions – see p. Psy5 >>

1. **Perception disorders**:
   1) illusions
   2) hallucinations
   3) depersonalization, derealization.
2. **Delusions**

   N.B. delusions are fixed – cannot be corrected by physician – physician should not pretend to agree with delusion but should ***take neutral position*** (contradiction to patient's delusional belief may cause patient to become angry and stop interview!).
3. **Homicidal** thoughts & plans
4. **Suicidal** thoughts & plans
5. Feelings of hopelessness, worthlessness, guilt, anhedonia
6. Obsessions
7. Phobias
8. Sexual concerns
9. Somatic preoccupations
10. Religiosity

16. EMOTIONAL STATE

Ask - "How are your spirits?"

1. **Mood / affect** – angry, sad, apathetic (flat affect), fluctuating (labile), happy, fearful, anxious.
2. ***Are mood and affect the same***?
3. ***Is mood / affect appropriate to verbal content, topics of discussion***?

In suspected DEPRESSION – ask as far as patient's positive answers warrant:

"Do you get pretty discouraged (or depressed or blue)?"
"How low do you feel?"
"What do you see for yourself in the future?"
"Do you ever feel that life isn't worth living? Or that you had just as soon be dead?"
"Have you ever thought of doing away with yourself?"
"How did (do) you think you would do it?"
"What would happen after you were dead?"

BIBLIOGRAPHY for ch. "Diagnostics" → follow this LINK >>