

# Brain Biopsy

Last updated: June 3, 2019

**TISSUE PROCESSING TECHNIQUES** ..... 1  
**FINDINGS** ..... 2  
 Inclusions, Bodies ..... 2  
**SURGICAL TECHNIQUE, PERIOPERATIVE CARE** – see p. Op310 >>

## TISSUE PROCESSING TECHNIQUES

Evaluation	Technique	Fixative	Staining
Cytological	Imprint/touch	Alcohol	Rapid H & E, Diff-Quik Papanicolaou
	Smear/squash		
Routine histological	Frozen section	Alcohol	Rapid H & E, metachrome B, special staining
	Paraffin section	Formalin, B5	
Special histological: histochemistry, immunohistochemistry	Frozen section	None	Enzymes, biochemical reactions
	Frozen or paraffin	Variable	Mono- or poly-clonal antibodies
Electron microscopy	Thick section	Glutaraldehyde/OsO <sub>4</sub>	Toluidine blue
	Thin section		Lead citrate/uranyl acetate

Frozen sections:

- may provide *specific diagnosis* in some cases (but in many situations definitive diagnosis can be made only after evaluation of all tissue specimens and with adjunctive studies).
- sometimes used to *guide resection* of mass lesion.

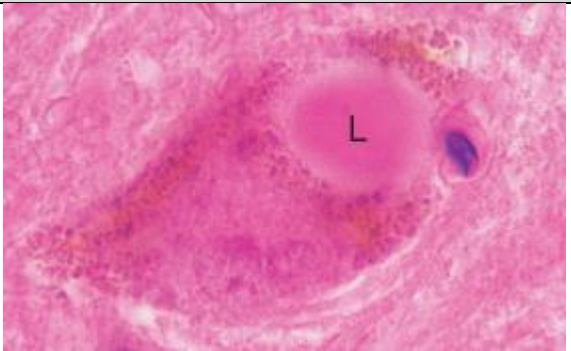

Ancillary studies:



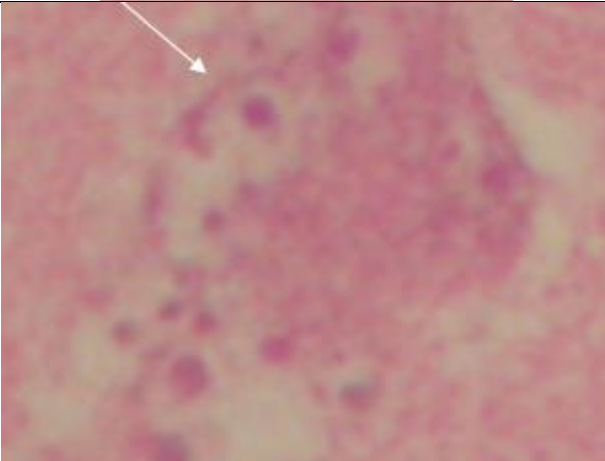
- 1) microbiology (e.g. bacterial, viral, fungal cultures)
- 2) cytogenetics (e.g. karyotype analysis)
- 3) molecular genetics (e.g. PCR)
- 4) biochemical analyses.

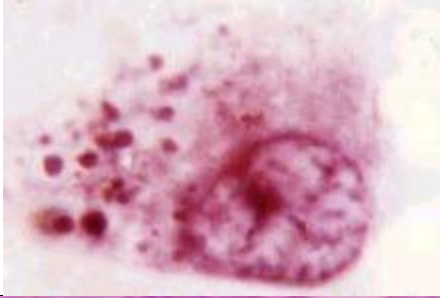
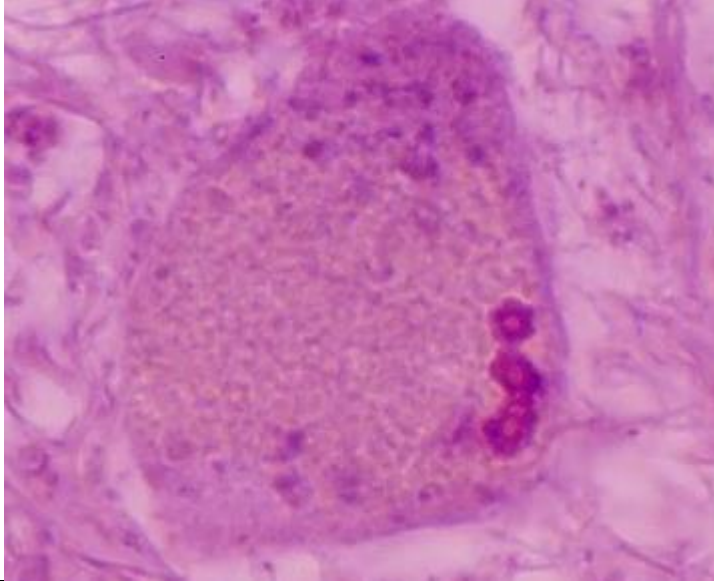
**FINDINGS**

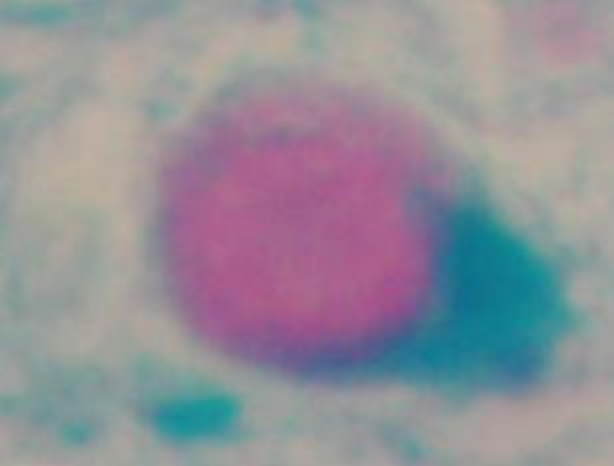
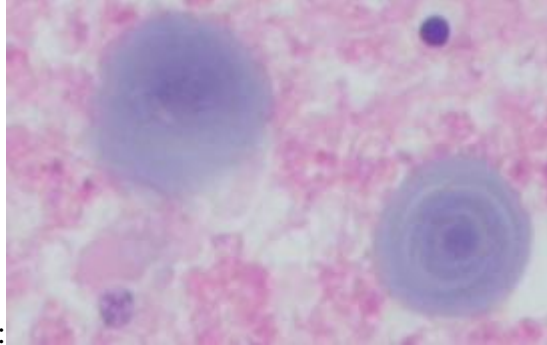
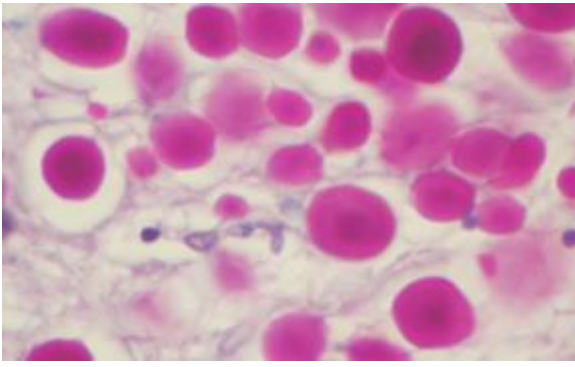
**INCLUSIONS, BODIES**

eosinophilic  
 basophilic  
 electron microscopy


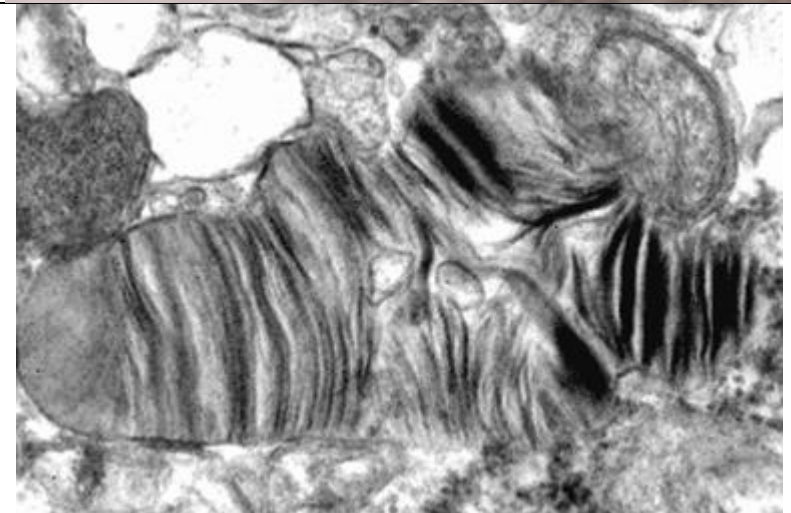
Disease	Inclusion name	Photo	Location (in cell)	Cells affected	Contents
Parkinson disease see p. Mov10 >>	LEWY bodies		cytoplasm	neurons	<i>neurofilament, tubulin, <math>\alpha</math>-synuclein</i> and <i>ubiquitin</i>
Pick disease (frontotemporal dementia) see p. S11 >>	PICK bodies		cytoplasm	neurons	

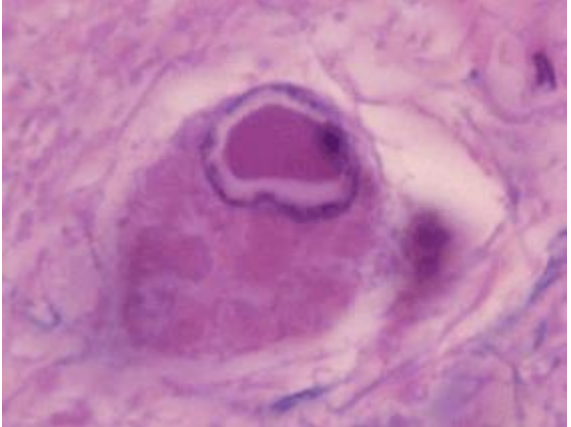
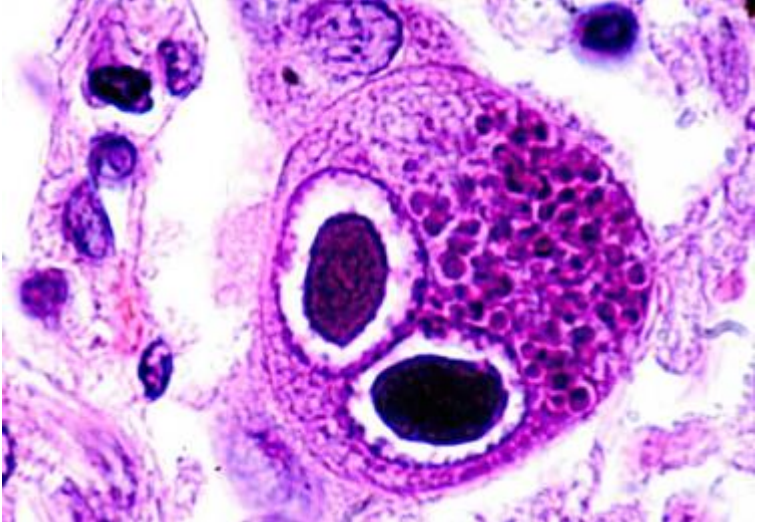
<p>Alzheimer disease see p. S11 &gt;&gt;</p>	<p>Neurofibrillary tangles</p>		<p>cytoplasm</p>	<p>neurons</p>	<p><b>TAU protein</b></p>
<p>Normal aging, neurodegenerative disorders (Alzheimer's disease, Pick disease, Creutzfeldt-Jakob disease)</p>	<p>HIRANO bodies</p>		<p>cytoplasm</p>	<p>neurons</p>	<p><i>actin</i> and actin-related proteins; no ubiquitin!</p>
<p>Normal aging, neurodegenerative disorders (Alzheimer's disease)</p>	<p>SIMCHOWICZ bodies (granulovacuolar degeneration)</p>		<p>cytoplasm</p>		<p>unknown composition</p>

					
ALS see p. Spin21 >>	BUNINA bodies		cytoplasm	neurons	unknown composition

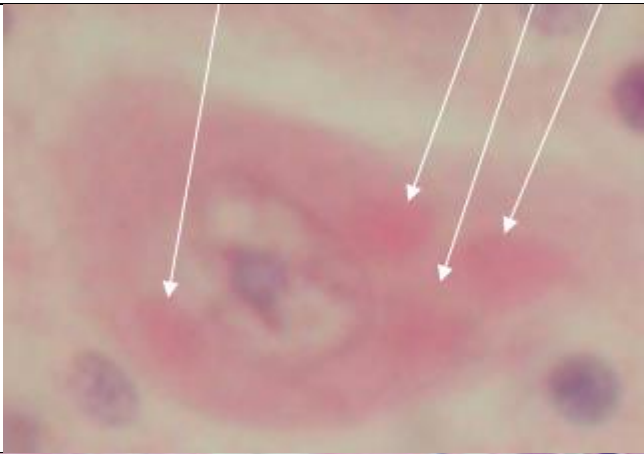
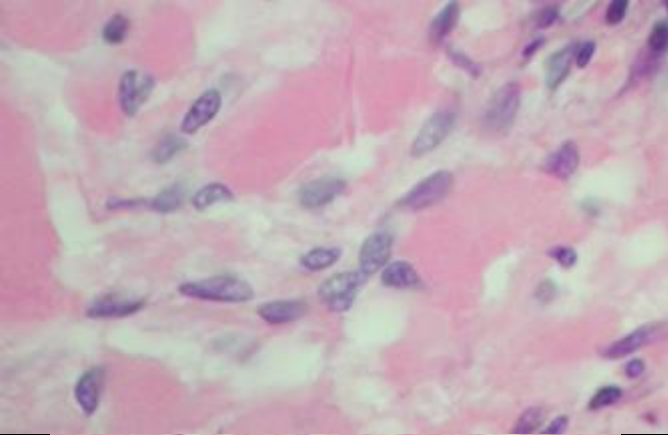
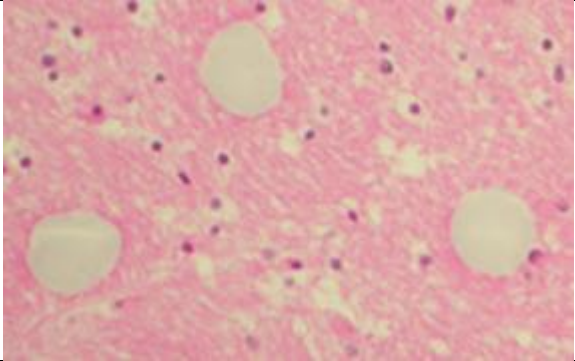
Familial myoclonic epilepsy	LAFORA bodies		cytoplasm	neurons	
Senile degenerative process	Corpora amylacea	<p>H&amp;E:</p>  <p>PAS:</p> 			

<p>Age-associated degen. changes in substantia nigra</p>	<p>MARINESCO bodies</p>		<p>cytoplasm</p>	<p>neurons</p>	<p><b>ubiquitin?</b></p>
<p>Meningioma</p>	<p>Psammoma bodies</p>				
<p>Schwannoma</p>	<p>VEROCAY body</p>		<p>extracellular</p>		

<p>Neuronal ceroid lipofuscinosis (s. cerebral sphingolipidosis)</p>	<p>Fingerprint bodies</p>				
<p>Lysosomal storage disorder, mucopolysaccharidoses I, II and III</p>	<p>Zebra bodies</p>				

<p>HSV, VZV</p>	<p>COWDRY type A</p>		<p>nucleus</p>	<p>neurons and glia</p>	
<p>CMV</p>	<p>“owl-eyes”</p>				



<p>Rabies see p. 262 (2a) &gt;&gt;</p>	<p>NEGRI bodies</p>	 <p>A light micrograph of a neuron stained with hematoxylin and eosin. The cytoplasm is filled with a dense, eosinophilic (pink) material. Three white arrows point to dark, eosinophilic, rounded inclusions within the cytoplasm, which are Negri bodies.</p>	<p>cytoplasm</p>	<p>neurons</p>	
<p>Neurosecretory granules in dilated</p>	<p>HERRING bodies</p>	 <p>A light micrograph showing neurosecretory granules in dilated terminal axons of the neurohypophysis. The granules appear as small, dark purple, oval-shaped structures within the cytoplasm of the neurons.</p>	<p>terminal axons of neurohypophysis</p>	<p>neurons</p>	
<p>Artifact of formalin fixation</p>	<p>BUSCAINO bodies</p>	 <p>A light micrograph showing Buscaino bodies, which are artifacts of formalin fixation. They appear as large, pale, rounded structures within the cytoplasm of neurons.</p>			

BIBLIOGRAPHY for “Brain Biopsy” → follow this [LINK >>](#)