

# Computed Tomography (CT), s. Computed Axial Tomography (CAT)

Last updated: June 3, 2019

<b>PHYSICS</b> .....	<b>2</b>
Helical (spiral) CT.....	2
Hounsfield scale .....	2
Windows.....	3
<b>CONTRAST ENHANCEMENT</b> .....	<b>3</b>
INTRAVENOUS CONTRAST ENHANCEMENT .....	3
Contrast medium .....	3
INTRATHECAL CONTRAST ENHANCEMENT (CT CISTERNOGRAPHY).....	5
INADVERTENT INTRATHECAL INJECTION OF IONIC CONTRAST AGENTS* .....	6
<b>TEMPORAL BONE CT</b> .....	<b>6</b>
<b>SELLAR REGION CT</b> .....	<b>8</b>
<b>ANTERIOR FOSSA CT</b> .....	<b>9</b>
<b>NORMAL VARIATIONS IN HEAD CT</b> .....	<b>9</b>
<b>PREGNANCY CONCERNS</b> .....	<b>9</b>
Dose considerations.....	10
Rate of absorption .....	10
Gestational age considerations .....	10
Counselling points.....	11
Iodinated contrast .....	11
Useful Websites.....	11
<b>SPINAL CT</b> – see p. D70 >>	
<b>CTA, PERFUSION CT</b> – see p. D64 >>	

- CT was developed in 1972-1974 by Sir Geoffrey Hounsfield and his colleagues in England.

## STRENGTHS of CT

1. **Fast** - typical high-quality brain CT requires 10-20 seconds (it takes far more time to position patient in machine than it does to do scan) – easy to use for follow up of critically ill patients.
2. **Easy to monitor patients** (vs. MRI incompatibility with ferromagnetic materials)
3. **Simplicity of interpretation** - all contrast on CT images is due to differences in **electron density** (appearance is determined by single parameter - images are relatively easy to interpret).  
If disease of interest does not change electron density, it will be invisible on CT!
4. Can easily detect **acute hemorrhage and calcification**
5. Excellent for studying **bones**

## WEAKNESSES of CT

1. **Less sensitive to parenchymal lesions** (than MRI) - normal intracranial structures have narrow range of electron density.
2. Potential for significant **contrast reaction**
3. **Radiation exposure**
4. **Artifacts** related to beam hardening (limits evaluation of posterior fossa structures).
5. **Difficulty in obtaining planes** other than axial (usually other planes are reconstructed from axial images)

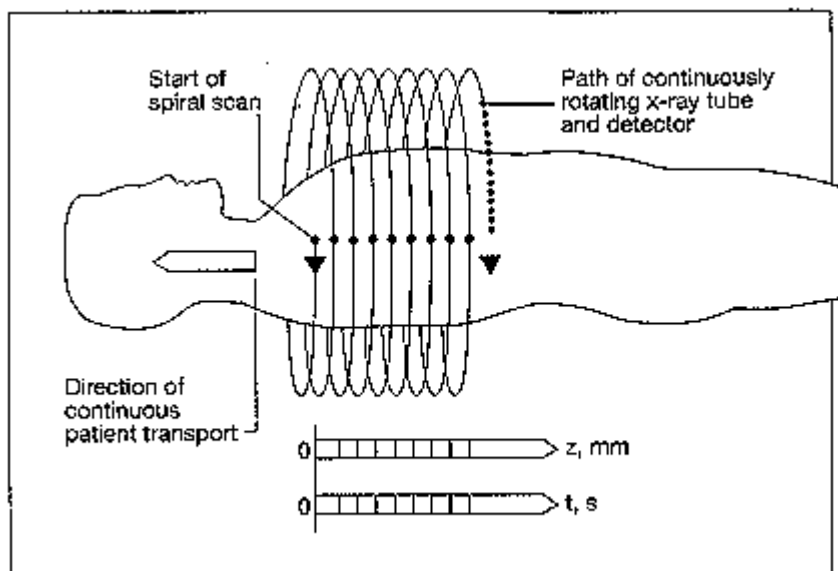
CT is not useful in evaluation of **CNS below upper pons** and **PNS** (H: MRI).

## PHYSICS

- tightly collimated X-ray beam is directed through patient.
- patient is placed in CT gantry, and X-ray beam travels in circular path around patient.
  - for **axial head CT**, gantry is angled parallel to orbitomeatal line.
  - for **coronal head CT**, patient is either supine or prone with neck hyperextended (impossible for intubated patients, patients with cervical spine disease, airway obstruction, or obesity).
- detectors 180° opposite beam measure X-ray attenuation.
- X-ray beam is collimated in range **from 1 to 10 mm** (depending on size of structure being examined) - patient is moved by same increment as slice thickness:
  - 5 mm sections through *posterior fossa*.
  - 10 mm sections through *supratentorial space*.
  - 1-3 mm sections for detailed examination of *small anatomical regions* (such as temporal bone, sella, orbits, paranasal sinuses).
- signal from radiation detector is digitized by analog-to-digital converter → image is constructed using computer (with air seen as black and bone as white).
- typical radiation dose for head CT  $\approx$  30-60 mGy.

### HELICAL (SPIRAL) CT

- differs from conventional CT in that *patient is moved continuously* through x-ray beam → **dramatically shortened scanning times**:
  - a) **traumatized** or **uncooperative** patients
  - b) enables **CT angiography** (rapid collection of images after contrast bolus is injected)
- "pitch" - distance table moves in millimeters for every rotation of tube.
- "pitch factor" (unitless term) = pitch divided by slice thickness.
- *reformatting* images or *3D reconstructions* are smoother and more accurate, but **some loss of resolution** - helical CT is not employed in routine brain imaging.



### HOUNSFIELD SCALE

(named after Godfrey N. Hounsfield, inventor of CT) – relative scale of *electron density*:

Tissue	Hounsfield Unit	Gray Scale
--------	-----------------	------------

Air	-1000	very black
Fat	-100	black
Water*	0	black
Cerebrospinal fluid	4-10	black
White matter	22-36	gray
Gray matter	32-46	gray
Extravasated blood	50-90	white
Contrast medium**	100	white
Bone	800-1000	very white

\*edema (water content↑) is seen as lucency

\*\*in any case of suspected acute hemorrhage, contrast medium should not be administered (similar attenuation characteristics to acute extravascular blood)

N.B. *acute hematoma* has high attenuation owing to clot retraction with **separation of high-density erythrocytes from lower density plasma**;

N.B. *unclothed blood* (**coagulopathy** or **hyperacute active bleeding**) is seen as relative lucency!

### WINDOWS

- **BRAIN windows** (60-80 HU) accentuate minor difference in Hounsfield units between *white and gray matter*.
- **BONE windows** (2000-4000 HU): brain is not seen!
  - a) *bone* evaluation (in trauma, bone infection, bone neoplasm)
  - b) detection of intracranial *air* (can separate air and fat density).
- **SUBDURAL windows** (150-200 HU) - to identify *acute subdural hematomas* (would blend with calvarium on routine brain images).

## CONTRAST ENHANCEMENT

### INTRAVENOUS contrast enhancement

Basics, Indications → see p. D45 >>

Pregnancy concerns – *see below* >>

In general, it is preferable to perform MRI than to perform CT with contrast enhancement

CT without contrast enhancement is of little value in diagnosis of brain tumors or other mass lesions!

*although hemorrhage, calcifications, hydrocephalus, shifts can be well seen on non-contrast CT, underlying causative structural abnormality can be missed.*

- routine use of *nonenhanced* CT scan before *enhanced* scan is of limited usefulness (recommended only for lesions with **hemorrhagic** / **calcified** components).

### CONTRAST MEDIUM

- **water-soluble IODINATED**:

- a) *ionic* (higher-osmolality)
- b) *non-ionic* (more expensive but safer! - **low-osmolality** - extremely low incidence of side effects)

*Specific indications for nonionic contrast agents:* previous adverse reaction to ionic agent, asthma, multiple allergies, cardiac problems (incl. CHF, pulmonary hypertension), severe general debilitation.

Maximum dose with normal renal function – **86-90 gm of IODINE** in 24 hour period.

- given as **intravenous drip** or as **IV bolus**.
- CTA uses  $\approx 21$  gm of iodine – GFR has to be  $> 45$  (vs.  $> 30$  for gadolinium)

Side effects - iodinated contrast agents are *physiologically inert* except for:

In general, both high- and low-osmolar contrast agents are **extremely safe!**

1. **Allergy** (rare\*, readily manageable); prophylaxis (e.g. in patients with allergic histories – best use MRI instead):
  - 1) **PREDNISONE** 50 mg orally (13, 7, and 1 hour before contrast injection).
  - 2) **DIPHENHYDRAMINE** 50 mg orally (1 hour before contrast injection).
  - 3) history of laryngospasm / hypotension with previous use of contrast → **anesthesiologist** should be present during contrast administration.  
\*severe allergic reactions - 0.04% patients receiving nonionic media
2. **Oncotic load**:
  - 1) *sensation of heat, pain, nausea, vomiting* (well-known side effect of ionic contrast media).
  - 2) potential **nephrotoxicity** (**CONTRAST NEPHROPATHY**):
    - risk is very little in normally hydrated patients who do not have kidney disease.
    - states that predispose to kidney injury: advanced age, multiple myeloma, severe diabetes, dehydration, recent aminoglycoside exposure, preexisting chronic renal dysfunction (anuria, hepatorenal syndrome, serum creatinine  $> 3$  mg/dL).
    - definition of **CONTRAST NEPHROPATHY**: **rise in serum [creatinine]** of at least 1 mg/dL within 48 h of contrast administration.
    - prognosis is usually favorable.
    - prophylaxis – **good hydration** ( $\pm$  **bicarbonates, acetylcysteine**) prior IV contrast administration.

Guidelines for use of IV contrast in impaired renal function:

Serum Creatinine, $\mu\text{mol/L}$ (mg/dL)	Guideline
$< 133$ ( $< 1.5$ )	Use contrast at 2 mL/kg (max. 150 mL total)
133–177 (1.5–2.0)	Use nonionic contrast; hydrate diabetics
$> 177$ ( $> 2.0$ )	Consider noncontrast CT or MRI
177–221 (2.0–2.5)	Nonionic contrast contraindicated in diabetics
$> 265$ ( $> 3.0$ )	Nonionic contrast given only to patients undergoing dialysis within 24 h

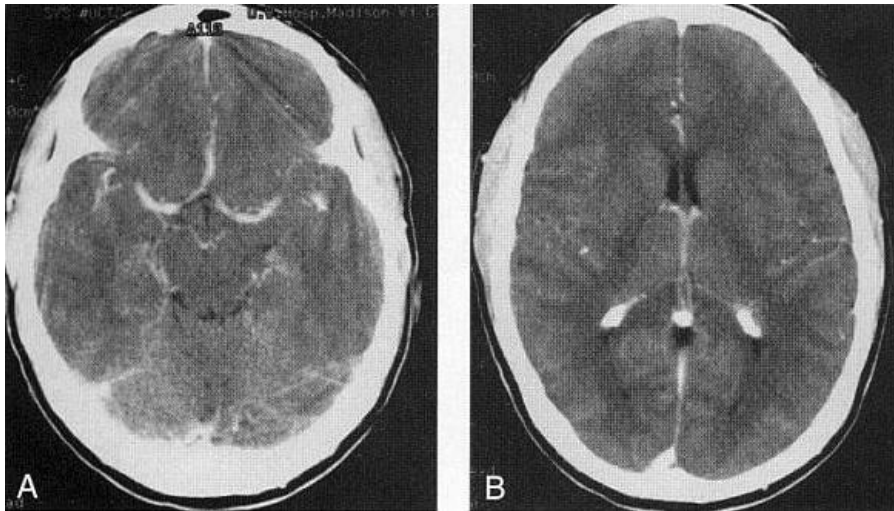
3. Iodinated contrast (IV or intra-arterial) may delay excretion of **METFORMIN**;
  - manufacturer recommends withholding metformin 48 hrs prior to and following contrast administration (or longer if there is evidence of declining renal function following use of contrast).

N.B. avoid of iodine contrast in *diabetics who are getting oral antidiabetic agents like metformin* - risk of **lactic acidosis!!!**

### Contraindications

1. **Acute renal failure** (absolute contraindication)
2. Renal insufficiency (H: dialysis soon after study)

Normal CT following IV contrast medium: arterial and venous structures at base of brain are prominent; also normal enhancement of falx cerebri and choroid plexus of lateral ventricles:



### INTRATHECAL contrast enhancement (CT cisternography)

- injection into **lumbar subarachnoid space**:

- small volumes of **air**.
- low doses of **water-soluble contrast medium** ( $\approx 1$  g IODINE).

*e.g. 10 ml of Iohexol (concentration of 240 mg/ml) is usually more than adequate*

Primary approved agent employed for intrathecal use today is **IOHEXOL** (Omnipaque®)

• information obtained:

- cisternal spaces**
- CSF leaks**
- communication** between various CSF-containing spaces.

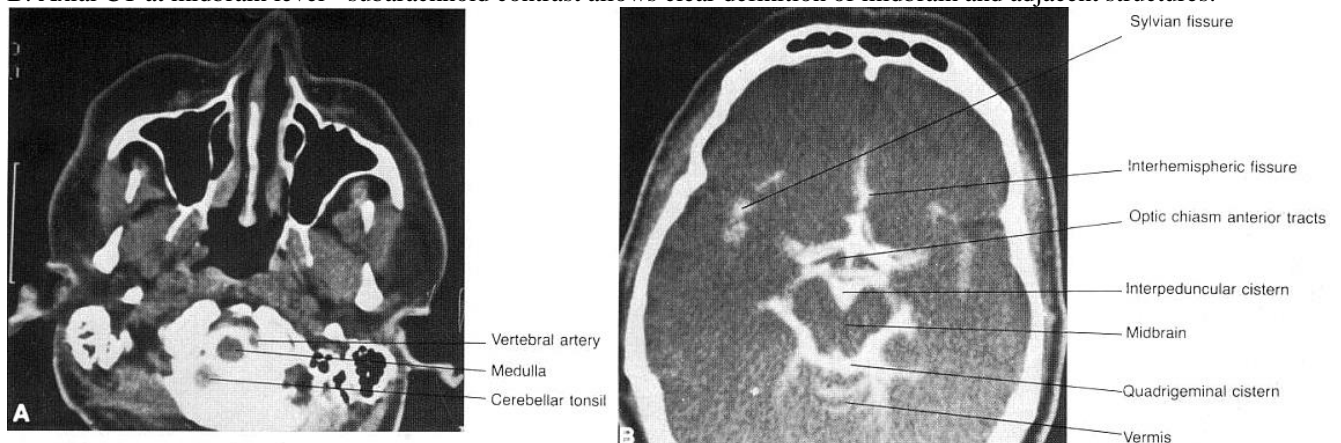
N.B. natural contrast provided by CSF on MRI examinations has eliminated need for CT cisternography!

• only modern indication - to identify **site of CSF leaks** before operative closure.

technique – see S64 p.

A. Axial CT at level of foramen magnum - subarachnoid contrast outlines vertebral arteries, cerebellar tonsils, and medulla.

B. Axial CT at midbrain level - subarachnoid contrast allows clear definition of midbrain and adjacent structures:



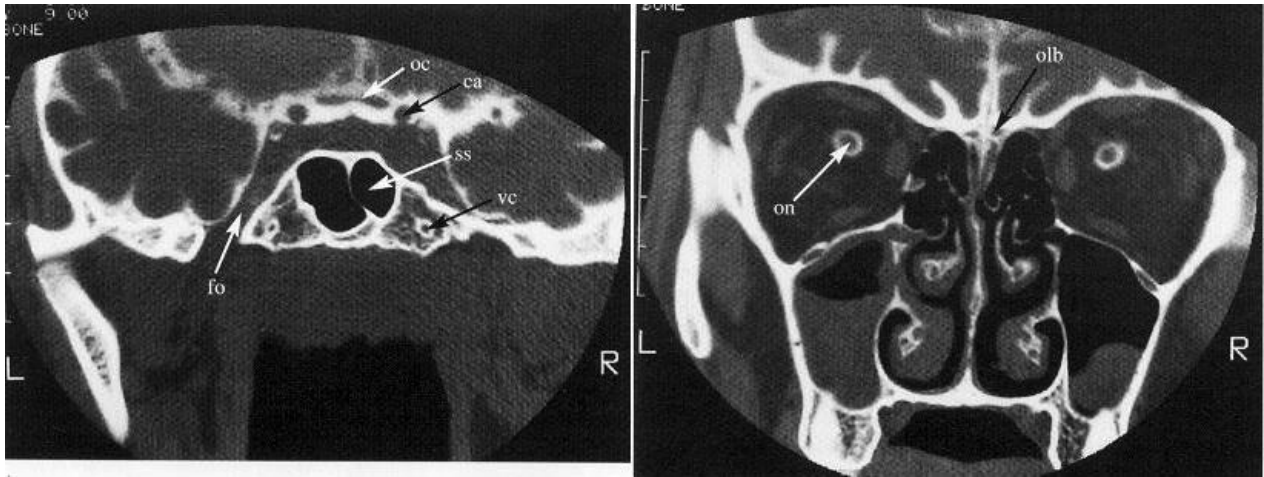
CT cisternography:

(A) level of olfactory grooves

(B) level of foramen ovale; intrathecal contrast outlines subarachnoid space and extends into optic nerve sheaths, outlining optic nerves.

ca = carotid artery, fo = foramen ovale, oc = optic chiasm, ob = olfactory bulb, on = optic nerve, ss = sphenoid sinus, vc = vidian canal.





### INADVERTENT INTRATHECAL INJECTION OF IONIC CONTRAST AGENTS\*

\*i.e. agents not specifically indicated for intrathecal use.

Clinical Features (significant fatality rate): uncontrollable seizures, intracerebral hemorrhage, cerebral edema, coma, paralysis, arachnoiditis, myoclonus, rhabdomyolysis with subsequent renal failure, hyperthermia, and respiratory compromise

#### Management:

1. **Immediately remove CSF** + contrast if the error is recognized when the opportunity is available (e.g. withdraw fluid through myelography needle)
2. **Elevate head of bed 45°** (to keep contrast out of head)
3. IV **steroids, antihistamines**: e.g. DIPHENHYDRAMINE 50 mg deep IM
4. **AED**: more than one agent may be required (e.g. phenytoin + phenobarbital + benzodiazepine); repeat EEGs to assess seizure activity while sedated/paralyzed
5. **Lumbar subarachnoid drain**
6. Pharmacologic paralysis (PRN muscle activity)
7. IV hydration, control HTN, sedation if patient is agitated
8. Respiration: supplemental oxygen / intubation
9. Treat fever (acetaminophen, cooling blanket)
10. Monitor: electrolytes, creatine kinase (CK)
11. If there is question about what may have occurred (i.e. it is not certain if inappropriate contrast agent was used):
  - 1) send **blood** and **CSF** with contrast for high performance liquid chromatography for identification of agent
  - 2) **plain CT scan**: may help assess if contrast has diffused intracranially, but this requires placing patient flat and may not be advisable

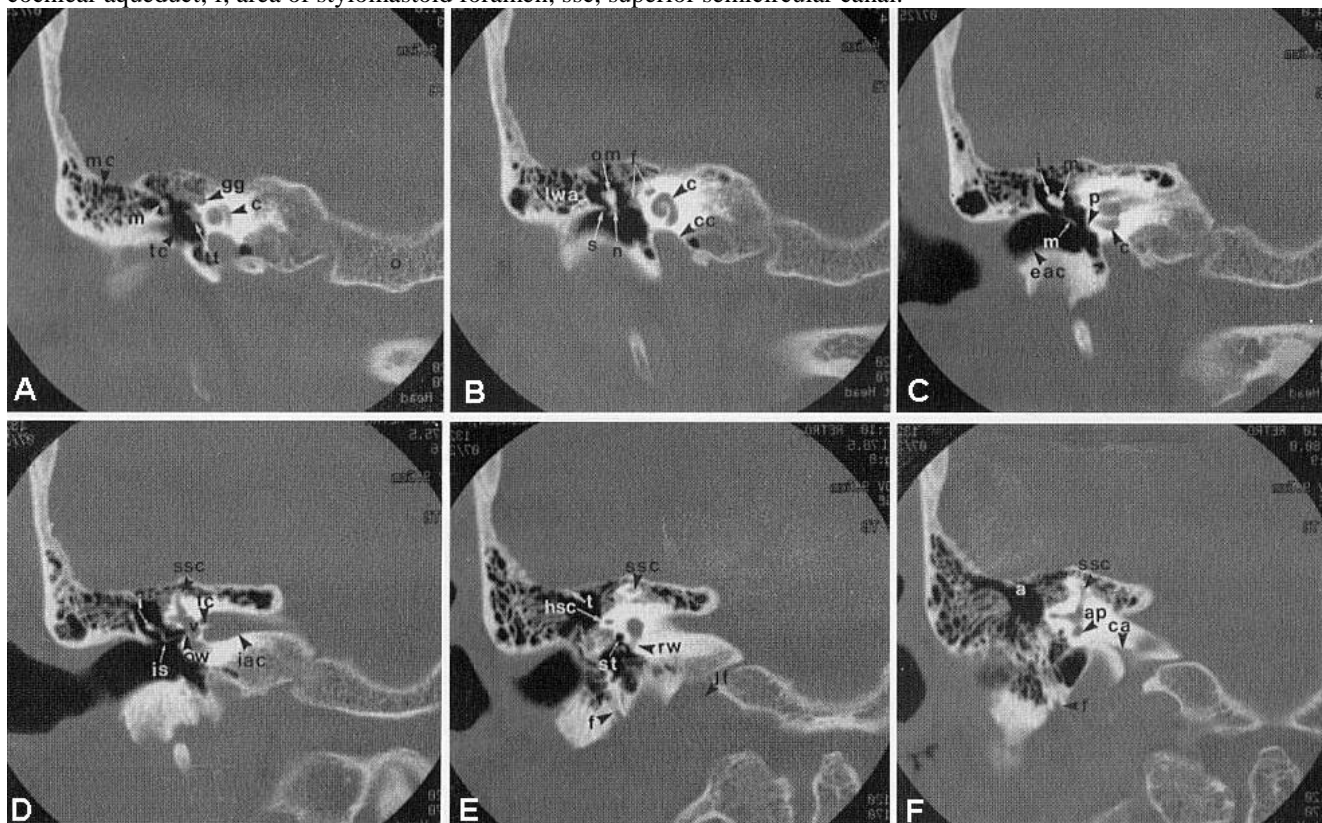
### TEMPORAL BONE CT

**Thin-section high-resolution CT** is study of choice for evaluating temporal bone (exquisite bone detail highlighted by air)!

- requires very thin sections (1 to 2 mm), small field of view (< 10 cm), and high-spatial-resolution reconstruction algorithm.

Temporal bone, CORONAL high-resolution CT, bone algorithm:

- A: Plane of head of malleus and geniculate ganglion** (most anterior plane). c, First cochlear turn; gg, geniculate ganglion fossa; m, head of malleus; mc, mastoid air cells; o, occipital bone; tc, tympanic cavity; tt, tendon of tensor tympani muscle.
- B: Plane of ossicular mass and midcochlea** (c). cc, Carotid canal; f, first and second portions of facial nerve canal; lwa, lateral wall of attic; n, neck of malleus; om, ossicular mass (malleus and incus); s, bony spur or scutum.
- C: Plane of incus**. c, Basal turn of cochlea; eac, external auditory canal; i, body of incus; black m, head of malleus; white m, manubrium of malleus; p, cochlear promontory.
- D: Plane of oval window**. i, Body of incus; iac, internal auditory canal; is, incudostapedial articulation; ow, oval window; ssc, superior semicircular canal.
- E: Plane of round window**. f, Vertical portion of facial nerve canal; hsc, horizontal semicircular canal; jf, jugular fossa; rw, round window; ssc, superior semicircular canal; st, sinus tympani; t, tegmen tympani.
- F: Plane of cochlear aqueduct** (most posterior plane). a, Mastoid antrum; ap, ampulla of posterior semicircular canal; ca, cochlear aqueduct; f, area of stylomastoid foramen; ssc, superior semicircular canal.

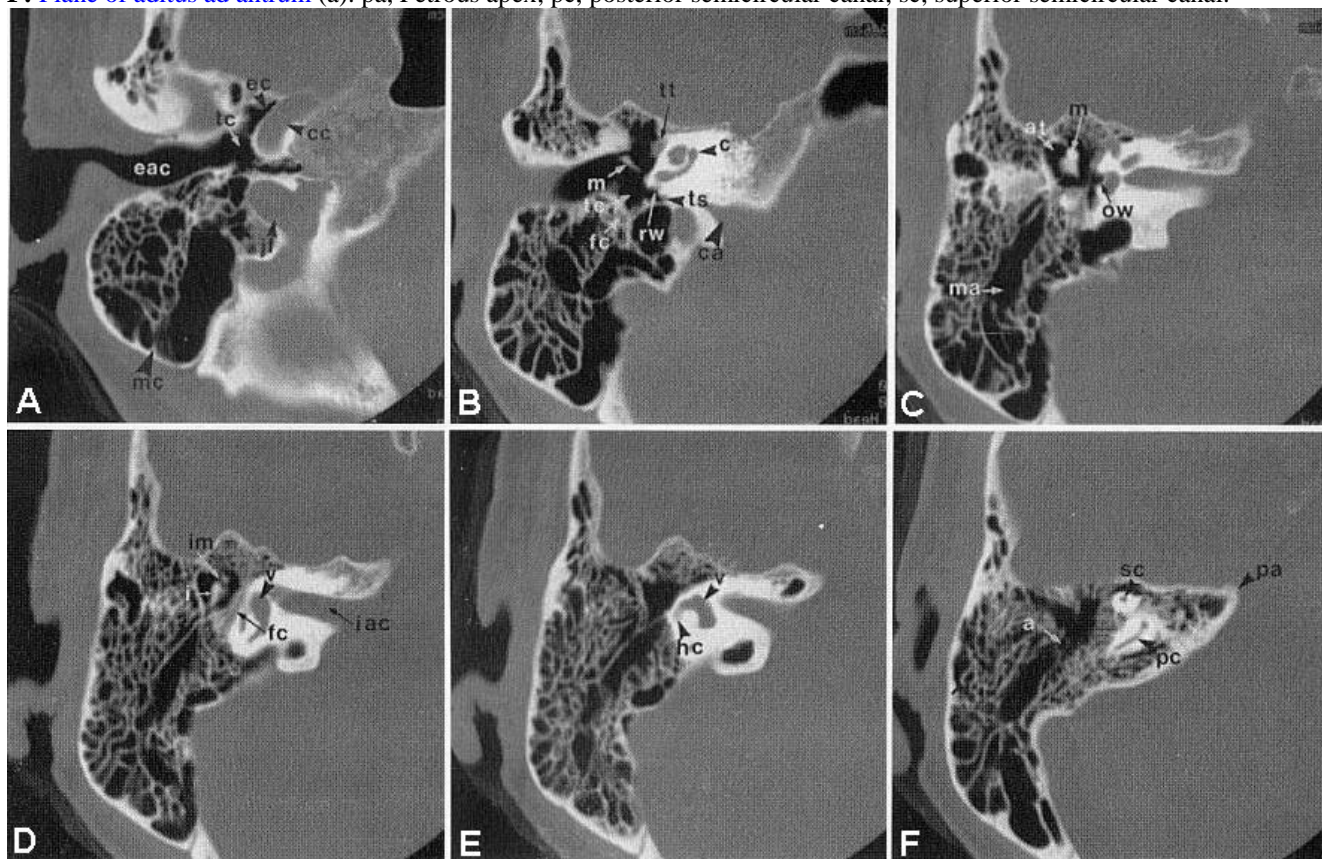


Temporal bone, AXIAL high-resolution CT, bone algorithm:

- A: Plane of hypotympanum** (most inferior plane). cc, Carotid canal; eac, external auditory canal; ec, eustachian canal; jf, jugular fossa; mc, mastoid air cells; tc, tympanic cavity (hypotympanum).
- B: Midcochlear plane**. c, Basal turn of cochlea (intermediate and apical turns are adjacent); ca, cochlear aqueduct; fc, vertical portion of facial nerve canal; m, handle of malleus; tc, tympanic cavity; ts, tympanic sinus; tt, tensor tympani muscle.
- C: Plane of oval window**. at, Attic (epitympanic recess); m, head of malleus; ma, mastoid antrum; ow, oval window.
- D: Plane of incudomalleolar articulation**. fc, Facial canal; i, body of incus; iac, internal auditory canal; im, incudomalleolar articulation; v, vestibule.
- E: Plane of horizontal semicircular canal** (hc). v, Vestibule.

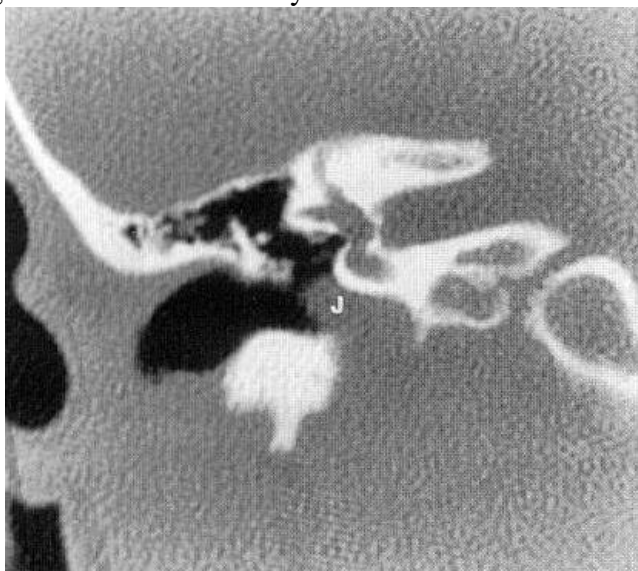


**F: Plane of aditus ad antrum** (a). pa, Petrous apex; pc, posterior semicircular canal; sc, superior semicircular canal.



Some normal ANATOMIC VARIANTS: (may be mistaken for *GLOMUS TUMORS*)

1. Most common major variant - **dehiscent (anomalous) jugular bulb** - absence of thin bony plate (jugular plate) between *internal jugular vein* and *middle ear cavity* - this allows jugular vein (J) to bulge into middle ear cavity:



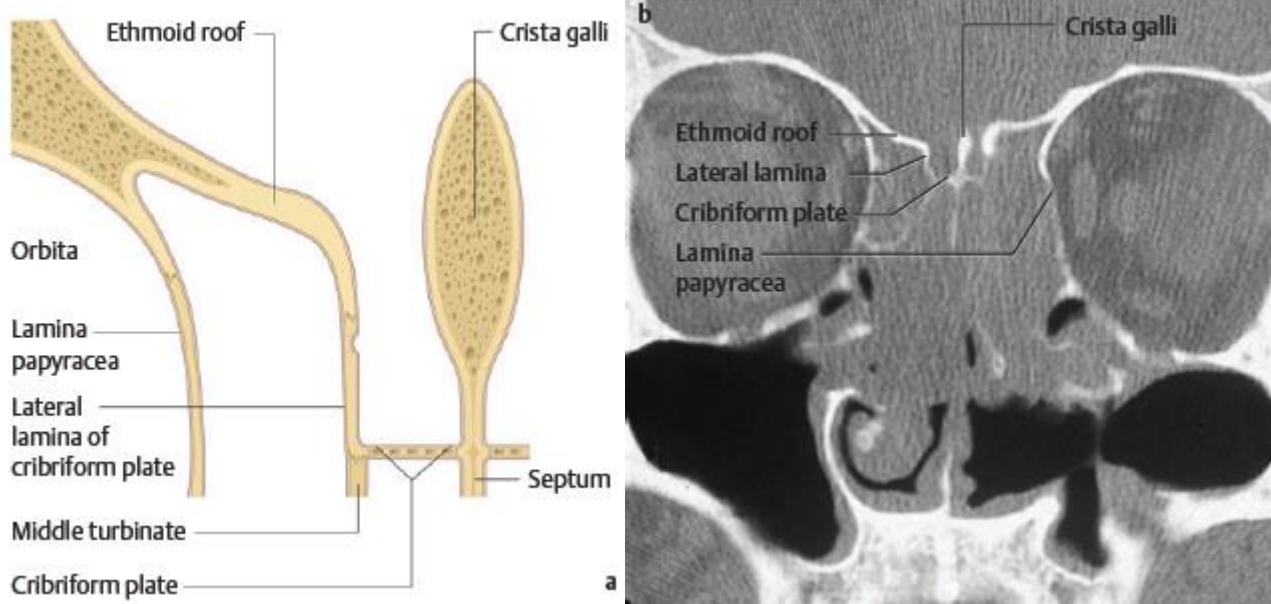
2. **Aberrant internal carotid artery.**

## SELLAR REGION CT

- performed in **coronal plane**\* with **IV contrast**.  
\*patient's position for study is uncomfortable → inconsistent image quality  
(MRI is study of choice for region of sella!)



## ANTERIOR FOSSA CT



## NORMAL VARIATIONS IN HEAD CT

- normally **calcified structures** – see S70 p.
- normally **enhancing structures** – see D45 p.
- no focal **white matter** low densities should be seen in young or middle-age patients.
  - in patients > 65 yrs. *mild periventricular hypodensities* are part of normal aging process.
- **ventricles**: mild differences in sizes of bodies, frontal, temporal, and occipital horns are common.
  - ventricles and subarachnoid spaces increase in size with increasing age.
  - in older patient, ventricles should not be dilated out of proportion to subarachnoid space.

## PREGNANCY CONCERNS

Effects of radiation depending on dose of radiation absorbed and fetal gestational age:

Menstrual or Gestational Age	Conception Age	<50 mGy (<5 rad) <sup>b</sup>	50–100 mGy (5–10 rad) <sup>b</sup>	>100 mGy (>10 rad) <sup>b</sup>
0–2 weeks (0–14 days)	Prior to conception	None	None	None
Third and fourth weeks (15–28 days)	First–second weeks (1–14 days)	None	Probably none	Possible spontaneous abortion
Fifth–10th weeks (29–70 days)	Third–eighth weeks (15–56 days)	None	Potential effects are scientifically uncertain and probably too subtle to be clinically detectable	Possible malformations increasing in likelihood as dose increases
11th–17th weeks (71–119 days)	Ninth–15th weeks (57–105 days)	None	Potential effects are scientifically uncertain and probably too subtle to be clinically detectable	Increased risk of deficits in IQ or mental retardation that increases in frequency and severity with increasing dose
18th–27th weeks (120–189 days)	16th–25th weeks (106–175 days)	None	None	IQ deficits not detectable at diagnostic doses
>27 weeks (>189 days)	>25 weeks (>175 days)	None	None	None applicable to diagnostic medicine

<sup>a</sup> Modified from American College of Radiology.<sup>3</sup> Reprinted with permission of the American College of Radiology. No other representation of this material is authorized without expressed, written permission from the American College of Radiology. Refer to the ACR website at [www.acr.org/Quality-Safety/Standards-Guidelines](http://www.acr.org/Quality-Safety/Standards-Guidelines) for the most current and complete version of the ACR Practice Guidelines.

<sup>b</sup> Columns 3, 4, and 5 describe the suspected fetal effects due to the increasing amounts of fetal radiation exposure delineated in the column headings.

- imaging parameters (incl. estimated dose received) should be included in all CT reports and become part of patient's medical record.

### DOSE CONSIDERATIONS

- low-dose irradiation to fetus has been linked to increased risk of childhood cancer, particularly leukemia:
  - baseline rate of childhood leukemia, 3.6 per 10,000 children → 5 per 10,000 after in utero exposures of 1-2 rad.
  - meta-analysis showed 6% increase in risk of childhood cancer per 100 rad.
- even with repeated imaging, however, such exposures would not be achieved; therefore, *attributable risk of childhood cancer from modern clinical imaging is believed to be low.*

### RATE OF ABSORPTION

- during entire gestation, fetal exposure to **background environmental radiation** is 0.23 rad.
- with CT, dose absorbed by fetus varies based on maternal size, examination parameters, and whether it receives direct rather than indirect radiation.
  - a) **direct radiation:** 0.28-2.4 rad for lumbar spine CT, up to 3 rad for abdomen/pelvis CT..
  - b) **indirect radiation** (e.g. CT of maternal head or cervical spine) - fetus is exposed only to attenuated scattered radiation with dose estimated at < 0.01 rad

N.B. during head/cervical CT, fetus is exposed only to radiation that is scattered through mother's body; shielding of abdomen (lead vest), does not significantly reduce minimal fetal radiation exposure but may help to alleviate maternal anxiety!

### GESTATIONAL AGE CONSIDERATIONS

**Conception to implantation (days 0-15)** - period of highest risk, with all-or-nothing effect: animals exposed to radiation during this period experience either death or no consequences; atomic bomb survivors exposed before 15 days gestational age had no sequelae.

- increased risk of miscarriages through week 4 is usually cited.

**Organogenesis (weeks 3-8)** - increased risk of congenital malformations, transient growth retardation, and neonatal death in animal studies.

- human fetuses exposed to medical irradiation during this period also manifested malformations, but in atomic bomb survivors, only dose-dependent **microcephaly** was noted.

**8 to 15 weeks** - most sensitive period: 12-20-rad dose threshold (much higher than used in clinical imaging) is associated with increased risk of **mental retardation**.

- this risk is 4 times greater than in period **15-25 weeks**, beyond which risk is negligible.

### COUNSELLING POINTS

- 1) fetal-absorbed doses of **< 5 rad (50 mGy)** - no definitive association with increased risk of **spontaneous abortion**, **developmental malformations**, or **mental retardation** has been proven.
- 2) fetal-absorbed doses of **5-15 rad (50-150 mGy)** may result in a small but detectable increase in risk of **congenital defects** above baseline population risk (5% → 10%).
- 3) very small association exists between radiation and **childhood malignancies**.

### IODINATED CONTRAST

- IV iodinated contrast ***should be avoided*** during pregnancy if possible.
- iodinated contrast is classified by FDA as **class B (Appendix A)** - animal studies have not shown teratogenic or mutagenic outcomes from iodinated contrast exposure, and well-controlled studies have not been performed in humans.
- iodinated contrast ***instilled directly into fetal cavity*** (as opposed to intravenously) has been associated with **neonatal hypothyroidism** - written informed consent should be obtained and neonatal thyroid function testing should be performed in the first week of life.
- standard precautions pertaining to risk of contrast-induced nephropathy should be followed.
- **during lactation**, no adverse effect on infant of low concentrations of iodinated contrast transmitted in breast milk has been proven (24-hour period of “pump and dump” interruption from breast-feeding may be preferred by nursing mother but is not indicated).

### USEFUL WEBSITES

See p. D51 >>

**BIBLIOGRAPHY** for ch. “Diagnostics” → follow this [LINK >>](#)