

Neural Tube Disorders (s. Dysraphism)

Last updated: September 5, 2017

Classification..... 1

ETIOPATHOPHYSIOLOGY..... 1

 Theories..... 1

 Etiology..... 1

EPIDEMIOLOGY..... 1

CLASSIFICATION, PATHOLOGY, CLINICAL FEATURES..... 1

 CRANIOSCHISIS..... 1

 Encephalocele..... 2

 SPINA BIFIDA..... 3

 Myelomeningocele..... 3

DIAGNOSIS..... 5

 PRENATAL DIAGNOSIS..... 5

 POSTNATAL DIAGNOSIS..... 5

MANAGEMENT..... 6

 ENCEPHALOCELES..... 6

 MYELOMENINGOCELE..... 6

 MENINGOCELE..... 6

PROGNOSIS..... 6

PROPHYLAXIS..... 6

NEURENTERIC CYST, EPIDERMOID CYST, DERMOID CYST → see p. Onc30 >>

NEURAL TUBE DISORDERS (s. NEURULATION defects, s. DYSRAPHIA) – most common CNS malformations!

CLASSIFICATION

→ see p. Dev1 >>

ETIOPATHOPHYSIOLOGY

EMBRYOLOGY → see p. A13 (1) >>

THEORIES

- a) **REOPENING** of closed neural tube – questionable.
- b) **NONCLOSURE** (failure of neural folds to come together) – probably correct theory!
 - normal closure begins on **20th day** after fertilization and is complete by **28th day** – i.e. ≈ 1-2 weeks beyond expected normal menstrual cycle - *women is frequently unaware that she is pregnant* during this critical time!

ETIOLOGY

- classic **multifactorial**;
- epidemiological-experimental investigations have *failed to identify obvious source*.
- **genetic factors** certainly play important role in at least conferring predisposition (*monoallelic disorders* are occasionally associated with neural tube defects).
- at least in cranial region, neural tube closure **occurs not in single continuous closure** but at *multiple sites* and *in coordinated pattern* - each defined site is **under control of different genes** (susceptible to different factors).

EPIDEMIOLOGY

- among most common major malformations (0.001-1% of all human malformations).
- **INCIDENCE** - overall decline in past decades.

Myelomeningocele – 1 in 1000* live births – most common anomaly of nervous system!

*3-4 in 1000 in England, Ireland, Scotland, and Wales

Encephalocele – 1 in 5000-10000 live births.

Anencephaly – 0,1-1 in 1000 live births (greatest frequency is in Ireland and Wales)

Risk factors:

- 1) maternal **hyperthermia**
- 2) maternal **diabetes**
- 3) **anticonvulsants** (esp. *VALPROIC ACID* – causes dysraphism in 1-2% patients, *CARBAMAZEPINE*)
- 4) **previous** infant / fetus with neural tube defect (risk increases 10-fold)
- 5) low socioeconomic status.

CLASSIFICATION, PATHOLOGY, CLINICAL FEATURES

All cases involve bone / soft tissues ± underlying neural tissue. see p. Dev1 >>

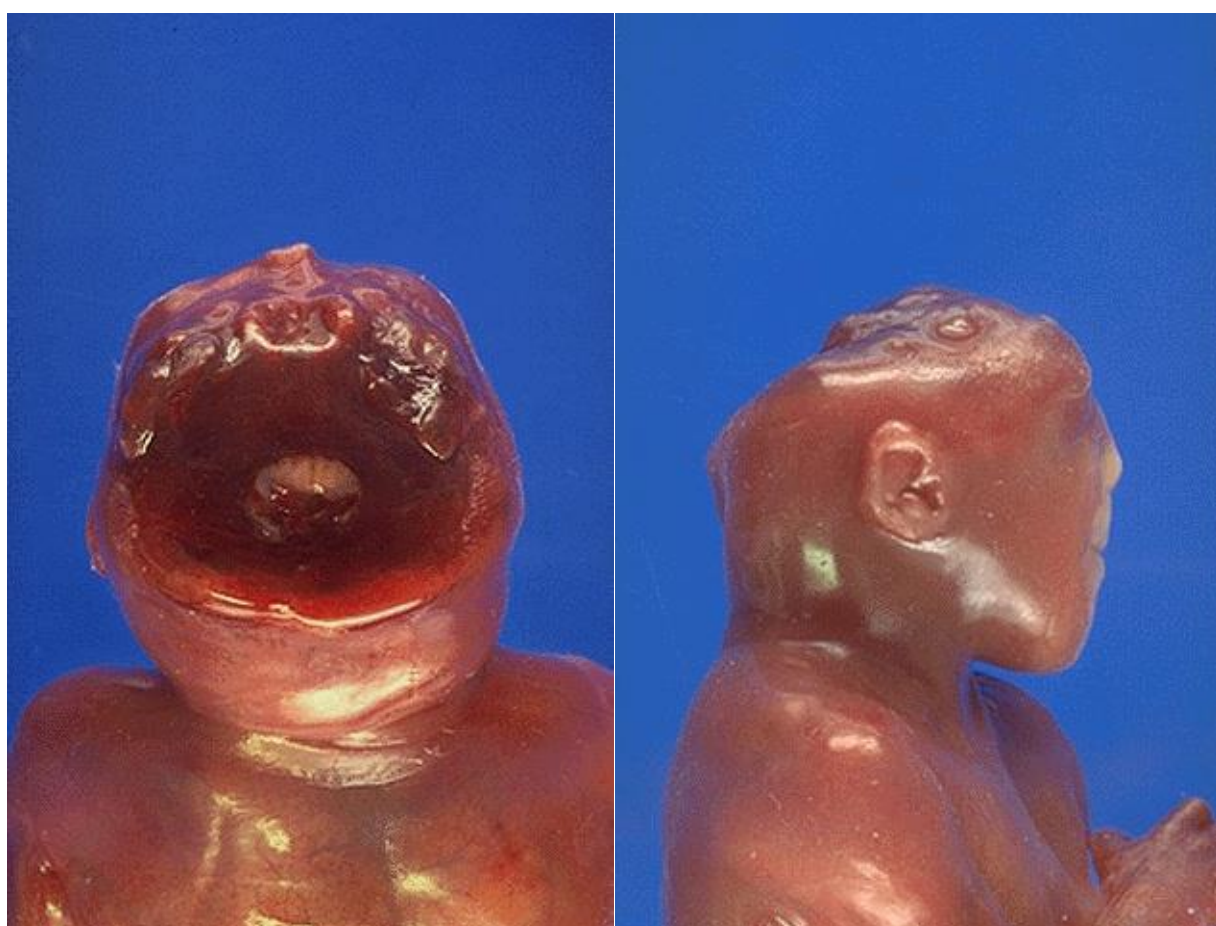CRANIOSCHISIS

ANENCEPHALY (“absence of head”) - **cranial neuropore closure defect** (develops at ≈ 28th day of gestation) - absence of **brain** and **calvarium**; no **epidermal covering**.

- vast majority of cases show **complete absence of most of brain**.
 - **anterior pituitary, eyes, brainstem** are usually spared.
 - spinal cord pyramidal tracts are missing due to absence of cerebral cortex.
- neural epithelium is present in embryo, but direct contact with amniotic fluid results in degeneration of neural epithelium.
- remaining tissue covering basal cranium is highly vascular and friable membrane (*area cerebrovasculosa*).

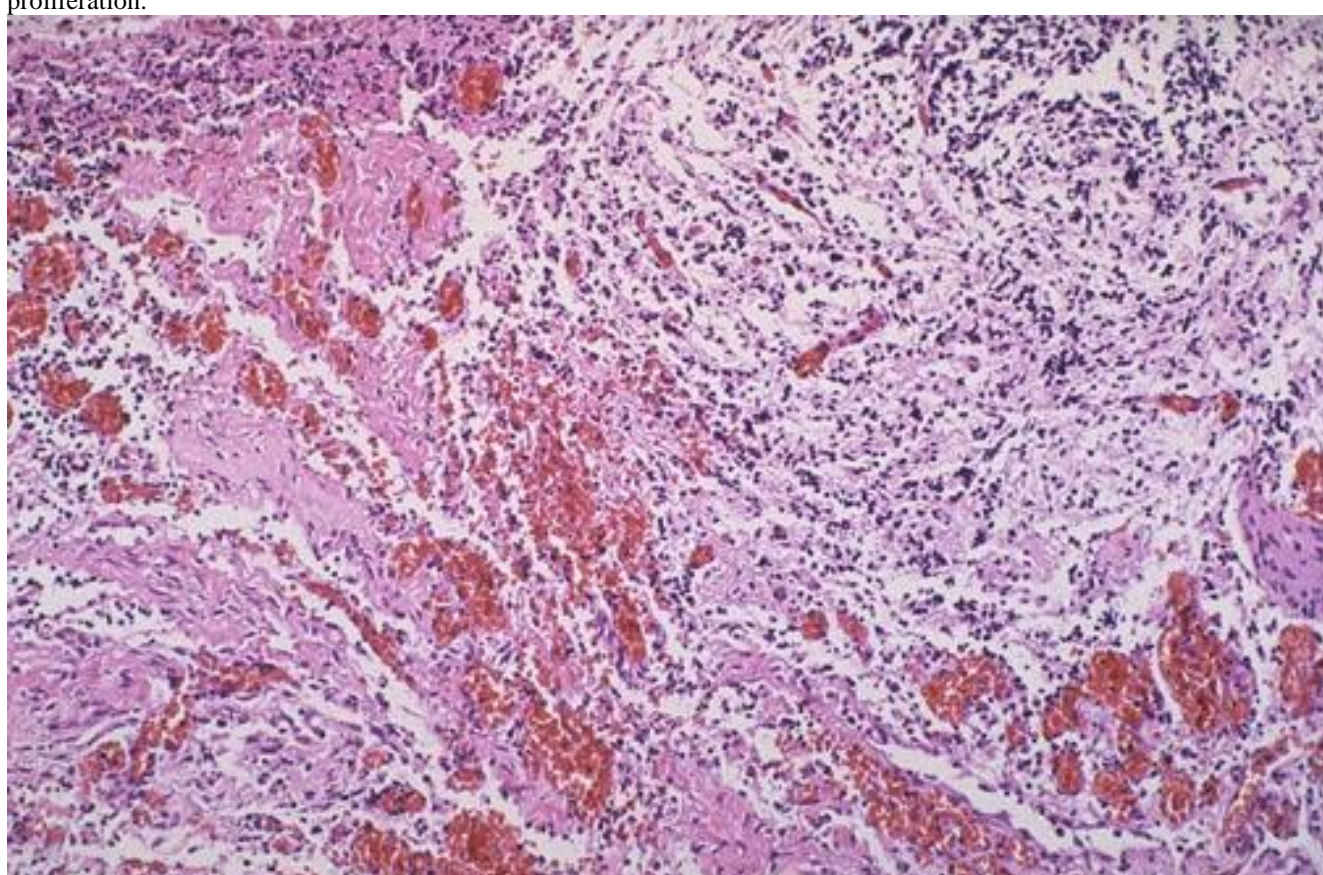
Clinical Signs

- 1) **polyhydramnios**.
- 2) neurological function is limited to **brainstem & spinal reflexes** (seizures, at times resembling infantile spasms, have been observed in some infants).
- 3) significant proportion are **stillborn**; infants who are born alive do not survive (survival can be prolonged with life support systems, creating controversy over use of anencephalic infants as organ donors).



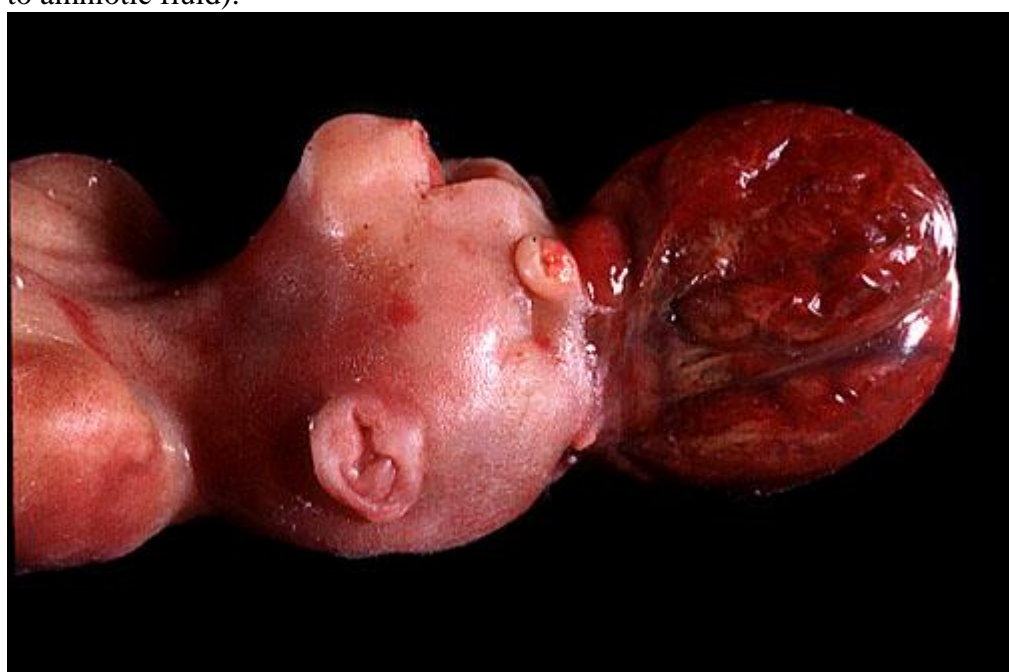Source of pictures: "WebPath - The Internet Pathology Laboratory for Medical Education" (by Edward C. Klatt, MD) >>

"Area cerebrovasculosa" from skull base - scattered primitive neuroglial tissue elements within irregular vascular proliferation:



Source of picture: "WebPath - The Internet Pathology Laboratory for Medical Education" (by Edward C. Klatt, MD) >>

EXENCEPHALY – defect in **calvarium** (dura, bone, skin) – exposed brain (degenerated due to exposure to amniotic fluid):



ENCEPHALOCELES, CRANIAL MENINGOCELES - defect in **skull & dura** (but often intact **epidermal covering**!; vs. anencephaly, myelomeningocele) with protrusion of:

- leptomeninges (CRANIAL MENINGOCELE)**
 - leptomeninges** and underlying **brain tissue (ENCEPHALOCELE)**; neural tissue (cerebral, cerebellar) within encephalocele is often abnormal and ischemic.
 - in few cases portions of **ventricles** are also included - **ENCEPHALOCYSTOCELE**.
- **transillumination** of sac may indicate presence of neural tissue within.

ENCEPHALOCELE

Pathogenetic theories:

- cranial neuropore closure defect**
- correct theory - **mesenchymal defect** → local herniation of fully neurulated neural tissue (at 8-12 weeks of gestation).

Location (usually midline):

OCCIPITAL encephaloceles (85% in **North America**) - often large and have variable contents

- MECKEL-GRUBER syndrome** - rare autosomal recessive condition: occipital encephalocele, microcephaly, microphthalmia, cleft lip / palate, abnormal genitalia, polycystic kidneys, polydactyly.
- WALKER-WARBURG syndrome** - autosomal recessive congenital muscular dystrophy. see p. Mus5 >>

ANTERIOR encephaloceles:

- most common isolated malformation in **southeast Asia**.
- Robert's syndrome

PARIETAL encephaloceles – less common.

SPHENOIDAL encephaloceles – endocrine dysfunction.

Clinical Features

- 1) **protuberant mass** that may be pulsatile; **size** of encephalocele varies: barely visible bulge* ÷ larger than infant's head.

*may resemble cephalhematoma

- 2) **neurological deficits** correlate with extent of *cortex that is herniated* into cele: motor deficits, visual defects, psychomotor developmental delay.
- 3) **malformed cortex** (within / adjacent to cele) → **seizures**.
- 4) frequently associated with *other intracranial abnormalities* (e.g. hydrocephalus!, agenesis of corpus callosum, Dandy-Walker malformations, holoprosencephaly).
- 5) PROGNOSIS is good for many patients.

N.B. encephaloceles that contain large amount of neural tissue have poor prognosis!

NASAL GLIOMA (misleading term - not neoplasm!) - form of **frontonasal encephalocele** with no clear bony defect - may not be immediately obvious on external examination.

- may present as **intranasal mass** (CSF rhinorrhea following removal of nasal polyp), **pharyngeal obstruction**, or recurrent **meningitis**.
- can be associated with **hypertelorism**, **median cleft lip**, **hypothalamic dysfunction**.
- requires immediate imaging and prophylactic antibiotics → surgical repair.

SPINA BIFIDA

- most common form of neural tube defects!
- mostly occurs in **lumbar region**, followed by **lumbosacral region** (can also be located in cervical, thoracic, or sacral regions).
- spinal dysraphism is occasionally associated with *other spinal defects* (tethered spinal cord, spinal lipomas, sacral teratomas).

A. **SPINA BIFIDA OCCULTA** - defect in **vertebral arch** without any other associated defect (i.e. without involvement of cord or meninges; **skin is intact** over malformation).

- most commonly - L₅ & S₁ (up to 24% of population!), C₁, Th₁.
- defect is nearly always narrow and asymmetric.
- **asymptomatic** or subtle clinical signs - **cutaneous markings in midline of back** (mark defect location): **tuft of hair**, cutaneous **angioma** or **lipoma**; rarely, **sinus tract** may communicate from skin to underlying dura.
- no clinical significance* - often found incidentally on radiographic studies.
*occasionally associated with more significant spinal abnormalities (e.g. syringomyelia, diastematomyelia, tethered cord)
- does not seem to increase risk of neural tube malformations in that individual's progeny.

B. **SPINA BIFIDA MANIFESTA (S. APERTA, CYSTICA)** - defect in **vertebral arch** plus:

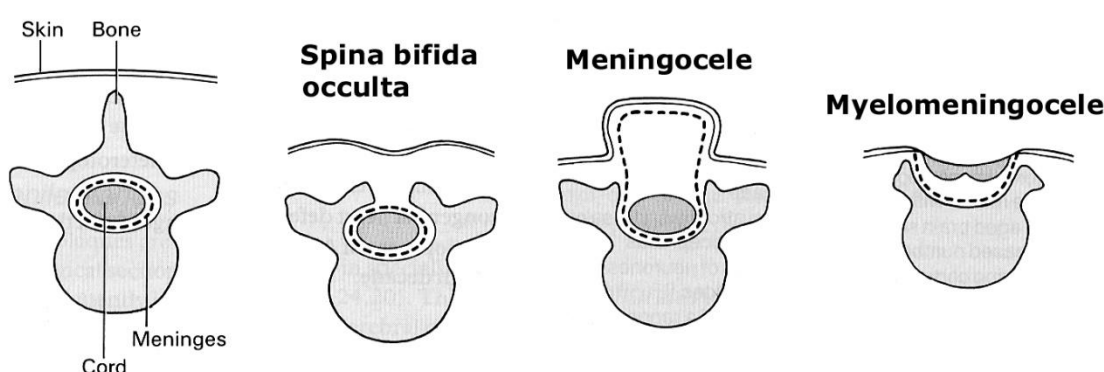
A) **MENINGOCELE** - involves **meninges** alone (i.e. POSTNEURULATION DISORDER - **neural elements** are intact)

- transilluminating protruding / herniating meningeal sac is covered by skin; may be asymptomatic!
- meningocele distends with crying.

ATYPICAL MENINGOCELES (differentiate from dural ectasias in spondyloarthropathies):

- 1) **ANTERIOR SACRAL MENINGOCELE** – presacral cystic mass projecting into pelvis through anterior eccentric defect in sacrum* → constipation, bladder dysfunction, anomalies of female genital tract (e.g. rectovaginal fistula, vaginal septa).
*pathognomonic scimitar [riestas rytietiškas kardas] appearance on plain X-ray
- 2) **INTRASACRAL MENINGOCELE** – sacral canal is expanded by meningocele which lies below normal level of termination of thecal sac.
- 3) **LATERAL THORACIC MENINGOCELE** – intrathoracic posterior mediastinal mass through eroded intervertebral foramen; occurs (70-85%) in association with neurofibromatosis.
- 4) **ANTERIOR THORACIC MENINGOCELE** with ventral spinal cord herniation; midsagittal MRI - spinal cord is displaced sharply forwards in contact with vertebral body at or very near intervertebral disc.

B) **MYELOMENINGOCELE** (most common derangement of neurulation!) - involves **meninges** and underlying **spinal cord**; no **skin** covering over defect.



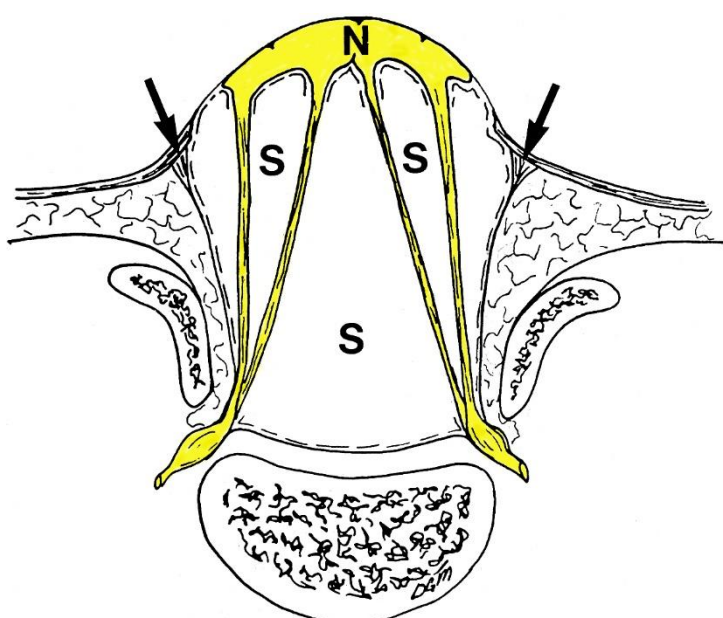
MYELOMENINGOCELE

Greatest disability of spinal dysraphism!

Pathology:

- focal segment of spinal cord fails to roll up and form tube (most commonly - failure of closure of caudal neuropore) - neural folds persist as flat plate of tissue referred to as *neural placode*.
- since neural tube does not fuse, cutaneous ectoderm does not come to cover neural tube (remains attached and lateral to neural plate, leaving cutaneous defect) - raw, exposed dorsal surface of *neural placode* represents tissue that should have formed **interior of spinal cord** (i.e. filleted spinal cord with visibly open central canal).
- CSF exiting from proximally formed central canal floods dorsal surface of placode.
- surrounding *neural placode* is thin layer of skin and arachnoid tissue, below which is subarachnoid space; enlarged **subarachnoid space** ventral to placode results in dorsally protruding sac on which neural placode is visible.
- nerve roots lie inferior to neural placode, with ventral roots lying medial to dorsal roots (i.e. dorsal roots exit from anterior surface of spinal cord just lateral to ventral roots).
- spinal cord is always tethered!

Transverse section through myelomeningocele: arrows demonstrate junction of neural placode (N) with dura mater and skin; subarachnoid space (S):



Source of picture: David C. Sabiston "Sabiston Textbook of Surgery: the Biological Basis of Modern Surgical Practice", 15th ed. (1997); W.B. Saunders Company; ISBN-13: 978-0721658872 >>

Level of defect: thoracolumbar junction (45%) > lumbar (20%) > lumbosacral (20%*) > sacral (10%) > more rostral locations (5%).

*according to Nelson – 75% cases are lumbosacral; according to Grainger – 80-90%

Clinical Features:

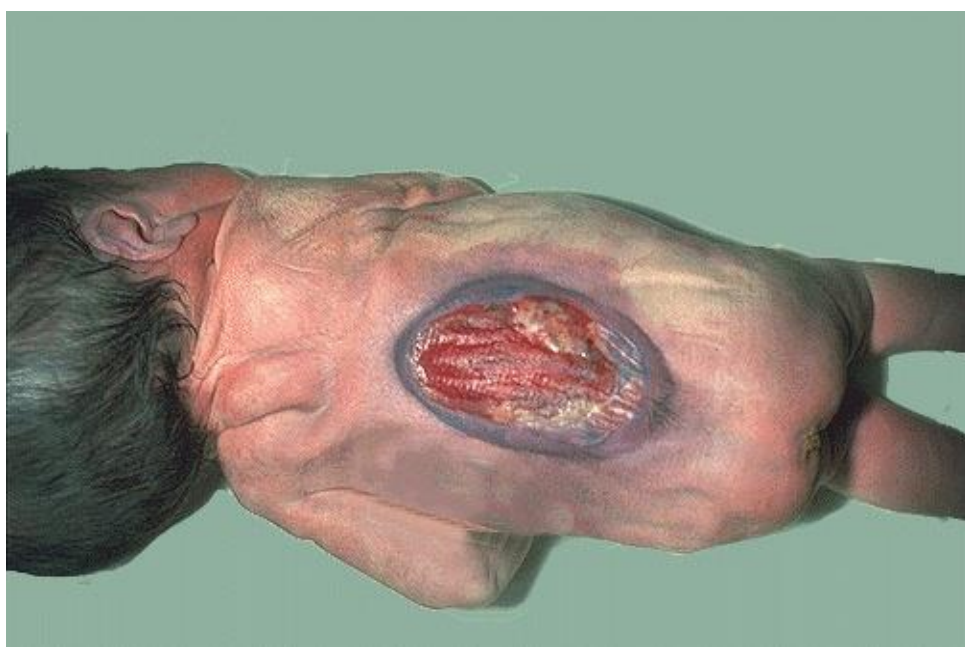1. Saclike **cystic structure** covered by thin layer of partially epithelialized tissue.
 - remnants of neural tissue are visible beneath membrane, which may occasionally rupture and leak CSF.
2. **Spinal cord dysfunction:**
 - 1) **flaccid paralysis & sensory deficits** below level of lesion:
 - defects above L₃ - deficits preclude ambulation (wheelchair dependent);
 - defects between S₁ and L₃ - assisting devices may allow ambulation;
 - defects below S₁ - unaided ambulation.
 - 2) **GU tract involvement** (≈ 90% patients) - constant urinary dribbling, relaxed anal sphincter.
3. Superimposed **infection** (sac rupture → meningitis; UTI)
4. 75% patients have **normal intelligence**.
5. Other defects along neuraxis and surrounding mesoderm:
 - 1) **Chiari II (s. Arnold-Chiari) malformation** – most common (> 95%) finding associated with myelomeningocele! – most common cause of death!
 - 2) **hydrocephalus** (80-95%; esp. with myelomeningoceles in lumbosacral region) - ventricular **outlet obstruction** and **obliteration of posterior fossa subarachnoid cisterns** are likely causes.
 - 3) **LÜCKENSCHÄDEL** (> 50% cases) - regional thinning of cranial bones (radiographic and transilluminative lucencies); rarely found after 2 years of age.
 - 4) **platybasia**.
 - 5) **cerebral hemisphere malformations** - enlarged massa intermedia (frequent finding), agenesis of corpus callosum, polymicrogyria, pachygyria.
 - 6) **diastematomyelia**, diplomyelia.
 - 7) **skeletal deformities** (kyphosis, scoliosis, dislocated hips, clubfeet, Klippel-Feil syndrome) – esp. in defects above L₃ – due to intrauterine paralysis.

N.B. patients with **myelomeningocele in upper thoracic ÷ cervical region** usually have very minimal neurologic deficit and in most cases do not have hydrocephalus!

Late complications of myelomeningoceles:

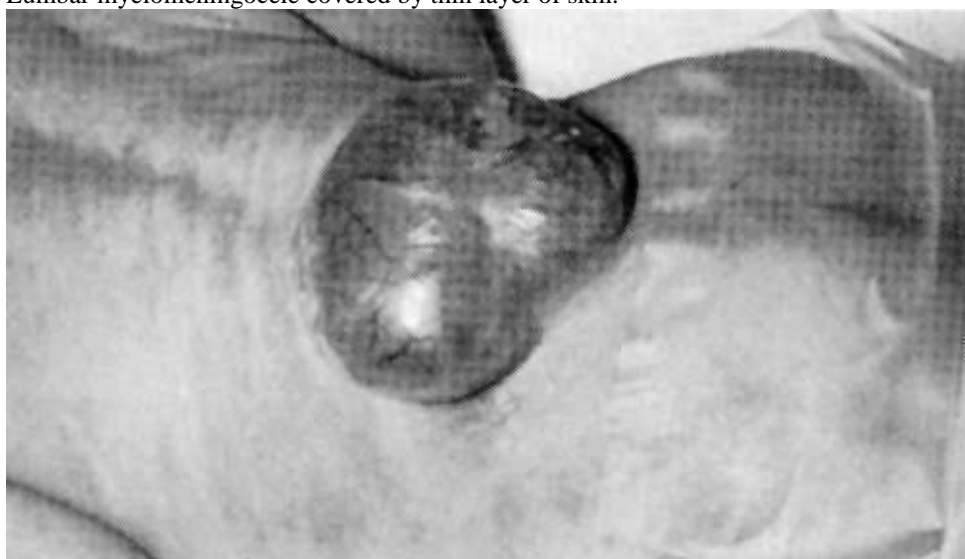1. **Scoliosis** (esp. with lesions above L₃)
2. **Traction on cord**.
3. **Urological complications** - continue to be leading cause of morbidity in myelomeningocele!

Usual causes of death: loss of renal function, shunt complications.

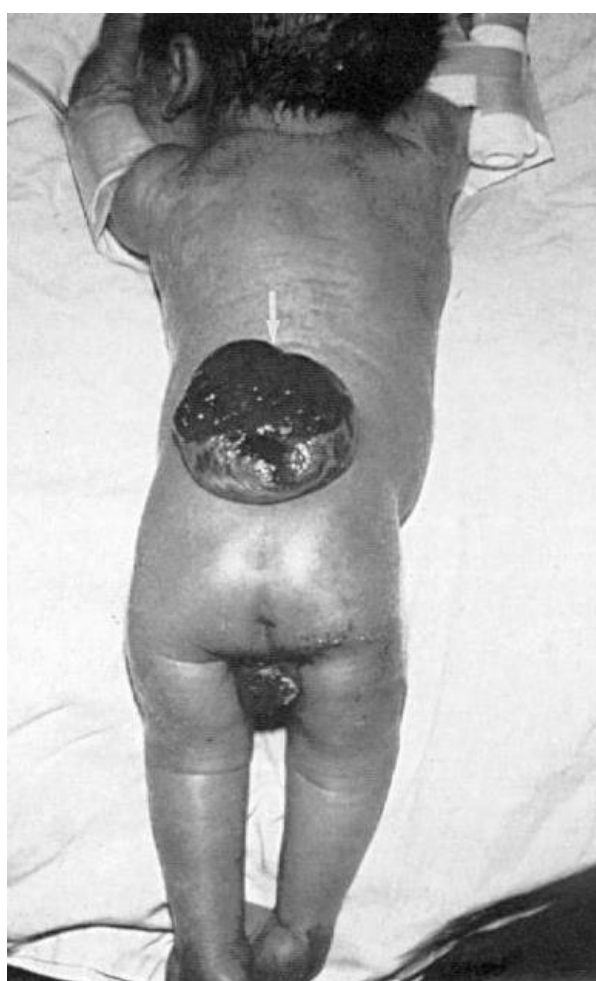


Source of picture: "WebPath - The Internet Pathology Laboratory for Medical Education" (by Edward C. Klatt, MD) >>

Lumbar myelomeningocele covered by thin layer of skin:



Myelomeningocele (arrow); note flaccid anal sphincter and poorly developed lower extremity musculature:



DIAGNOSIS

PRENATAL DIAGNOSIS

- SERUM chemistry** - through routine screening programs: see p. 71-72 (3) >>, p. 2700 >>
 - serum **α -fetoprotein (AFP)** \uparrow - *specificity* is much lower than amniotic fluid; peak of *sensitivity* somewhat later than amniotic fluid (i.e. \approx 16-18 weeks' gestation – normal AFP peak; before that time, levels may be normal).
 - most common causes of *false-positive* AFP \uparrow : incorrect dating of pregnancy, multiple gestation.
 - further course is **detailed (level II) ultrasound** or **amniocentesis**.
- AMNIOTIC FLUID chemistry**:
 - amniotic fluid **α -fetoprotein (AFP)** \uparrow (in almost all **open** neural tube defects, but also in gastroschisis, etc).
 - amniotic fluid **acetylcholinesterase (AChE)** \uparrow (only in almost all **open** neural tube defects).

Amniotic fluid **AFP** \uparrow + amniotic fluid **AChE** \uparrow - sensitivity for open defects \approx 100%
 → **detailed (level II) ultrasound**
- Ultrasound** - very high sensitivity at even 14-16 weeks' gestation.
 - lemon sign** (indirect sign) - symmetrical bifrontal narrowing of skull – risk of neural tube defects.

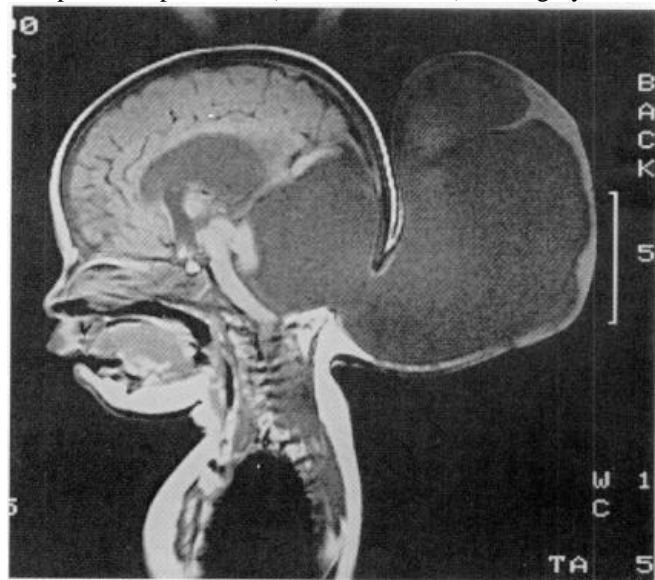
POSTNATAL DIAGNOSIS

- careful **MRI** (!) and **CT**.

ENCEPHALOCELE

- ultrasound** is most helpful in determining contents of sac.

Occipital encephalocele (MRI in newborn); at surgery, sac contained herniated dysplastic cerebellar tissue as well as CSF:



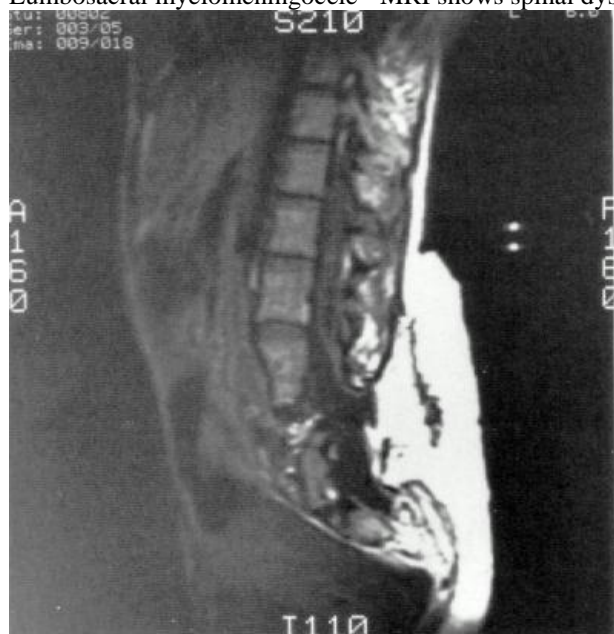
SPINA BIFIDA

- cervical spine** – absence of cortical line on anterior surface of spinous process (on lateral and AP X-ray).
- lumbosacral spine** – defect best seen on AP X-ray.

MYELOMENINGOCELE

- imaging is not necessary preoperatively – diagnosis is obvious clinically.
- do not overlook *Chiari II, tethered spinal cord*.
- every child must be screened for *hydrocephalus* (daily *occipital-frontal circumference* measurements and baseline **transfontanellar ultrasound**).
- orthopedic & urological assessment**.

Lumbosacral myelomeningocele - MRI shows spinal dysraphism and tethered cord:



MENINGOCELE

- US - subcutaneous cystic mass in continuity with spinal canal through bone defect.

MANAGEMENT

Prevention of meningitis / ventriculitis is extremely important (intellectual outcome is inversely related to occurrence of such complications) - **antibiotic prophylaxis** before and around time of surgery (esp. with open defects).

Atraumatic delivery (damaged CNS is more vulnerable to perinatal insults)

- prelabor **Cesarian section** significantly improves neurological outcome in large encephaloceles, myelomeningocele.

ENCEPHALOCELES

Surgical management – as early as clinical conditions permit:

1. Encephalocele contents:
 - a) **relocation** into cranium
 - b) **resection**
2. Watertight **dural closure**
3. **Bone grafting** to cover calvarial defect (usually at later operation).

- indicated in most situations (exceptions – very small defects*, large defects with associated microcephaly) even if there are significant associated malformations**

*may decrease with time

**goal of surgery here - to simply improve caregiving for such infant.

- CSF leak → urgent surgery within 12-24 hours (to prevent meningitis).
- surgical PROGNOSIS is best in sporadic **frontal encephaloceles**; **occipital encephaloceles** are more commonly associated with hydrocephalus → worse cognitive outcome.

MYELOMENINGOCELE

- child is kept **prone** or in **lateral** recumbent position.
- defect is covered with **warm saline-moistened nonadherent dressing** (e.g. Telfa - to prevent injury and desiccation of neural placode).
- **antibiotics** (**NAFCILLIN** + **GENTAMICIN**), esp. if defect is leaking CSF; continue until clear that shunt is not needed.
- HUS then daily HC.
- genitourinary system evaluation.

Surgical management - **closing** all but prognostically worst cases. see p. Op250 >>

Conservative management

- **urological management** plays prominent role:
 - regularly catheterize neurogenic bladder - avoid secondary dilatation of proximal urinary system → pyelonephritis, hydronephrosis.
 - periodic urine cultures, assessment of renal function, renal imaging.
 - some can become continent with implantation of artificial urinary sphincter at later age.
- **incontinence of fecal matter** is common and socially unacceptable (but does not pose same risks as urinary incontinence); many children can be "bowel-trained" with timed enemas or suppositories that allows evacuation at predetermined time once or twice day.
- **ambulatory aids, orthopedic care.**

MENINGOCELE

Surgical repair – for cosmetic reasons: amputation of herniating sac, and closing dura; remainder of wound is closed in layers.

- prior to surgery, patient must be thoroughly imaged (MRI) for neural tissue involvement, if any, and associated anomalies.
- if CSF is leaking → immediate surgery (to prevent meningitis).

PROGNOSIS

Recurrence rate for neural tube defect in subsequent pregnancy ≈ 3-5%*; raises to 7-10% after two previous abnormal pregnancies

*it is general recurrence risk for *multifactorial disorders*

MORTALITY RATE:

myelomeningocele (treated aggressively) ≈ 10-15% (most deaths occur before 4 yrs).

PROPHYLAXIS

1. **Folate supplementation** 4 mg/day before conception* and during early pregnancy (until 12th week).

*general diet fortification with folate in case of unplanned pregnancy

- esp. for women who have had infant / fetus with neural tube defect.
- folate mechanisms are poorly understood.

U.S. Public Health Service 1992 recommendation:

- 1) all women of childbearing age capable of becoming pregnant must take **0.4 mg folate** daily (dose should not exceed 1.0 mg/d to avoid secondary vit. B₁₂ deficiency).

- 2) women who had pregnancy with in neural tube defect must take **4 mg folate** daily (beginning 1 month prior to time pregnancy is planned).
2. **Avoid heat exposure** (esp. hot tub).
3. **Change VALPROATE** to another anticonvulsant.

BIBLIOGRAPHY for ch. "Developmental Anomalies" → follow this [LINK >>](#)