

Refractive Errors

Last updated: September 5, 2017

TYPES	1
CONTACT LENSES	1
INDICATIONS	1
SIDE EFFECTS, COMPLICATIONS.....	1
CONTRAINDICATIONS.....	3
TYPES	3
REFRACTIVE SURGERY.....	3

TYPES

EMMETROPIA - normal refractive system (light rays focus clearly on retina → sharp image perceived by brain).

AMETROPIA - refractive system defects:

1. **Hyperopia (farsightedness)** - images of **DISTANT** and **NEAR** objects are focused behind retina:

- too short axis of eyeball
 - too weak refractive power (too flat cornea)
- most common refractive error.
 - sustained accommodation** (even when viewing distant objects!) causes tiring prolonged eye strain (headaches, blurring of vision); prolonged convergence of visual axes (associated with accommodation) may lead eventually to strabismus.
 - convex (plus)** corrective lens is used.

PRESBYOPIA - progressive, age-related loss of accommodative amplitude → physiologic hyperopia.

- primary factors in presbyopia are **lens hardening** (lens gradually grows less pliable and eventually cannot change shape – HELMHOLTZ theory) and **loss of ciliary muscle motility** (SCHACHAR theory).
- begins in adolescence.
- prevalence 100% among people > 50 yrs.
- no need for corrective glasses until *early to mid-40s*.
- no universally accepted treatments or cures are currently available for presbyopia.

2. **Myopia (nearsightedness)** - image of **DISTANT** object is focused in front of retina:

- too long axis of eyeball
 - too strong refractive power (too steep cornea)
- concave (minus)** corrective lens is used.
 - myopia is genetic in origin; however, eye shape during development is determined in part by refraction presented to it (e.g. in young adults extensive close work accelerates myopia development).
 - 1/4 of world's population is myopic!
 - myopia starts at age ≈ 6 yrs., then progresses (due to increase of eyeball AP diameter) and stabilizes at late teens (in later life increasing myopia may indicate developing cataracts).

Astigmatism - unequal refraction in different meridians of eyeball → distorted retinal image (e.g. point is seen as line):

- unequal curvature of cornea.
 - unequal curvature of lens.
 - lens dislocation
- cylindric** corrective lens is used (has no refractive power along one axis and is concave or convex along other axis).
 - TORIC lens** - both meridians are curved but not to the same degree.

Anisometropia (vs. **isometropia**) - significant (usually > 2 diopters) difference between refractive errors of two eyes.

- if refractive errors are corrected with lenses, differences in image size (**ANISEIKONIA**) are produced → difficulties in fusion → suppression of one image (amblyopia).

REFRACTION - act of determining refractive errors and correction by lenses:

static (cycloplegic) refraction – refraction without accommodation.

dynamic (manifest) refraction - refraction during accommodation.

Ametropia can be corrected by 3 different means:

- Optical devices** (glasses, contact lenses)
- Corneal refractive procedures** - cannot take care of high refractive errors.
- Intraocular procedures** (clear lens extraction ± lens implantation; phakic intraocular lens implants)

CONTACT LENSES

- provide better visual acuity & peripheral vision than do eyeglasses.

INDICATIONS

- MYOPIA** (contact lenses don't increase or decrease amount of myopia), esp. > -12.0 D
- HYPEROPIA**, esp. > +10.0 D (incl. **APHAKIA**); **PRESBYOPIA** can also be corrected:
 - nondominant eye is corrected for reading and dominant eye for distant vision (**monovision**).
 - bifocal** and **multifocal** contact lenses (fitting procedure is time-consuming - precise alignment is essential!).
- ASTIGMATISM** (**toric** lenses are used but require expertise for fitting)
- ANISOMETROPIA**, aniseikonia
- CORNEAL DISORDERS** (keratoconus, bullous keratopathy, etc) - soft contact lenses (**bandage** lenses) ± prophylactic antibiotic eyedrops.
- OCCCLUSION THERAPY FOR AMBLYOPIA** - soft contact lenses (well-tolerated in children).

SIDE EFFECTS, COMPLICATIONS

(rate of complications ≈ 5% per year).

All eyes are altered by contact lens wear!!!

N.B. poor contact lens hygiene may lead to hard-to-reverse inflammatory conditions!

- causes of **discomfort**:
 - poorly fitting lenses
 - changes in lens / corneal parameters (swelling of tissues)
 - harmful (e.g. oxygen-poor, smoky, windy) environment
 - improper inserting / removing lenses

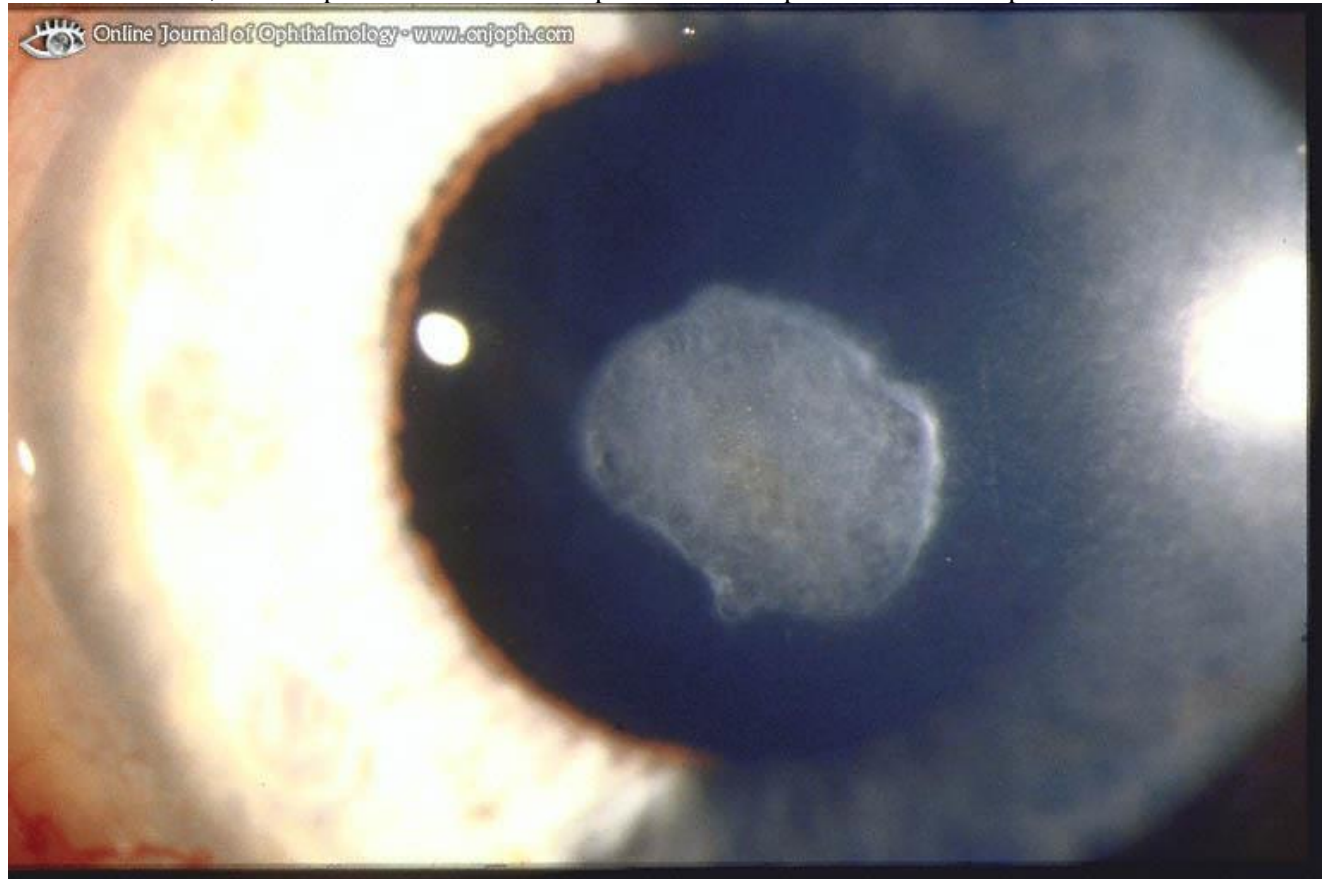
- e) trapped small foreign particles (e.g. soot, dust)
- f) removing lenses after prolonged use (**OVERWEAR SYNDROME**); spontaneous healing may occur in day or so if lenses are not worn (in some cases, treatment is required - pupil dilation to prevent posterior iris synechiae, topical antibiotic, sometimes sedation).

No pain should be present at any time; pain is sign of ill-fitting contact lens or corneal irritation!

Cornea

- corneal epithelium defects can be caused **mechanically** or **chemically** (H: preservative-free hydrogen peroxide based disinfection systems).
- 1) **SUPERFICIAL CHANGES** (painless)
 - 2) **ABRASIONS** (pain, photophobia, anxiety) - indicate chronic epithelial stress; can allow bacteria to penetrate cornea
 - 3) **ULCERS & SCARS**

non-vascularized, dense superficial scar indicates problems with epithelial defects in past contact lens wear:

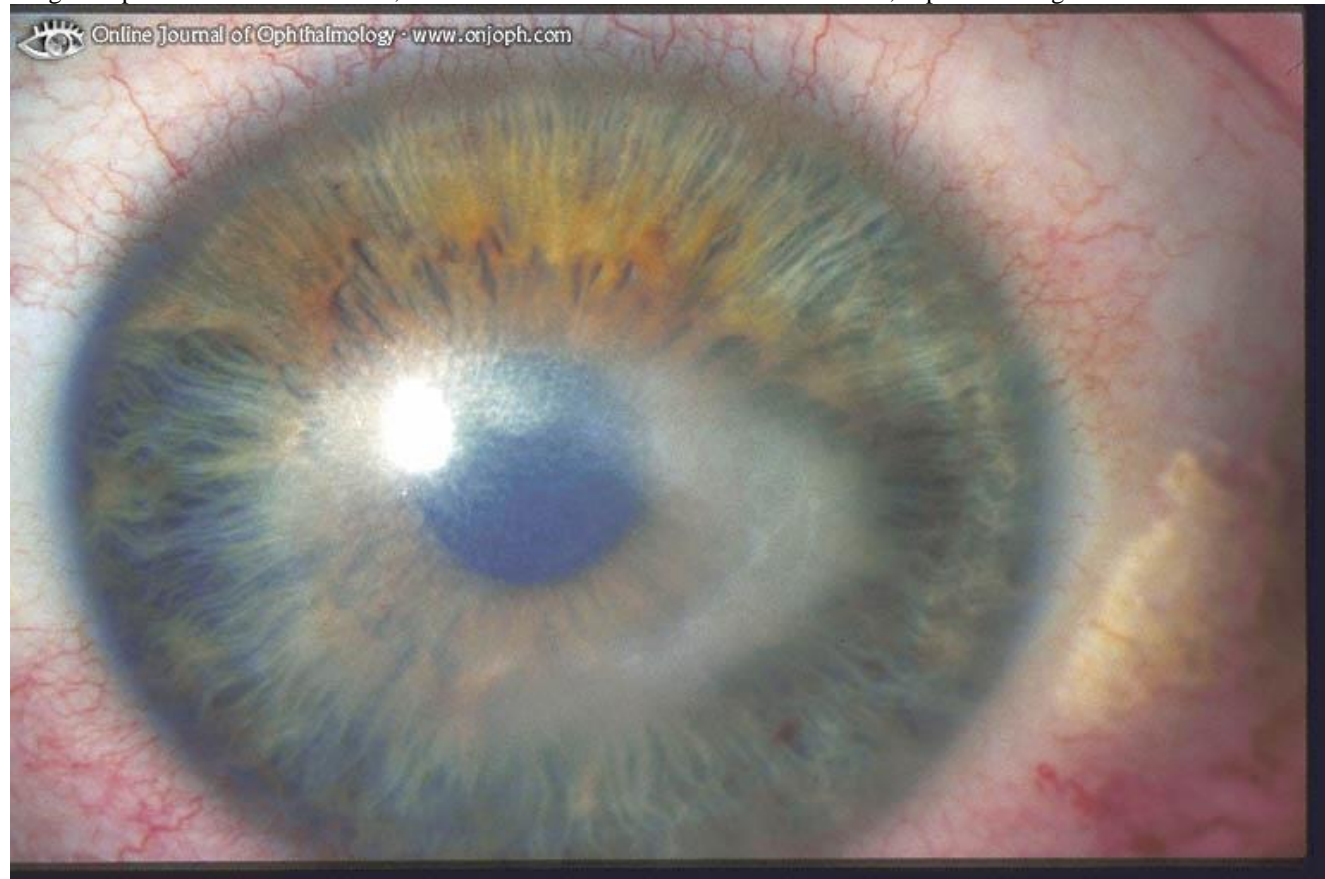

Source of picture: "Online Journal of Ophthalmology" >>

- 4) **sterile corneal stroma INFILTRATES** (immune-mediated reaction to bacterial toxins from colonized contact lenses).
- 5) **BACTERIAL KERATITIS**
 - pathogens - *Pseudomonas aeruginosa* [can penetrate intact epithelium!], staphylococci.
 - predisposing pathophysiologic factors:
 - corneal epithelium is thinner less sensitive, hypoxic in contact lens wearers;
 - contact lens is barrier between epithelial surface and lid (preventing wiping action of lid and tear exchange);
 - contact lens mechanically damages epithelial barrier.

N.B. primary risk factor is **sleeping with lenses!**
- 6) **ACANTHAMOEBA KERATITIS** - *Acanthamoeba castellanii* [found widely in nature; most common source – tap water!].
 - insidious; very painful; after 6 weeks irreversible ring infiltrates form;
 - diagnosis: *Acanthamoeba* feed on bacteria (corneal scrapings are placed on *E coli*-layered agar - inspected for characteristic tracks that trophozoites make as they eat their way across dish), Giemsa and calcofluor white stains on corneal scrapings.

Irregular epithelium without defects, localized stromal edema with minor infiltrate, superficial ring-infiltrate:

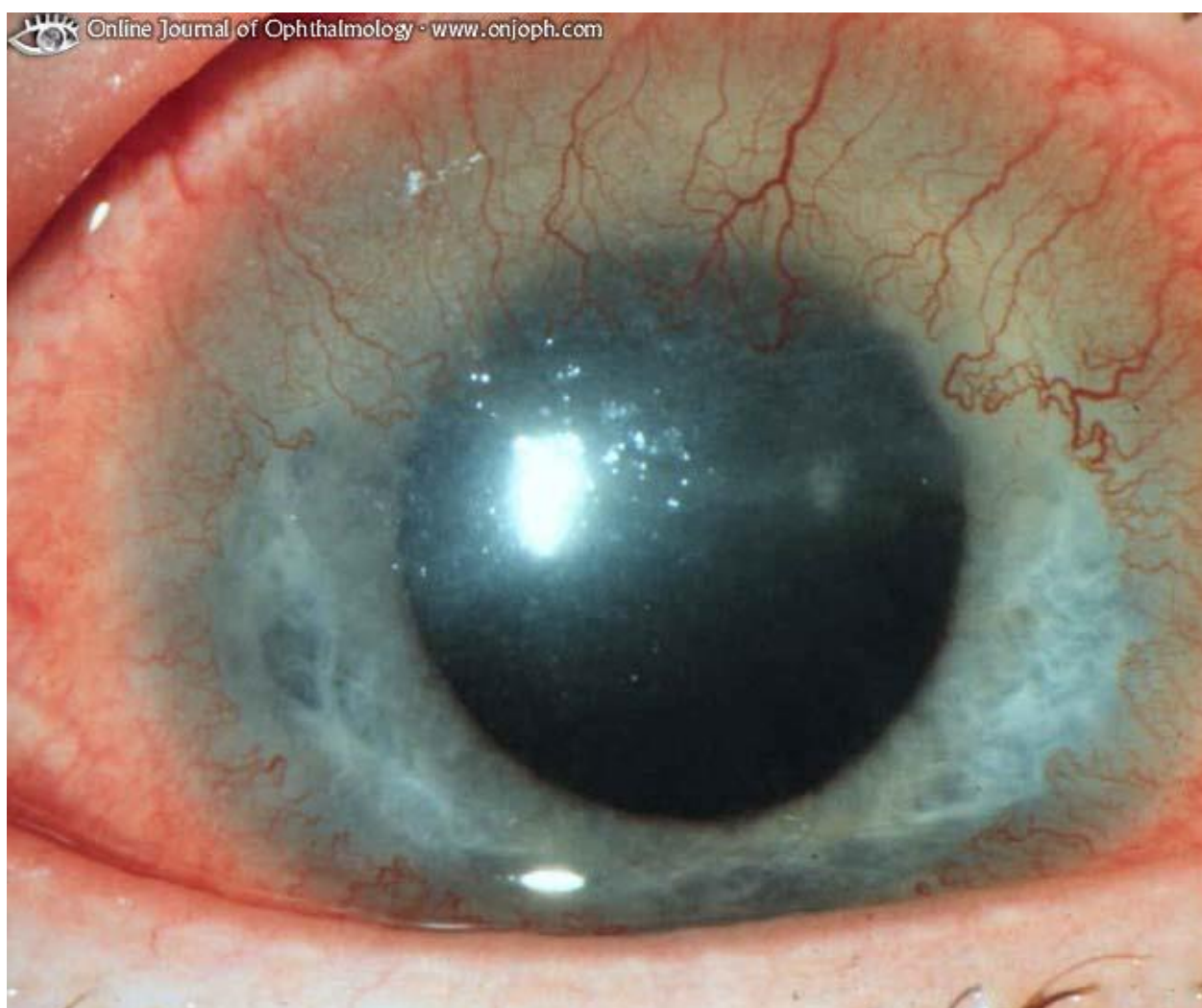


Source of picture: "Online Journal of Ophthalmology" >>

- treatment:
 - traditional** – propamidine + neomycin + oral miconazole / clotrimazole / ketoconazole.
 - modern** - **PHMB (POLYHEXAMETHYLENE BIGUANIDE)** every 1-2 hours until clinical improvement → reduced gradually to 4 times a day; treatment continued for number of months.
- 7) lens wear (esp. with closed lid during sleep) can cause corneal epithelial **HYPOXIA**:
 - acute mild hypoxia* → **epithelial edema** (temporary blurred vision);
 - acute severe hypoxia* → **epithelial cell death** and desquamation.
 - chronic hypoxia* → **epithelial microcysts, superficial neovascularization** (esp. along superior limbus).

H: thinner lenses with greater O₂ permeability, greater lens movement, decreasing wear time.

Superficial neovascularization between Bowman lamella and corneal epithelium:



Source of picture: "Online Journal of Ophthalmology" >>

- 8) prolonged lens (esp. hard lenses) wear may produce gradual unpredictable irregular astigmatism (**CORNEAL WARPAGE**); it may take weeks or even months to regain regular shape after discontinuation of contact lenses.
- 9) long-term wear of contact lenses can produce **KERATOCONUS** in susceptible individuals.

Conjunctiva

- 1) **GIANT PAPILLARY CONJUNCTIVITIS** (1-3%) - conjunctival injection, mucoid discharge, itching, tear film debris, coated lenses, excess lens movement, blurred vision; tarsal conjunctiva inflamed and hypertrophied (morphologically similar to papillary hypertrophy of vernal conjunctivitis);
 - pathophysiology: deposits on lens surface → constant blinking lid rubbing on lens surface exposes allergenic deposits to conjunctival lymphatic system.
 - most commonly associated with *soft contact lenses*.
 - treatment - frequent enzymatic lens cleaning, disposable lenses, reduction in wearing time, topical steroids, topical mast cell stabilizers (e.g. 4% cromolyn).
- 2) **CONTACT LENS-INDUCED SUPERIOR LIMBIC KERATOCONJUNCTIVITIS** - immunologic reaction in peripheral conjunctiva; causes - excessive lens movement or sensitivity to preservative thimerosal (rarely used today).
- 3) **CONTACT LENS "LOSS"** into superior fornix (may erode into lid tissues).

CONTRAINDICATIONS

Contact lenses ARE NOT RECOMMENDED:

1. Eyes susceptible to infections
2. Severely dry eyes
3. Anesthetic corneas
4. Hand tremor, arthritis
5. Insufficiently motivated to tolerate temporary discomfort that may occur while adapting to lenses.

Lenses should not be worn if eyes *inflamed / infected*, during *sleep*, when *swimming*.

TYPES

RIGID CONTACT LENSES

- simpler and less time-consuming to care.

- a) older **hard contact lenses** – made of polymethyl methacrylate (PMMA); rarely prescribed today.
- b) modern **gas-permeable contact lenses (GPCL)** - made of fluorocarbon and polymethyl methacrylate admixtures.

- diameter 6.5-10 mm - *cover part of cornea*, floating on tear layer.
- when corneal surface is irregular, rigid lenses provide smooth refracting surface.
- **adaptation period** may be as long as a week - wearer gradually increases daily number of hours lenses are worn.
- **SPECTACLE BLUR** - temporary (< 2 h) vision blurring when wearing eyeglasses after removing contact lenses.

SOFT HYDROPHILIC CONTACT LENSES

- require special care and handling.

- made of poly-2-hydroxyethyl methacrylate.
- hydrophilic:
 - brittle when dry and break easily.
 - do not use solutions for rigid contact lenses.
- 13-15 mm in diameter:
 - *cover entire cornea*;
 - are not likely to eject spontaneously;
 - foreign bodies are less likely to lodge underneath them;
 - easier for elderly persons to handle.
- **brief or no adaptation period** is necessary (wearing comfort usually is immediate).
- **do not damage eye** (even when eye is closed for short periods) - better for patients who may *become unconscious* (e.g. epileptics, diabetics - such patients should carry emergency card or bracelet that identifies them contact lens wearers).
- most therapeutic **eyedrops can be used** with soft lenses!
- **astigmatism cannot be treated** (soft lens molds to corneal curvature), unless special toric lens is used.

REFRACTIVE SURGERY

- alters corneal curvature → eliminates / decreases one's dependence on glasses or contact lenses.

- in general, it is outpatient procedure under topical anesthesia.

REQUIREMENTS for candidates:

- 1) realistic **patient motivation** (although surgery risks are low, they do exist!)
- 2) **healthy eyes**
- 3) **refraction stable** for ≥ 1 yr.
- 4) **> 18-21 yrs** of age (stable refraction).

CONTRAINDICATIONS:

1. **Pathologic myopia** (subnormal corrected acuity).
2. History of **autoimmune / collagen vascular disease** (potential problems with wound healing).
3. Tendency to form **keloids** (haze formation in cornea).
4. **Latent herpes simplex virus** (may reactivate after surgery).
5. **Pregnancy or breastfeeding**
6. Use of following **medications**: isotretinoin, amiodarone, sumatriptan.

PREOPERATIVE TESTS

- contact lens wear should be discontinued prior to examination (3 days for soft lenses; 2 weeks for rigid gas permeable lenses).
- **cycloplegic refraction** is basis for calculating surgical plan and for comparing preoperative and postoperative results.
- **slit lamp** – to exclude pathologic myopia, early keratoconus, corneal scars, mild lens opacities, etc.
- **tonometry** (only pressures 10-20 mmHg are acceptable for surgery).
- preoperative ultrasound **PACHYMETRY** (accurate measurement of corneal thickness) is necessary; N.B. leaving at least 250 μm of cornea untouched is recommended! [average corneal thickness is 500 μm centrally and 700 μm peripherally]
- **CENTRAL KERATOMETRY** (measure of central cornea curvature) - plays little role in designing surgical plan.
- corneal **TOPOGRAPHY** (s. qualitative **KERATOGRAPHY**) - measuring corneal shape and curvature (to rule out keratoconus and irregular astigmatism).

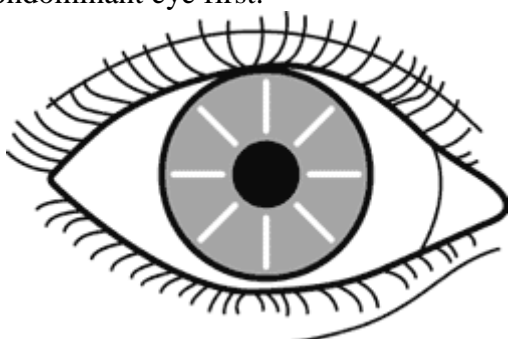
SIDE EFFECTS - temporary foreign-body sensation, glare, halos.

COMPLICATIONS (rate is very low):

- 1) corneal perforation
- 2) over- and undercorrection
- 3) infection (very rare)
- 4) irregular astigmatism
- 5) haze formation (in excimer laser procedures).

Postoperative cornea is permanently weaker, which increases its risk of rupture from direct trauma!

RADIAL KERATOTOMY

- rarely performed today.
 - **indication** - low to moderate **myopia** (from 1.5 to 6.0 D)
 - can be performed on both eyes on same day, but some ophthalmologists wait at least 1 wk between procedures; many surgeons prefer to operate on patient's nondominant eye first.
 - up to eight incisions (using guarded diamond blade) in radial pattern in peripheral cornea.
 - incision length depends on patient age and myopia degree.
 - incision depth is based on corneal thickness.
 - relaxation, or steepening, occurs at incision site \rightarrow flattening of central uncut tissue.
- 
- results are immediate; $> 90\%$ achieve vision 20/40 or better.
 - 25-30% need **ENHANCEMENT PROCEDURE** - fine-tuning of initial surgery (existing incisions are lengthened / deepened).

ASTIGMATIC KERATOTOMY

- **indication** – **astigmatism**.
- two arcuate incisions placed 180° apart along steep axis using diamond blade:

PHOTOREFRACTIVE KERATECTOMY

- **indication**:
 - 1) low to moderate (1.0-6.0 D) **myopia** (can safely treat higher degrees of myopia than can radial keratotomy!)
 - 2) **hyperopia**
 - 3) **astigmatism**
- **EXCIMER LASER** flattens central corneal tissue through **photoablation**.
 - excimer laser uses photons in UV spectrum (created by argon fluoride gas mixture) - breaks intermolecular bonds with submicron precision;
 - each laser pulse removes 0.25 μ of corneal tissue;
 - corneal epithelium is removed before photoablation and takes 3 days to regenerate.
 - *topical antibiotics* are used with *therapeutic contact lens* until reepithelialization is complete.
 - risk of central haze formation.

LASER IN SITU KERATOMILEUSIS (LASIK)

- **hinged lamellar corneal flap** is created with microkeratome \rightarrow flap is turned back \rightarrow stromal bed is sculpted with **EXCIMER LASER** \rightarrow flap is repositioned and adheres tightly to stromal bed (suturing or bandage contact lens are not necessary).
 - i.e. LASIK is photorefractive keratectomy performed under flap instead of on corneal surface
- surface epithelium is not disrupted centrally:
 - visual recovery is rapid, minimal postoperative pain.
 - no healing response (\downarrow risk of central haze formation).
 - **larger range of refractive errors** can be treated than with other surgical methodologies - up to 14.0 D myopia, up to 6.0 D hyperopia, up to 5.0 D astigmatism!!!
- most today surgeons offer their patients option of **bilateral** surgery.
- in **myopia** treatment, *central* cornea is carved, in **hyperopia** treatment – *peripheral* cornea.
- up to 6 months postoperatively corneal flap can be raised easily – allowing **ENHANCEMENT PROCEDURE** (if necessary).

Most modern modification - **wavefront-guided LASIK**:

- adds measurement of more subtle corneal distortions (called higher-order aberrations).
- based on technology that helps astronomers see twinkling stars more clearly, they send waves of light into eye and measure how they bounce back, forming 3-D map of each person's unique wave patterns.
- can remove $\approx 10\%$ more tissue than regular LASIK does.

INTRACORNEAL RINGS

- indication – mild-to-moderate **myopia**.
- implantation of transparent polymethyl methacrylate (PMMA) **RING** in *peripheral corneal stroma* → anterior corneal curvature is changed by using rings of different thicknesses.
Central optical zone is not disturbed!!! Removable and exchangeable!!!
- inserted through peripheral radial incision made with diamond knife at two-thirds corneal depth.
- 360° peripheral intrastromal channel is created with specially designed instruments.
- incision is closed with 1 or 2 interrupted 11-0 nylon sutures.
- disadvantage – ≥ 1 D astigmatism is induced in 20% eyes.
- *recent design modification* – implantation of **RING SEGMENTS (“Intacs” inserts)** - ring split into two 150° arcs - simplified implantation procedure.

CLEAR LENS EXTRACTION (S. REFRACTIVE LENS EXCHANGE)

- *removal of noncataractous natural lens* \pm intraocular lens placement.

- reserved for **high myopia** (> 8 D) or **high hyperopia** (> 4 D); toric IOLs are now available for **astigmatism** correction.
- accommodative IOLs are available!!! - can become number one refractive procedure!

PHAKIC INTRAOCULAR LENS IMPLANTS

- a) **angle-supported** (i.e. in anterior chamber)
- b) **iris-fixated** (i.e. in pupil plane) - fixed to anterior iris surface independent of pupil.
- c) **precrystalline** (i.e. in posterior chamber)

CONDUCTIVE KERATOPLASTY

- controlled-release of high *radiofrequency energy* delivered with thin metal tip in concentric rings of multiple spots around corneal periphery → collagen shrinking → steepening central cornea.

- indication – **hyperopia** (up to +3.25 D).
- procedure is painless and typically requires ≈ 5 min to perform.
- vision begins to improve within week's time.

BIBLIOGRAPHY for ch. “Ophthalmology” → follow this [LINK >>](#)