

Dermoid, Epidermoid, Cysts, Lipoma

Last updated: April 12, 2020

NEURENTERIC CYST	1
DERMOID TUMOR, EPIDERMOID TUMOR	2
EPIDERMOID CYSTS (FROM WHO MANUAL).....	4
DERMOID CYSTS (FROM WHO MANUAL).....	5
COLLOID CYSTS.....	6
ARACHNOID CYSTS.....	8
LIPOMA	9
MUCOCELE	9

Same tumors in the spine – see p. Onc54 >>

EPIDERMOID, DERMOID, RATHKE CLEFT CYST, COLLOID CYST, AND NEURENTERIC CYSTS

- benign dysraphic malformations (dysembryogenesis) at **GASTRULATION stage*** of development
 *traditionally, such disorders have been described as primary failure of NEURULATION (later stage in embryogenesis than gastrulation)

- primary disruption of tissues derived from one or more of three germ cell layers:
 DERMOID AND EPIDERMOID CYSTS, DERMAL SINUS TRACTS – **surface ectoderm** malformation.
 NEURENTERIC CYSTS, RATHKE CLEFT CYSTS, COLLOID CYSTS – all the same just different location – **endodermal** malformation.
- frequently associated with **mesodermal** malformations (esp. vertebrae - hemivertebrae, absent vertebrae, fused vertebrae, butterfly vertebrae, midline bony spurs).
- can manifest in patients of any age.
- clinically** onset is usually **insidious**; occasionally **cyst rupture and spillage of irritative contents** into subarachnoid space → acute meningitic complaints or increased ICP.
- treatment** of each of these entities is primarily **surgical**; radiotherapy and chemotherapy have little to offer.

NEURENTERIC CYST

(s. enterogenous cysts, neuroepithelial cysts, gastrocytomas, foregut cysts)

Neurenteric canal – normal embryologic transitory communication between **neural tube ECTODERM**, **NOTOCHORDAL canal**, and **gut ENDODERM**; canal persistence → paravertebral neurenteric cyst(s) or fistula(s).

- by third embryonic week, this neurenteric canal closes, and notochord separates from primitive gut.
- develop as early as embryonic day 16-17 - part of split notochord syndrome or split cord malformation.
- no definite sex predilection (spinal neurenteric cysts more often in males, whereas 60% of intracranial cysts have been reported in females).
- 0.7-1.3% of all spinal cord tumors.
- spinal neurenteric cysts are almost pathognomonically associated with vertebral anomalies or diastematomyelia.
- 5% of patients with Klippel-Feil syndrome and vertebral fusion abnormalities may have neurenteric cysts and fistulas.

PATHOLOGY

- benign slow-growing cysts

- location** (intra and extra axial):
 - Most commonly - **spinal canal** (particularly in low cervical or high thoracic region); can be found both ventral and dorsal to spinal cord, as well as in intramedullary location
 - Intracranial** (most often **posterior fossa** - pontomedullary region, cerebellopontine angle, parasellar area, and craniocervical junction)
 N.B. most are **VENTRAL** and **EXTRA-AXIAL**
- cyst wall** is composed of well-differentiated cuboidal, columnar, or ciliated epithelium, with or without goblet cells or microvilli; **mucin-containing cells show positive reaction with periodic acid-Schiff stain** and are seen in 75% to 80% of specimens
- epithelium** may resemble intestinal or respiratory type, and there may be smooth muscle in underlying fibrovascular tissue.
- cyst fluid** - clear and colorless, milky, yellowish, gelatinous, xanthochromic, and blackish and viscous.
- immunohistochemical** staining - positive for cytokeratin and epithelial membrane antigen and negative for vimentin, glial fibrillary acidic protein, and S-100
- cells also often test positive for carcinoembryonic antigen (CEA).
- differentiate between neurenteric* and ependymal cysts.
 *presence of underlying basement membrane or collagenous tissue separating epithelial layer from neuroglial tissue + lack of immunoreactivity to GFAP, S-100, neuron-specific enolase, and vimentin.
- malignant transformation** is rare.

CLINICAL FINDINGS

- slow and insidious compression of adjacent spinal cord
- persistent fistulas (between enteric structures and these cysts within CNS) → **recurrent aseptic meningitis**.

IMAGING

Differential - from simple arachnoid cysts to complex teratomas.

MRI - variable and heterogeneous cyst signal (often parallel signal intensity of CSF), no enhancement (some variable wall enhancement may be present)

- reports of T1 signal changes in these tumors, resulting from changes in protein concentration or hemorrhage.
- cysts have tendency to insinuate themselves between surrounding structures.

A, T1-MRI - hypointense suprasellar mass.

B, Hypointense midline suprasellar lesion.

C, T1-MRI - cystic lesion.

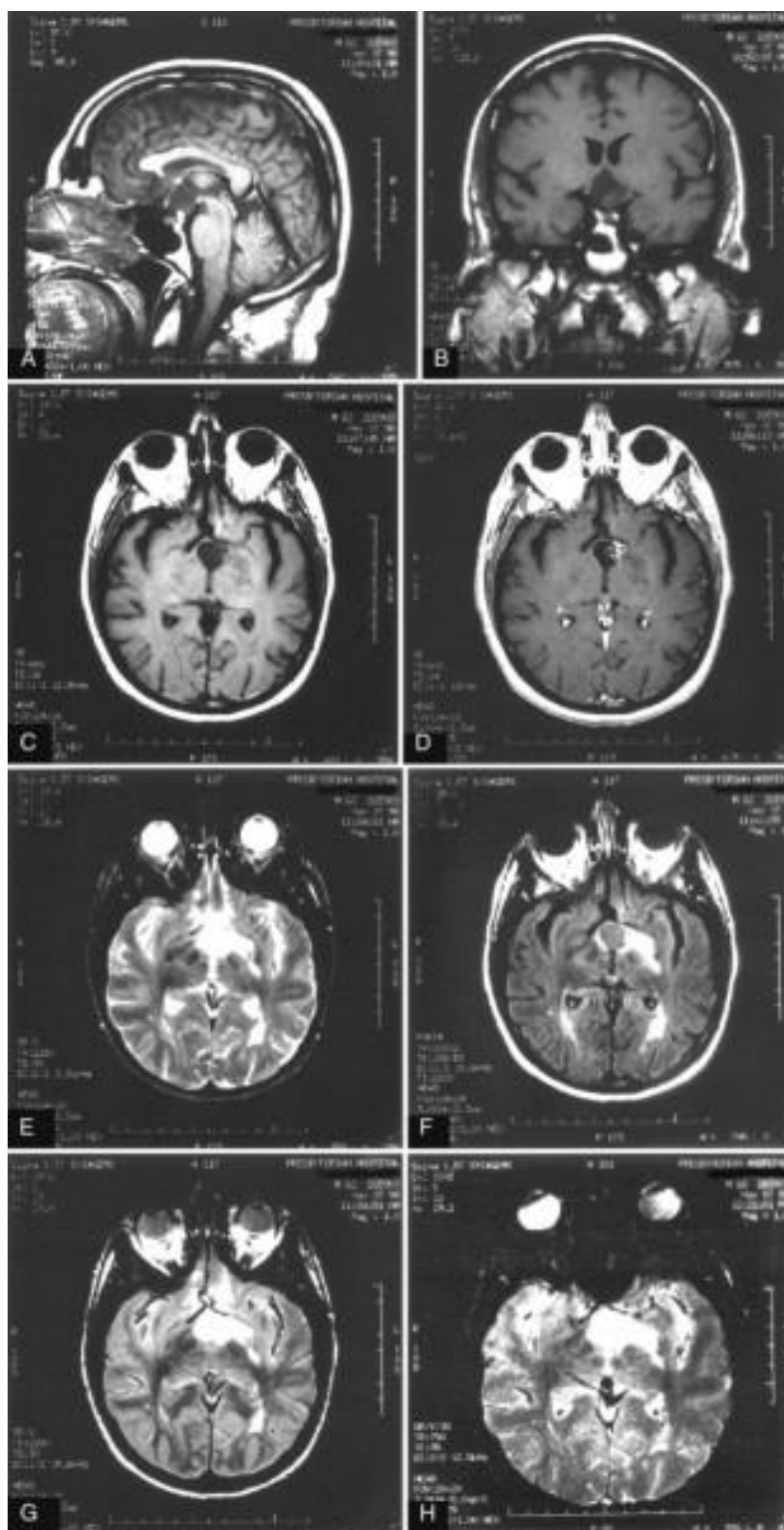
D, Contrast-enhanced, T1-MRI - rim of cyst wall enhancement and region of intracyst enhancement.

E, T2-MRI - hyperintense signal of cyst contents that follows signal change in cerebrospinal fluid.

F, FLAIR MRI - increased intensity in cyst and some parenchymal hyperintensity around tumor, consistent with edema.

G, Proton density axial MRI - cyst contents somewhat heterogeneous.

H, Gradient echo axial MRI - cyst heterogeneity.



Source of picture: H. Richard Winn "Youmans Neurological Surgery", 6th ed. (2011); Saunders; ISBN-13: 978-1416053163 >>

TREATMENT

- primarily **surgical** - **complete resection** (not always feasible given difficulty of completely removing cyst wall at locations where it adheres to adjacent structures)
 - simple cyst aspiration, cyst wall marsupialization, or creation of cyst-subarachnoid shunt*, are considered in difficult cases.
 - *aseptic meningitis has not been problem one might expect.
 - **recurrence** is possible even after gross total resection → **reoperation**.
 - radiotherapy and chemotherapy have little to offer; whether there may be some role for radiosurgery in treatment of residual neurenteric cysts remains to be seen.

DERMOID tumor, EPIDERMOID tumor

- benign **inclusion cysts** (not true neoplasms!) composed of **ectodermal elements**.

dif. CHOLESTEATOMA → see p. Ear38 >>

ETIOLOGY

- **congenital** (embryonic remnants) - inclusion of ectodermal epithelial elements:
 - during 3-5th embryonic weeks when neural tube closes at midline → midline tumors (esp. *DERMOIDS*)
 - during formation of secondary cerebral vesicles → lateral tumors (esp. *EPIDERMOIDS*).

N.B. *EPIDERMOIDS* also may be **acquired** – due to trauma, frequently from lumbar puncture (epithelial cells deposited within spinal canal, mostly historical when spinal needles didn't have stylet).

PATHOLOGY

- similar appearances and developmental origins;
 - both contain stratified squamous epithelium found in skin.
 - centrally, both contain desquamated epithelial keratin and some lipid material (cyst fluid may contain cholesterol crystals).
 - external surface is smooth, lobulated; *EPIDERMOIDS* has pearly appearance ("pearly tumors" or "keratin pearls"* in wall) due to capsule of stratified squamous epithelium.
 - *histo – cell nuclei among keratin (vs. pure keratin s. "wet keratin" in craniopharyngioma)

EPIDERMOIDS have outer **connective tissue capsule** and are lined with **stratified squamous epithelium** (i.e. composed of *ectodermal* remnants).
DERMOIDS have outer **connective tissue capsule** and are lined with **stratified squamous epithelium**, which also contains **hair follicles, sebaceous glands, and sweat glands** (i.e. composed of *ectodermal* and *mesodermal* remnants).

vs. *TERATOMAS* - composed of *ectoderm, mesoderm, and endoderm*

- *expand slowly over many years* due to central accumulation of epithelial debris and glandular secretions – predictable **linear growth** due to accumulation of keratin (vs. tumors – **grow exponentially** due to cell multiplication).
- *DERMOIDS* frequently calcify; *EPIDERMOIDS* calcify uncommonly (but when it occurs, it is feature that helps in distinguishing from arachnoid cysts).
- *malignant transformation* is rare.

LOCATION:

- sites of epithelial deposition can occur anywhere between neural tube and overlying skin surface (depending on stage of intrauterine development at which they arise, they can lie within ventricular system, brain parenchyma, subarachnoid space, bones of skull, or even extracranially):

DERMOIDS (INTRACRANIAL) - most commonly **midline**: 2/3 in **posterior fossa** (extradural, vermian, or within 4th ventricle); also suprasellar region, subfrontal areas; other sites – scalp (commonest location in childhood), skull, orbit, nasal, oral cavity, neck.

DERMOIDS (SPINAL) - most commonly near thoracolumbar junction, tends to involve conus medullaris and **cauda equina**:

- intramedullary ≈ 50%
- intradural extramedullary ≈ 50%
- extradural ≈ least common

Dermoids should be considered whenever lumbar puncture yields fat in CSF!

EPIDERMOIDS - most commonly **lateral** near **cerebellopontine angle**; may also occur in suprasellar and parasellar regions, choroidal, sylvian, and interhemispheric fissures, intraventricular, intradiploic (in cranial bones), inside spinal cord; intracerebral epidermoid is very rare.

EPIDEMIOLOGY

DERMOID - uncommon (≈ 0.3% of all brain tumors).

EPIDERMOID - 4-10 times more frequent than dermoid (≈ 2% of all intracranial tumors).

CLINICAL FEATURES

Patient's age at diagnosis:

- DERMOID** – generally do not produce clinical symptoms until 3rd decade of life (i.e. > 20 yrs)
- EPIDERMOID** (enlarges more slowly than dermoid) - 40-50 yrs.

Symptoms & signs are associated with slowly progressing **mass/pressure effect** (seizures, diabetes insipidus, hypopituitarism, etc).

- blockage of CSF flow occurs only rarely!
- cyst **rupture** → intense granulomatous **chemical meningitis** (rarely results in infarction from vasospasm).
- associated **dermal sinus tracts / dimples** are common:

Any infant with dermal sinus tract → neuroradiological evaluation!

congenital lumbar dermal sinus may terminate in **EPIDERMOID** (less frequently **DERMOID**) within or near conus medullaris or cauda equina; often associated with spinal dysraphism and vertebral abnormalities.

congenital nasal dermal sinus may be associated with **DERMOID** or **EPIDERMOID**.

- if associated **dermal sinus tract** becomes **infected** → recurrent **bacterial meningitis**.

DIAGNOSIS

Absence of edema is characteristic!

Plain radiographs – local bone expansion or erosion, lytic lesions with thin sclerotic margin.

CT – well-circumscribed, unilocular cystic mass; calcifications in tumor wall.

- contrast enhancement is uncommon!!! (**EPIDERMOID** wall may sometimes enhance).
- **DERMOID** fat gives very low density (may be slightly heterogeneous due to additional ectodermal elements - hair follicles, sebaceous glands, sweat glands).
- **fat-fluid level** in ventricles or **fat droplets** in subarachnoid spaces strongly suggest **DERMOID** rupture.

MRI:

DERMOID - characteristics similar to **fat** (glandular secretions) – midline mass **hyperintense** on both T1 and T2 – unique tumor!

- **chemical-shift artifact** is often present on T2 images as markedly hypointense band posterior at fat-fluid interface.

EPIDERMOID - characteristics similar to **CSF** – variably **hypointense** on T1 and variably **hyperintense** on T2 – mimics arachnoid cyst (H: **DWI** – **epidermoid has diffusion restriction**).

Epidermoid cyst has **diffusion restriction** (bright on DWI, dark on ADC) vs. arachnoid cyst (normal DWI)
Abscess, stroke, and lymphoma (high cellularity) also have **diffusion restriction** vs. gliomas and metastases do not restrict diffusion!

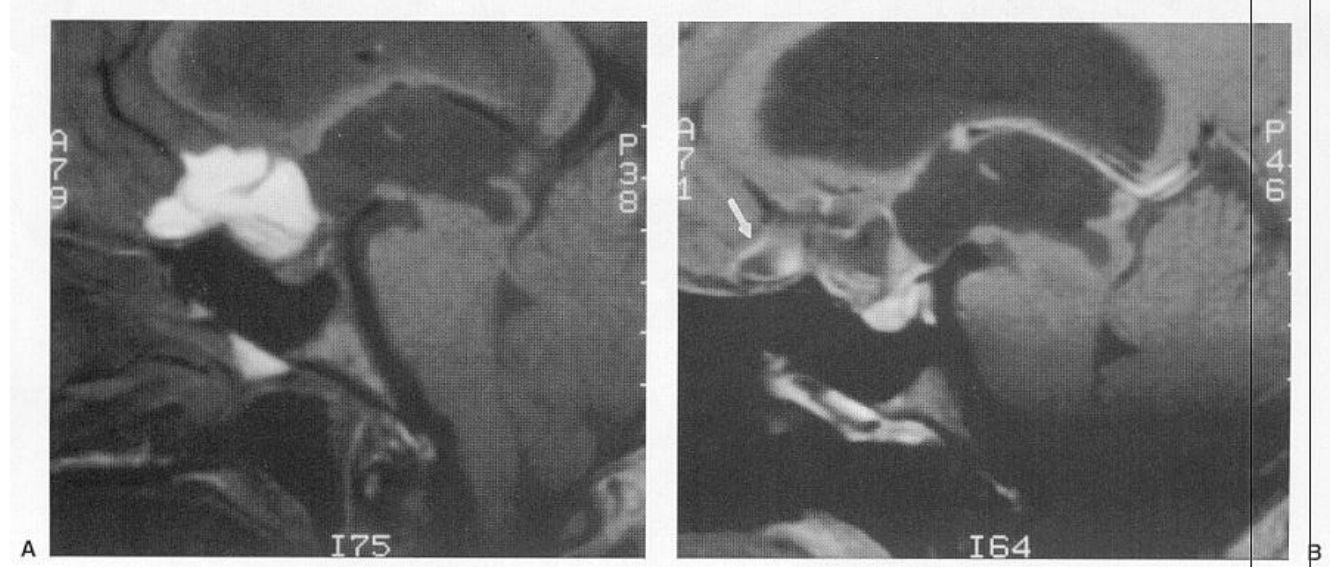
Angiography - avascular mass.


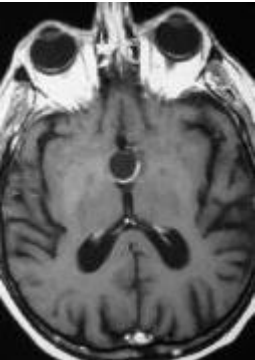

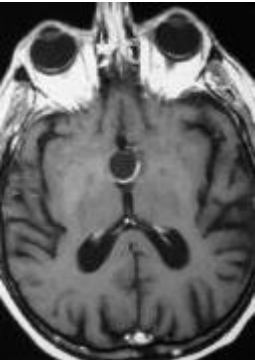
Prenatal diagnosis with **ultrasound** (and resection shortly after birth) are now possible.

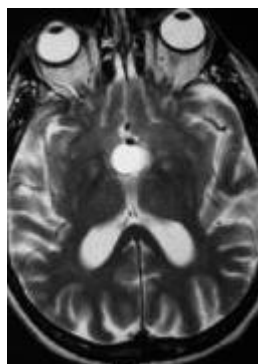
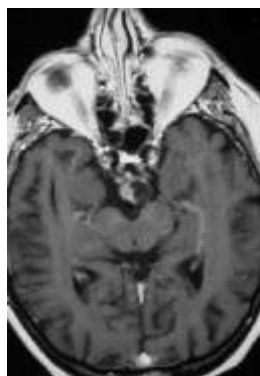
Suprasellar **dermoid**:

A) noncontrast T1 - high-signal-intensity suprasellar mass extending along planum sphenoidale.

B) contrast T1 with fat saturation - small amount of enhancement along peripheral aspects of lesion (*arrow*); majority of mass suppresses with fat saturation:

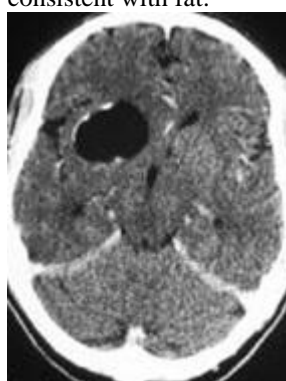
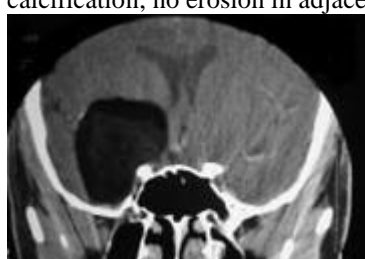
<p>Dermoid (nonenhanced CT) - well-circumscribed, cystic, low-attenuating lesion at midline in suprasellar region, posterior to 3rd ventricle; small focus of calcification is noted at posterior margin of tumor:</p> 	<p>Same dermoid (T1) - hypointense lesion; crescentic posterior rim of hyperintensity represents fat chemical-shift artifact:</p> 
<p>Same dermoid (T1 with contrast) - nodular focus of enhancement in right side of suprasellar lesion:</p> 	<p>Same dermoid (T2) - hyperintense cystic component in lesion:</p> 



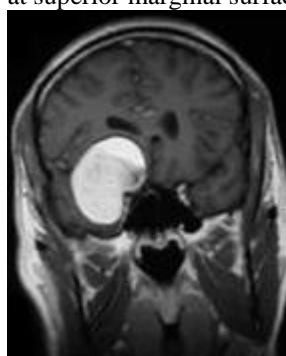
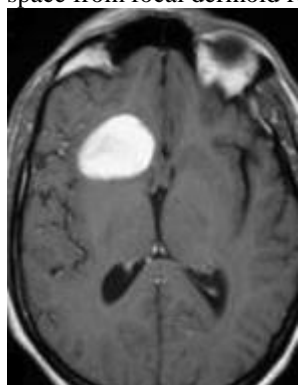
Dermoid (nonenhanced CT) - large, well-circumscribed low-attenuating cystic lesion in right temporal lobe lateral to cranial midline; peripheral marginal calcification; no erosion in adjacent bone of sella:

Same dermoid (contrast CT) - partial marginal enhancement; attenuation degree in center of lesion consistent with fat:



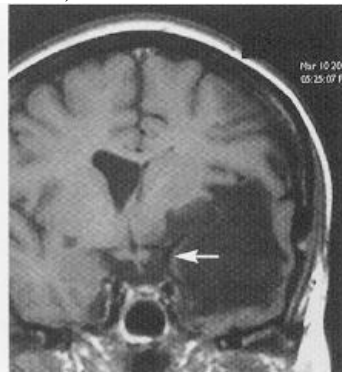
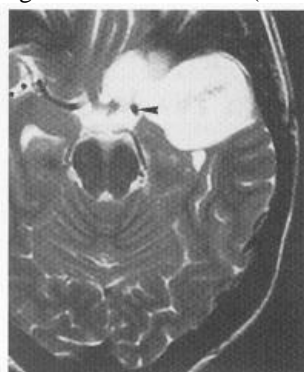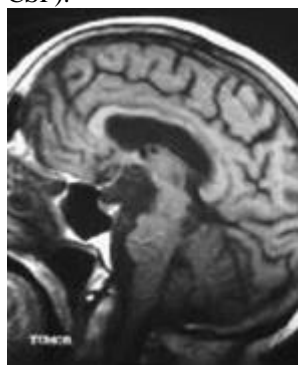
Same dermoid (T1) – hyperintense signal in lesion; multiple small hyperintense foci along sulci of right temporal lobe (represent fat droplets in subarachnoid space from focal dermoid rupture):

Same dermoid (T1 with contrast) - hyperintense lesion (hyperintensity is due to short T1 of fat); multiple hyperintense foci (fat droplets) in subarachnoid spaces; mild midline septal shift to left; chemical-shift artifact at superior marginal surface of lesion:



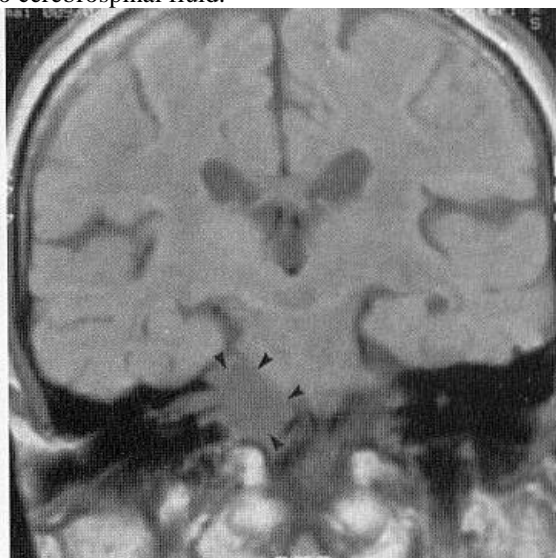
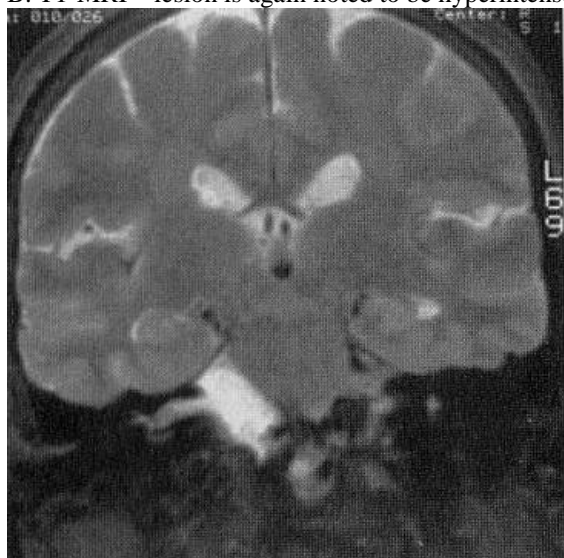
Epidermoid (T1 with contrast) - suprasellar, prepontine, and interpeduncular location of nonenhancing tumor (signal intensity similar to CSF):

Epidermoid (A- T2-weighted; B- T1-weighted MRI): left Sylvian fissure is filled by mass which extends into chiasmatic cistern and encases left internal carotid artery termination (arrowhead); signal is similar to CSF on T2, but slightly higher than CSF on T1 (white arrow):



Epidermoid:

A. T2-MRI – large homogeneous mass, which is slightly higher in signal than CSF, fills right cerebellopontine angle
 B. T1-MRI – lesion is again noted to be hyperintense to cerebrospinal fluid.



TREATMENT

- complete **surgical excision** is curative.
 - epidermoids **do not invade but interdigitate** around vital structures - complicating surgical removal.
 - avoid spilling of contents → chemical meningitis (15%); prophylaxis – irrigation with dexamethasone solution intraop + 2 weeks of oral dexamethasone (↑↑↑risk of infection).
 - associated dermal sinus should be removed completely.

Chemotherapy and **radiotherapy** are not useful.

EPIDERMOID CYSTS (from WHO manual)

- benign ectopic inclusions of epithelial cells during gastrulation (i.e. malformations of surface ectoderm) → secondary disruption of neural tube closure (i.e. dysraphism is secondary).
 N.B. epidermoid and dermoid cysts represent malformations of surface ectoderm (as opposed to neuroectoderm)

PATHOLOGY

- location – tend to be off midline:
 - A. **SPINE** - intradural extramedullary (rarely intramedullary)
 - B. **CRANIAL** (0.2% to 1.8% of all intracranial tumors):
 - a) **intradural** (usually extra-axial) - cerebellopontine angle (may extend into Meckel's cave) or parasellar cisterns
 - b) **extradural** (usually arising in diploic space of calvaria)
- thin **capsule** of stratified, keratinized squamous epithelium.
- **cyst** contains accumulation of desquamated epithelial cells, keratin, and cholesterol (characteristic *pearly flakes*).
- malignant transformation is rare, but **SQUAMOUS CELL CARCINOMA** has been reported (reported 15 cases with leptomeningeal dissemination of squamous cell carcinoma); **MALIGNANT MELANOMA** has also been reported in temporal lobe epidermoid.
- immunohistochemical staining positive for **carbohydrate antigen CA19-9*** (also detected in serum - can be used to evaluate for tumor recurrence or progression).

CLINICAL FINDINGS

- reported from infancy to adulthood + incidental findings at autopsy.
- average age at detection is 35-40 years
- female preponderance
- grow linearly (similar to normal skin) → insidious onset (median duration of symptoms 4-14 years).
- picture of acute meningitis may indicate epidermoid cyst rupture.
- spinal epidermoid tumors are frequently associated with vertebral anomalies.

EXTRADURAL LESIONS - manifest as local mass.

INTRADURAL TUMORS - headache (because of common parasellar location), visual disturbance, and to lesser extent, hypothalamic alterations.

- tumors in middle fossa grow quite insidiously and are often asymptomatic.
- tumors in cerebellopontine angle may cause ataxia, dizziness, or cranial nerve deficits.

IMAGING

CRANIAL XR – for *intradiploic tumors* - typically in cranial vault (may also occur in orbital region)

- lytic erosion of skull, sharply delineated sclerotic edge and scalloped margins on plain radiographs.
- inner table of skull is usually destroyed and outer table thinned.

CT - homogeneous nonenhancing hypodense lesion in subarachnoid space without surrounding edema.

- occasionally, high density masses (“white epidermoids”) - difficult diagnosis.

Differential diagnosis: arachnoid cyst, Rathke's cleft cyst, craniopharyngioma.

- differentiation from **ARACHNOID CYST**:
 - 1) diffusion restriction on DWI (vs. arachnoid cysts – no diffusion restriction)
 - 2) more fat density than CSF density
 - 3) extend into subarachnoid space and enlarge it (vs. arachnoid cysts cause more focal mass effect).

MRI - hypointense to hyperintense, heterogeneous, multiloculated.

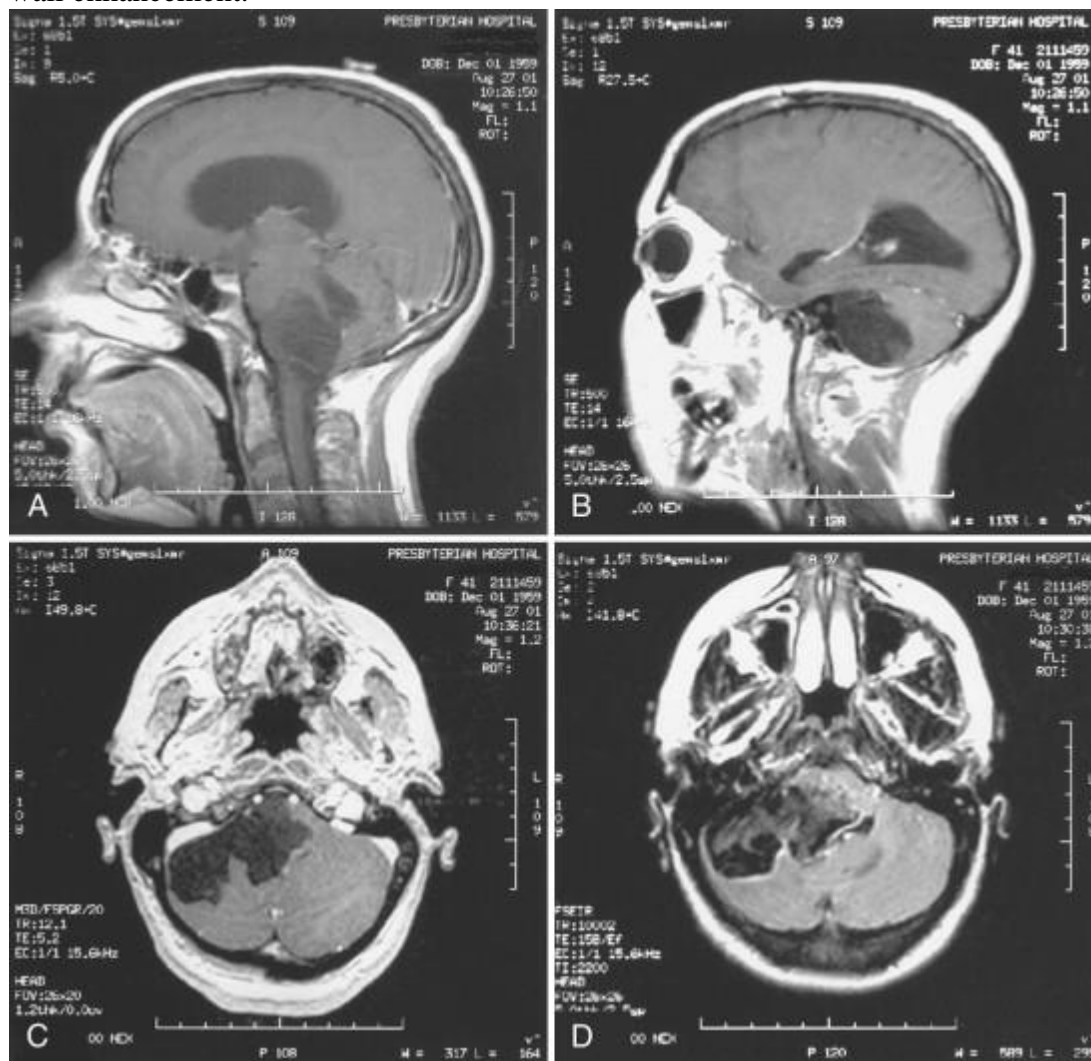
- T1 hypointensity + T2 hyperintensity
- some tumors show rim enhancement
- no surrounding edema
- hydrocephalus is rare
- DW imaging is superior to other types of MRI sequencing in delineating borders of epidermoid cysts.

A, Contrast-enhanced, T1-MRI - hypointense mass without enhancing components in midline posterior fossa. The mass is compressing brainstem and obstructing egress of cerebrospinal fluid from fourth ventricle, thereby causing hydrocephalus.

B, More lateral extent of this tumor.

C, Mass insinuating between normal posterior fossa structures and extending to involve both right cerebellopontine angle and midline structures.

D, Contrast-enhanced, FLAIR MRI - marked heterogeneity within cyst and discontinuous rim of cyst wall enhancement.



Source of picture: H. Richard Winn “Youmans Neurological Surgery”, 6th ed. (2011); Saunders; ISBN-13: 978-1416053163 >>

TREATMENT

- symptomatic patients benefit from surgery (technically difficult because of tumor adhesions)
- tumor is well demarcated, with smooth, hypovascular capsule
- primary intracapsular debulking (CUSA is extremely useful) → removal of capsule (fragments of capsule adherent to important structures are left when necessary to avoid neural or vascular injury).
 - although subtotal resection increases risk for recurrence, slow growth of epidermoid cysts makes this less problematic.
 - capsule should not be removed from intramedullary cysts because of risk of causing neurological deficits or preoperative cyst rupture (radiographic finding of small fat globules in subarachnoid and intraventricular spaces)
- MENINGITIS → steroids
- no established role for radiotherapy or chemotherapy for residual / recurrent epidermoid cysts.

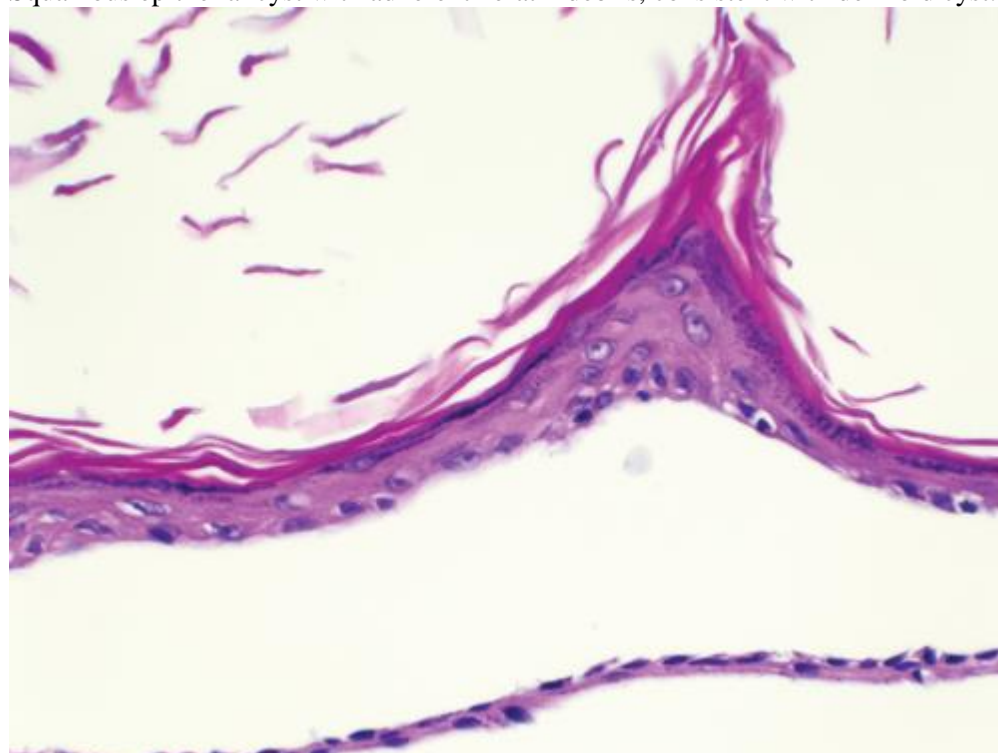
DERMOID CYSTS (from WHO manual)

- manifest at earlier age than epidermoids and have shorter duration of symptoms (duration of symptoms average 8.5 years; vs. 16 in epidermoids).
- female preponderance
- denser tumors than epidermoids → more focal mass effect - patients are initially seen at younger age (average age at diagnosis - 15 years; vs. 35-40 in epidermoids).
- tend to occur at **MIDLINE** (when extradural, may arise at anterior fontanelle).
- reported in association with Klippel-Feil syndrome.

PATHOLOGY

- positive for **CA19-9*** in many cases (serum CA19-9 levels tend to be higher than in epidermoid cysts - means of follow-up for residual or recurrent disease).
*tumor marker for pancreatic cancer
- dermoids contain **elements of dermis** (hair and hair follicles + apocrine, sebaceous, or sweat glands).
- epithelial cell lining may be less differentiated (than in epidermoids)

Squamous epithelial cyst with adherent keratin debris, consistent with dermoid cyst. H & E, magnification x40:



CLINICAL FINDINGS

- local neural deficits, headache, or meningitis.
- dermoid cyst rupture - previously thought to be uniformly fatal.

IMAGING

CT - hypodense and avascular, no contrast enhancement.

- extradural cranial lesion shows typical bony erosive changes seen with epidermoids.

MRI - more signal heterogeneity than epidermoids; **high fat content** - **high signal on both T1- and T2-weighted images** – unique tumor!

- **nonenhancing** (rare cases of capsule contrast enhancement and even enhancing mural nodule should raise suspicion for neoplasm!).
- more solid (than epidermoid tumors) - less likely to grow between neurovascular structures and tend to demonstrate more of local mass effect.
- edema is lacking.
- **dermoid cyst rupture** → fat droplets may be seen throughout subarachnoid or intraventricular space, localized dissemination in sulci causing widening, perhaps contained by pia or inflammatory tissue; hydrocephalus secondary to CSF obstruction by fat droplets

TREATMENT

- **surgical extirpation** is treatment of choice - less problematic (than epidermoid tumors) because of firmer consistency; adherence of tumor capsule to vascular and neural structures → more conservative surgical approach.
- complete excision decreases risk for both postoperative chemical meningitis and tumor recurrence.
- tumor recurrence has been reported → reoperate.
- no current role for radiotherapy or chemotherapy.

COLLOID CYSTS

- **congenital benign tumors** that **can cause sudden death** because of their location (almost always found in **3rd ventricle** → obstructive hydrocephalus).

- 0.5-1% of all primary brain tumors (15-20% of all intraventricular masses).

ETIOLOGY

- possible sources:

- a) in 1910, Sjovall hypothesized that colloid cysts are remnants of **PARAPHYSIS** (embryonic midline structure within diencephalic roof immediately rostral to telencephalic border, in posterior lip of foramen of Monro) - cells of paraphysis are similar to those found in colloid cysts (i.e. low columnar epithelial cells without cilia or blepharoplasts) - colloid cysts were called *paraphyseal cysts* for 50 years.
- b) diencephalic **ependyma**
- c) invagination of **neuroepithelium** of ventricle
- d) **respiratory epithelium** of endodermal origin.

PATHOLOGY

- arise in anterior superior portion of 3rd ventricle between fornices, **immediately dorsal to Monro foramen**.
also have been reported to arise in septum pellucidum, 4th ventricle, sella turcica.
- attached to roof of 3rd ventricle (and frequently to choroid plexus).
- gross appearance of **small white ball**.
- lined with simple or pseudostratified cuboidal or low columnar ciliated **epithelial cells** (PAS-positive; stain positively for S100 and negatively for glial fibrillary acidic protein, vimentin, and neurofilament).
- epithelial lining **secretes mucinous fluid** (greenish, of variable viscosity and can be rubbery) → cyst enlargement.

CLINICAL FEATURES

- classic **intermittent obstructive hydrocephalus** with paroxysmal **HEADACHE associated with changing head position** (large cyst obstructing Monro foramen).

Positional headache!

- usually present in age 20-50 yrs (youngest reported case - 2-month-old infant).
- other reported symptoms (sometimes related to changes in posture):

- sudden weakness in lower limbs associated with **falls without loss of consciousness**.
- symptoms similar to **normal pressure hydrocephalus** (dementia, gait disturbance, urinary incontinence).
- **short memory deficits** due to fornix stretching!
Mental changes are common (may persist after surgery if fornix is damaged)!
- look for papilledema.
- **sudden death** (incidence appears to be low) has been reported; may not correlate to tumor size, degree of ventricular dilatation, or duration of symptoms; suggested mechanisms:
 - a) acute hydrocephalus
 - b) hypothalamic dysfunction

DIAGNOSIS

CT - well delineated, round or ovoid, homogenous, 66% **hyperdense** (to surrounding parenchyma) and 33% isodense.

- most are 5-25 mm.
- typically **nonenhancing** and **uncalcified** (occasional thin rim of enhancement).
- **viscosity* of cyst contents** correlates more closely to radiodensity on CT than to density visible on MRI.

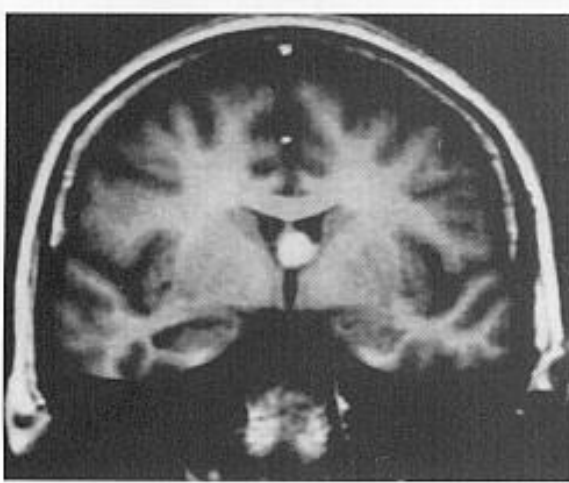
**viscosity determines most appropriate surgical approach*; hyperdense cyst is more likely to have solid contents - more difficult to drain, but reduced capacity to enlarge over time.

MRI - hyperintense on T1 and hypointense on T2.

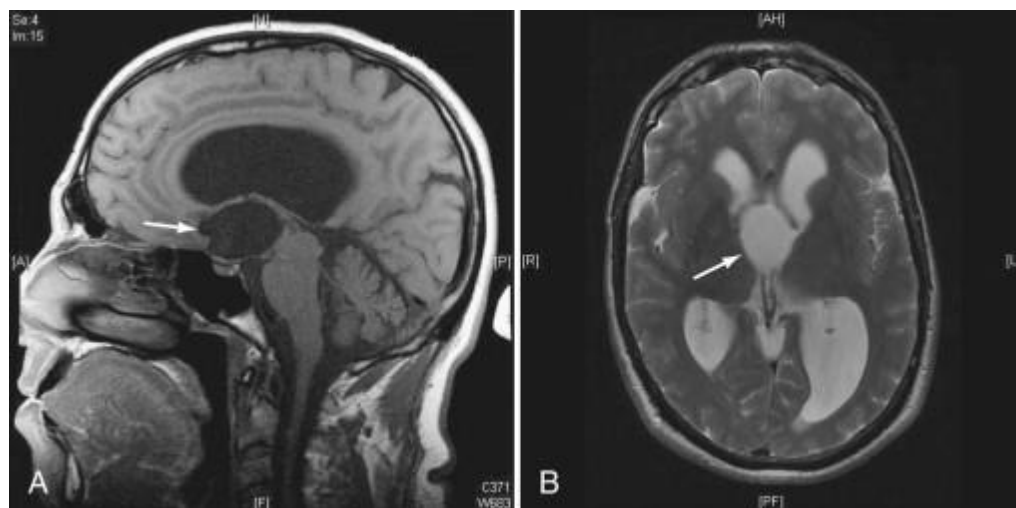
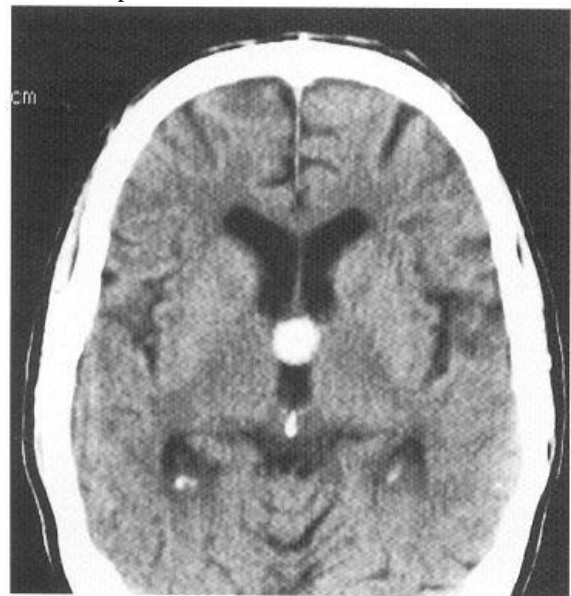
N.B. CSF flow artifact at Monro foramen can mimic colloid cyst!

- amount of rim enhancement is variable.
- MRI differentiates colloid cyst from basilar tip aneurysm (may have similar appearance on CT).

T1-MRI without contrast: well-circumscribed high-signal-intensity lesion adjacent to foramen of Monro:



CT - dense, rounded mass in region of foramina of Monro causing enlargement of lateral ventricles, and indenting anterior aspect of 3rd ventricle:



TREATMENT - STRATEGY

Immediate attention to hydrocephalus!

Strategy:

- a) **large cyst & hydrocephalus** → **surgery**.
 - *if patient is too ill* → **bilateral CSF diversion or unilateral with septostomy** (suboptimal because sudden death has been reported in absence of acute obstructive hydrocephalus)
- b) small cyst, large ventricles, few or no symptoms → **observation** with serial MRIs.
- c) small cysts and normal-sized ventricles → **observation**.

N.B. prevention of sudden death is not indication for surgery in asymptomatic patients with small cysts and no hydrocephalus!

- explain to patient that cyst stretches fornix - look for preoperative **short memory deficits** – those may worsen postop if fornix is further violated surgically.

TREATMENT - SURGERY

- a) **endoscopic-transventricular approach** – only if hydrocephalus is present
- b) **transcortical-transventricular approach** – only if hydrocephalus is present
- c) **transcallosal approach** – see p. Op340 >>
- d) **subfrontal lamina terminalis approach**

Surgical approaches:

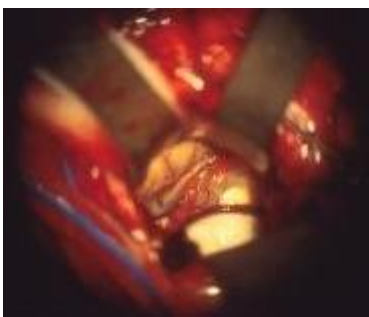Transcortical approach

The transcortical approach involves making corticectomy over middle frontal gyrus and proceeding to frontal horn of lateral ventricle. Intraoperative ultrasonography may aid in approach to ventricle. The Monro foramen is visualized at convergence of septal veins, thalamostriate vein, and choroid plexus. The fornix arches over superior and anterior margins of foramen. Avoiding fornix is important because unilateral fornix damage has been associated with amnesia. The cyst should be readily visualized through foramen. The cyst is punctured and contents are aspirated, internally decompressing walls of cyst.

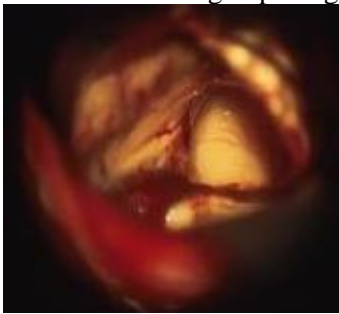
Avoid excessive retraction of walls of lateral ventricle because genu of internal capsule is in subependyma. Other concerns include damaging thalamostriate veins, which can result in basal ganglia damage. After cyst has been decompressed, completely remove it in order to prevent recurrence. Leaving small portion of cyst behind may be necessary if it is attached to either thalamostriate or internal cerebral veins.

The transcortical approach carries increased incidence of epilepsy.

Intraoperative photograph through operating microscope shows colloid cyst in Monro foramen. Choroid plexus is observed overlying cyst, and thalamostriate vein is along inferior border:



Intraoperative photograph showing removal of cyst, leaving dilated Monro foramen. The third ventricle can be seen through opening:



Endoscopic approach

The endoscopic approach is same as transcortical approach, with exception that former is accomplished through burr hole. The cyst is punctured and aspirated through working channels of endoscope. The endoscopic approach is least invasive, but it can be used only on cysts that can be aspirated. Hydrocephalus can persist after surgery, even after resection of cyst. This complication may be secondary to spillage of cyst contents or to bleeding during surgery. A ventricular catheter may be placed intraoperatively to safeguard against ventricular dilatation.

POSTOPERATIVE FOLLOW-UP

Hydrocephalus may develop despite cyst removal; H: periodic CT.
Cyst may recur if partially excised!

ARACHNOID CYSTS

References

Mark S. Greenberg “Handbook of Neurosurgery” 8th ed. (2016), ch. 15.1

FEATURES

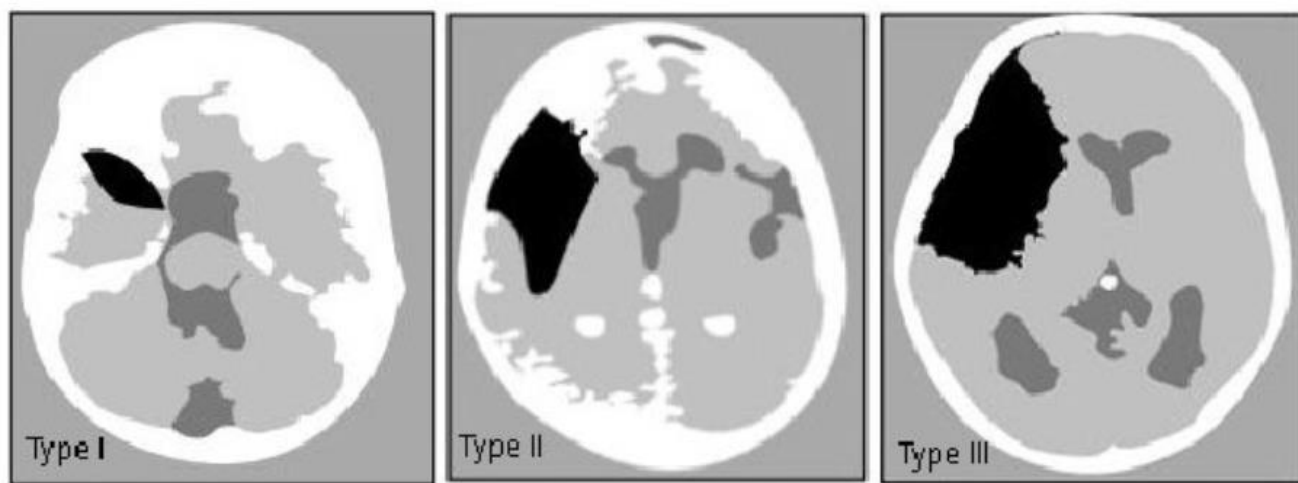
- congenital - splitting of arachnoid membrane (thus they are technically intra-arachnoid cysts), contain fluid identical to CSF.
- arise *anywhere on brain surface* or in spinal canal.
- almost all occur in relation to an arachnoid cistern (exception: intrasellar - only one that is extradural).

Location	%
sylvian fissure	49%
CPA	11%
supracollicular	10%
vermian	9%
sellar & suprasellar	9%
interhemispheric	5%
cerebral convexity	4%
clival	3%

- incidence: 5 per 1000 in autopsy series (≈ 1% of intracranial masses).
- male:female ratio = 4:1.
- bilateral arachnoid cysts may occur in Hurler syndrome (a mucopolysaccharidosis).
- lined with meningotheial cells positive for epithelial membrane antigen (EMA) and negative for carcinoembryonic antigen (CEA) - two types:
 - 1) “simple arachnoid cysts”: arachnoid lining with cells that appear to be capable of active CSF secretion (middle fossa cysts seem to be exclusively of this type).
 - 2) cysts with more complex lining which may also contain neuroglia, ependyma, and other tissue types
- do not communicate with the ventricles or subarachnoid space.
- uniloculated or have septations
- incidence of growth – about 2% (some grow to remarkable size.).
- smooth surface (vs. *EPIDERMoids* - cauliflower-like deep clefts).
- may **hemorrhage** (into cyst or subdural compartment): **middle fossa cysts** are notorious for hemorrhage due to tearing of bridging veins - some sports organizations do not allow participation in contact sports for these patients.

Obsolete term - “*temporal lobe agenesis syndrome*” - findings with middle cranial fossa ACs; however, the brain volumes on each side are actually the same (bone expansion and shift of brain matter account for the parenchyma that appears to be replaced by the AC).

- clinically: majority are *incidental findings*; most commonly symptomatic location – **suprasellar**:
 - a) **hydrocephalus** (probably due to compression of the third ventricle)
 - b) **endocrine** symptoms: occurs in up to 60% (incl. precocious puberty)
 - c) **head bobbing** (the so-called “bobble-head doll syndrome” - considered suggestive of suprasellar cysts, but occurs in as few as 10%).
 - d) **visual** impairment
- imaging – nonenhancing, extraparenchymal cyst with characteristics exactly mimicking CSF;
 - remodeling of bone (chronic nature).
 - **no diffusion restriction** on DW-MRI (vs. *EPIDERMoids* - diffusion restriction).
 - evaluation with CSF contrast or flow studies (cisternograms, ventriculograms) are only occasionally necessary for midline suprasellar and posterior fossa cysts.
 - never calcify!



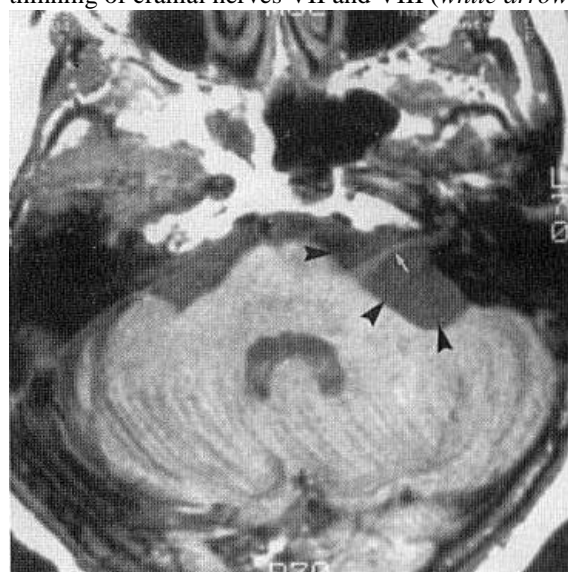
CT Classification of Sylvian fissure arachnoid cysts.

Type I: small, biconvex, located in anterior temporal tip. No mass effect. Communicates with subarachnoid space on water-soluble contrast CT cisternogram (WS-CTC).

Type II: involves proximal and intermediate segments of Sylvian fissure. Completely open insula gives rectangular shape. Partial communication on WS-CTC.

Type III: involves entire Sylvian fissure. Marked midline shift. Bony expansion of middle fossa (elevation of lesser wing of sphenoid, outward expansion of squamous temporal bone). Minimal communication on WS-CTC. Surgical treatment usually does not result in total reexpansion of brain (may approach type II lesion).

T1-MRI - large, fluid-filled structure expands left cerebellopontine angle cistern (arrowheads); note elongation and thinning of cranial nerves VII and VIII (white arrow):



TREATMENT

- *asymptomatic* - best left alone regardless of size or location (in adults, a single follow-up imaging in 6–8 months is adequate to rule-out any increase in size; children need to be followed until adulthood).
- indications for surgical treatment:
 1. Accelerated head growth in younger patients.
 2. Significant midline shift.
 3. Enlarging over time.
 4. Obstructive hydrocephalus.
- surgery in *symptomatic* cases yields good results:
 - a) cyst **aspiration** – high rate of recurrence.
 - b) cyst **fenestration** – best treatment!
 - c) cyst **shunting** – second best treatment (due to risk of shunt dependence); for shunting into peritoneum, use a low pressure valve; if there is concurrent ventriculomegaly, may also place a ventricular shunt (e.g. through a “Y” connector).
 - d) cyst **excision** - significant *morbidity and mortality* (may be due to abrupt decompression), subsequent scarring may block fenestration allowing reaccumulation of cyst, flow through subarachnoid space may be deficient

Suprasellar cysts (endocrinopathies tend to persist even after successful treatment of suprasellar cysts):

- a) endoscopic **ventriculo-cystostomy** - procedure of choice of Pierre-Kahn et al.
Pierre-Kahn A, Capelle L, Brauner R, Sainte-Rose C, et al. Presentation and Management of Suprasellar Arachnoid Cysts: Review of 20 Cases. J Neurosurg. 1990; 73:355–359
- b) subfrontal or transcallosal **cystectomy** - dangerous and ineffective.

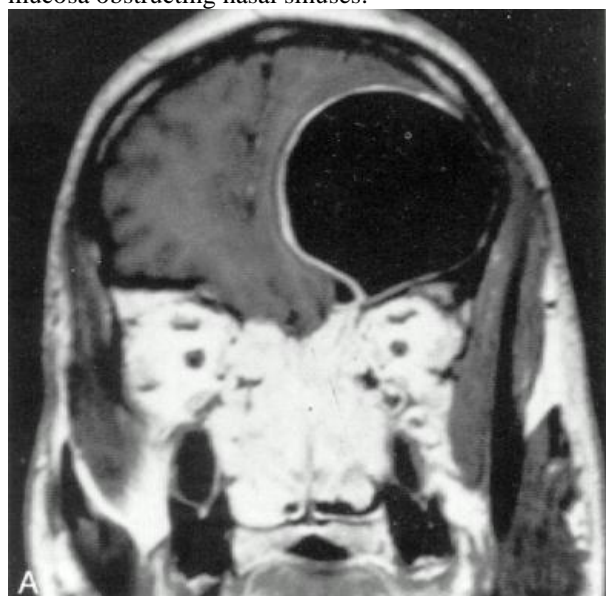Middle fossa cysts - shunting may be accomplished through the lateral ventricle, thus shunting both compartments (distal shunt tubing should be routed behind the ear; do not tunnel in front of ear - injury to facial nerve or solicit the plastic surgeon to help avoid the facial nerve).

LIPOMA

- derived from mesoderm.
- occur chiefly in *midline* (esp. over corpus callosum*, vermis, quadrigeminal cistern, spinal dural sac).
*often associated with **callosal dysgenesis**
- majority are *incidental findings*.
- characteristic appearance on both **CT** and **MRI** - fat density; calcification is frequent in periphery.

MUCOCELE

Frontal mucocele (contrast MRI) - large mucocele compressing frontal lobe, with chronic inflammation of nasal mucosa obstructing nasal sinuses:



BIBLIOGRAPHY for ch. "Neuro-Oncology" → follow this [LINK >>](#)

Viktor's NotesSM for the Neurosurgery Resident
Please visit website at www.NeurosurgeryResident.net