CSF shunting procedures

Last updated: December 20, 2020

SHUNT TIE-OFF

- use thick silk.
- place sleeve of rubber (e.g. opened rubber shod) on catheter – if later will need to untie, will cut on rubber and not on catheter.

VENTRICULOPERITONEAL (VP) SHUNT

RESOURCES

R. **Jandial** "Core Techniques in Operative Neurosurgery" (2011)

Pending read: Connolly ch. 118-121, 123
Karl Storz NeuroEndoscopes and Instruments >>

INDICATIONS

1. Hydrocephalus, communicating or obstructive:
   a) not amenable to endoscopic third ventriculostomy
   b) not amenable to treatment of primary etiology (e.g. removal of 4th ventricle neoplasm).
2. Failure of previously placed shunt system

CONTRAINDICATIONS

1. Fevers
2. Any evidence of active intracranial infection
3. Abnormal CSF rheology (pleocytosis, intraventricular hemorrhage or SAH with still bloody CSF)
   N.B. high protein (e.g. > 100) does not affect shunt performance!
4. Body weight < 2 kg (relative)
5. Peritoneal cavity with reduced absorptive capacity (e.g. multiple operations, recent abdominal sepsis, known malabsorptive peritoneal cavity).

PREOPERATIVE

1. Check CSF (protein content, pleocytosis, infection)
2. Clamp EVD at midnight to expand ventricles (for pediatric / critical patient may raise EVD instead of clamping)
3. Recent CT / MRI

EQUIPMENT FOR OR

Valve and programming device
Catheters
Manometer
X-ray (for air ventriculogram) / ventricular endoscope / O-arm – all for verification
C-arm – for finding old catheters (in revision cases).
Laparoscopic tower

PROCEDURE

POSITIONING

- supine with **head turned** to left.

- JRC - **bump under shoulders** (Holloway – only for kids – large head) to allow for straight trajectory from right occiput, across clavicle, to abdomen.
- Tye, Collins place large bump under shoulders to get good neck extension; Collins covers entire prep zone perimeter with self-adhesive clear plastic drape "3M 1010" (keeps patient dry and warm – allows to keep lower temperature in OR and keep sheets dry)

Source of picture: R. Jandial "Core Techniques in Operative Neurosurgery: Expert Consult - Online and Print", 1st ed (2011), Saunders; ISBN-13: 978-1437709070 >>

PREP

- Ritter uses alcohol → Betadine → ChloraPrep.
  Ritter may not use local anesthetic to prevent introducing skin flora.
- Tye uses Betadine for kids < 2 months.
- remove EVD (unless doing soft pass or on opposite side – may leave EVD until end of case – remove all stitches, pull EVD a little bit until you see sterile part and tie long silk string on it; drop silk down so that anesthesia can pull it in the middle of case; prep and drape so that catheter is hidden).
- Tye does not use staples to keep drapes! Collins uses lots of staples. Ritter uses few staples.

CRANIAL PORTION

- curvilinear (horseshoe or C*) scalp **incision** over planned bur hole; very little horseshoe radius for infants; Ritter creates opposite direction horseshoe flap in pericranium.
- with knife/needle electrocautery; may incorporate EVD incision (unless infected).

*base towards shunt direction
N.B. use shallow C (complete C is suboptimal for blood supply)

Entry and trajectory

Frontal – see p. Op6 >>
Occipital – see p. Op6 >>

Dr. Day:
1) use stylet always; *never soft pass* (catheter easily gets deflected).
2) use **bur-hole ultrasound** to guide the catheter!

Bur hole:

a) with 14 mm perforator (Young saves bone dust and replaces back to bur hole at the end)
b) with M8 bit – better small hole, esp. for little kids to prevent CSF leak (Ritter)

- for newborns, insert shunt via lateral corner of open anterior fontanel:
  a) Tye – coagulate soft tissue membrane with bipolar layer by layer until entering CSF space
  b) Collins – incise scalp skin over mosquito (advanced under galea), then open dural membrane by gentle incision with #15 blade.
- for premature kids use tip of # 15 blade to scrape hole in cranium.

Source of picture: R. Jandial "Core Techniques in Operative Neurosurgery: Expert Consult - Online and Print", 1st ed (2011), Saunders; ISBN-13: 978-1437709070 >>

Valve

- create subcutaneous pocket with blunt dissection (spreading tonsillar clamp or large Kelly clamp) to accommodate reservoir and valve.
- pump valve in saline bucket so no air inside remains (vs. Tye connects temporary short piece of catheter on proximal valve to protect from blood entry into valve and flushes with saline via blunt needle in catheter tip).
- inline valve is secured (with silk tie*) to proximal end of distal catheter.
  - Tye, JRC, Holloway like fixed medium-low pressure Codman valve (without Rickham)
  - Graham uses exclusively Medtronic (Codman has spiral antisiphon device that clogs very often)
  - for NPH patients use programmable valves

*knot on undersurface of valve to prevent skin erosion

Source of picture: R. Jandial "Core Techniques in Operative Neurosurgery: Expert Consult - Online and Print", 1st ed (2011), Saunders; ISBN-13: 978-1437709070 >>

- small hole in dura, same diameter as ventricular catheter, is made by electrocautery applied to blunt needle.

Source of picture: R. Jandial "Core Techniques in Operative Neurosurgery: Expert Consult - Online and Print", 1st ed (2011), Saunders; ISBN-13: 978-1437709070 >>

- antibiotic-impregnated Bactiseal ventricular catheter is cut* to age-appropriate length and passed over stylet into right lateral ventricle

  *JRC, Holloway leave catheter intact but move blue angle bender to 6 cm mark
  - "perpendicular to skull" catheter trajectory usually results in prompt entry into ventricle, and if catheter is advanced while removing stylet, tip of catheter heads toward frontal horn.
  - intraoperative US/CT/MRI, intracatheter endoscopy (Neuropen®; need to make slits in catheter tip beforehand), frameless stereotaxy can be useful adjuncts for ventricles that are difficult to cannulate.
  - ventricular cannulation failure:
    a) admit to ICU with hope of progressive ventricular dilation → reoperation
    b) if patient's life is in jeopardy, place shunt in CT scanner suite (or use O-arm)
- always send CSF for culture ± other studies (e.g. cytology).
- Young measures opening pressure with saline-filled **manometer**.
- may flush and aspirate valve chamber with **25G needle**.
- Young injects 4-5 mL of air inside ventricles (for air ventriculogram in PACU or in OR).
- ventricular catheter is (cut and) secured* to valve, and valve is placed in previously created subcutaneous scalp pocket.

  *never secure ventricular catheter to valve unless CSF is clear (H: gentle irrigation through catheter can resolve issues with blood or debris in ventricular catheter).

Source of picture: R. Jandial "Core Techniques in Operative Neurosurgery: Expert Consult - Online and Print", 1st ed (2011), Saunders; ISBN-13: 978-1437709070 >>

TUNNELING

- subcutaneous tunneler* (with plastic stylet within) is passed from cranial to abdominal incision (or opposite - JRC, Tye).

  *alternatively, create path and pocket with tonsillar forceps / uterine sound
  - may need additional incision in neck (most attendings prefer transverse [less chances violating shunt tubing when closing with staples] incision right above tunneler tip) – then use uterine sound from scalp incision to neck incision → tie catheter tip with thick silk to probe and pass to scalp.
  - Dr. Tye tries to tunnel as posterior from auricle as possible for small kids.
  - Dr. Collins uses nondisposable long metal tunneler (very stiff – allows long tunnels and tip steering) with plastic sheath over it.
- antibiotic-impregnated Bactiseal distal catheter is passed through tunneler (may continuously spray saline into tunneler lumen to facilitate passage), and tunneler is removed.

Source of picture: R. Jandial "Core Techniques in Operative Neurosurgery: Expert Consult - Online and Print", 1st ed (2011), Saunders; ISBN-13: 978-1437709070 >>

- if SHUNT ASSISTANT is needed, it is placed at postauricular incision level (tie silk on catheter to mark location, then pull catheter to scalp incision, place SHUNT ASSISTANT and pull catheter back into position – SHUNT ASSISTANT must be vertical in position).

  SHUNT ASSISTANT prevents oversiphoning thus must be selected according to patient's height
- after confirmation of **steady*** **CSF egress** from distal catheter, catheter is fed into peritoneal cavity under direct vision.

  *do not implant peritoneal catheter unless continuous CSF egress is observed.

  Correctable issues:
  1) "air blocks" in tubing (H: aspirate with blunt tip needle from distal end).
  2) "kinking" of distal tubing at level of attachment to valve in insufficiently capacious subcutaneous scalp pocket.

ABDOMINAL PORTION

- Tye, Young - horizontal incision close to midline in right mid-abdomen → cricket retractor → cut anterior rectus sheath vertically and split muscle fibers bluntly longitudinally → see peritoneum
- Ritter - vertical incision in right mid-abdomen with needle electrocautery.
- JRC, Broaddus – 4-5 cm midline* incision 2 finger breadths below xiphoid: large Weitlaner → linea alba (where fascial fibers cross) incised sharply → two perpendicular (to each other and to the floor) small Weitlaners → see peritoneum

  *muscle fiber division is minimized!
- peritoneum is gently elevated with mosquito clamps and incised with No. 11 blade; avoid bowel injury (insert tip of scissors under peritoneum fold before cutting to make sure no bowel is

captured); visual confirmation of entry into peritoneal cavity is made; leave mosquito on fascial edge for later easier finding:

Source of picture: R. Jandial "Core Techniques in Operative Neurosurgery: Expert Consult - Online and Print", 1st ed (2011), Saunders; ISBN-13: 978-1437709070 >>

Intraperitoneal placement – last step – to verify CSF flow (so everything proximally is OK)

Source of picture: R. Jandial "Core Techniques in Operative Neurosurgery: Expert Consult - Online and Print", 1st ed (2011), Saunders; ISBN-13: 978-1437709070 >>

- place redundant tubing into abdomen to allow for future child growth.

Dr. Collins uses trocar technique:
- stab incision with #15 blade (for obese adults may need longer incision).
- use special trocar (**Codman disposable split trocar** – has C shape in cross-section; make sure plastic stylet is locked in place at the end) – advance through subcutis, Scarpa, until feel gritty – it is abdominal muscle aponeurosis; direct trocar cranially and pressing on it down direct it caudally (this way aponeurosis is made taught – it is attached to rib cage) and pop through aponeurosis; continue pressure down (anesthesia gives Valsalva) and pop two more times – get inside peritoneum.
- verify inside peritoneum – saline syringe inject easily in and nothing comes back; plus, catheter is inserted easily without resistance.
- insert catheter (make sure trocar is rotated so C opening faces cranially.
- advance catheter through trocar with DeBakey forceps.

N.B. if there is any *concern regarding placement of peritoneal tubing* (i.e., morbidly obese patient, history of laparotomy and excessive scarring), obtain **KUB** before patient leaves OR.

To minimize infection rate:
- surgical sponges should be avoided
- implants should not be opened from sterile packaging until immediately before use.
- implants should be handled with surgical instruments using "no touch" technique.
- extraneous room traffic should be minimized.
- expedite surgical time from incision to closure.
- keep catheters wrapped in the gauze with bacitracin solution.

N.B. for difficult anatomy / revisions for malpositions – consider intraop verification (air ventriculogram, endoscope, or O-arm).

CLOSURE

- abdominal incision – close peritoneum, fascia, subcutaneous layer, skin.
- scalp – close galea, skin.
  N.B. nonabsorbable monofilament simple running suture to skin minimizes wound breakdown and CSF-cutaneous fistulas, particularly in active child.
  - for kids at VCU: use running 4-0 Monocryl for scalp incision with ± Dermabond* on top.
  - for adults at VCU: use staples for scalp and neck incision.

* Ritter never places Dermabond on scalp!!!!!!!!

N.B. if placing shunt because of unable to wean EVD, pull EVD now but think twice – if patient was ***very sensitive to EVD clamping*** during wean trial (or if ***ventricles dilate significantly even at low level of EVD drainage***), may leave EVD catheter in and clamped and watch patient postop – EVD will work as a safety valve and can be pulled on POD1-2 after postop CT shows good position and no ventricle increase; may also think of installing Rickham reservoir at bur hole (will allow to aspirate CSF and flush with alteplase if system clots off).

REVISION CASES

See below >>

POSTOPERATIVE

- next day:
  1) **head CT** (Ritter*, JRC do not use it) or head US
     *it takes 3-4 months for ventricles to equilibrate to new true baseline size
  2) **plain radiographs of entire hardware system s. shunt series** (Tye does not use it – "if you have concerns, do intraop fluoroscopy"; Ritter may not use as well) - confirm good position + baseline for future.

- wounds should remain dry for at least 3 days postoperatively, until epithelialization has occurred.
- monitor every 6-12 months:
  1) ***head growth*** in infants (occipitofrontal head circumference)
  2) detailed ***funduscopy***
  3) ***distal tubing length*** (with plain radiographs) when child grows.
  4) ***neuropsychological testing*** or ***developmental assessment*** (in younger children)
- although some children cease to need shunt as they become older, determination of this is difficult, thus *shunts are rarely removed*.

CATHETERS

MEDTRONIC RIVULET (41701)

– 141 USD each catheter

ANTIBIOTIC IMPREGNATED

CODMAN BACTISEAL

MEDTRONIC ARES

- impregnated with two antibiotics: **rifampicin and clindamycin** - very low risk of resistance mutation due to dual antibiotics that are hard to resist simultaneously.
- laboratory tests show the catheters provide antimicrobial activity for at least 156 days.

91101 = VENTRICULAR CATHETER (353 USD):

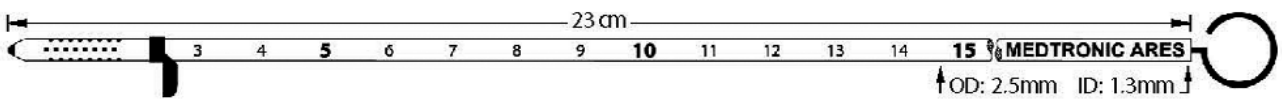

93092 = PERITONEAL CATHETER (353 USD):

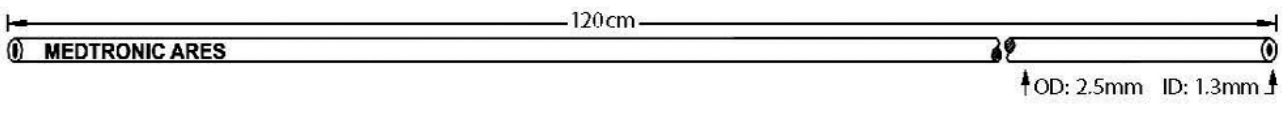

95001 = Kit including both ventricular and peritoneal catheter together (620 USD).

VALVES

CHOICE OF VALVE

Best valve:
NPH: Aesculap ProGAV + Pro ShuntAssist ← does not regulate flow, only prevents siphoning.

Small babies: Codman Certas with SiphonGuard ← regulates flow independent of position.

Bloody CSF (e.g. after SAH) – need the simplest design (most patients don't need shunt after several months): fixed medium pressure valve.

Shunt Design Trial

Drake JM , Kestle JRW , Milner R , Cinalli G , Boop F , Piatt J , Haines S , Schiff S , Cochrane DD , Steinbok P , MacNeil N for the collaborators . Randomised trial of cerebrospinal fluid shunt valve design in pediatric hydrocephalus . Neurosurgery 1998 ; 4 3: 2 94– 3 03.

Standard differential pressure valve versus Delta valve (PS Medical-Medtronic) versus Sigma valve (NMT Cordis).

- 344 pediatric patients (age ≤ 18 yrs), 12 centers in North America and Europe.
- overall shunt failure at 1 year was 39% with all three valves.
- no significant differences in causes of shunt failure between the three valves.
- no significant advantage with any of the three valves.

FIXED PRESSURE

PS MEDICAL DELTA (MEDTRONIC)

Cannot be implanted below ventricle level!

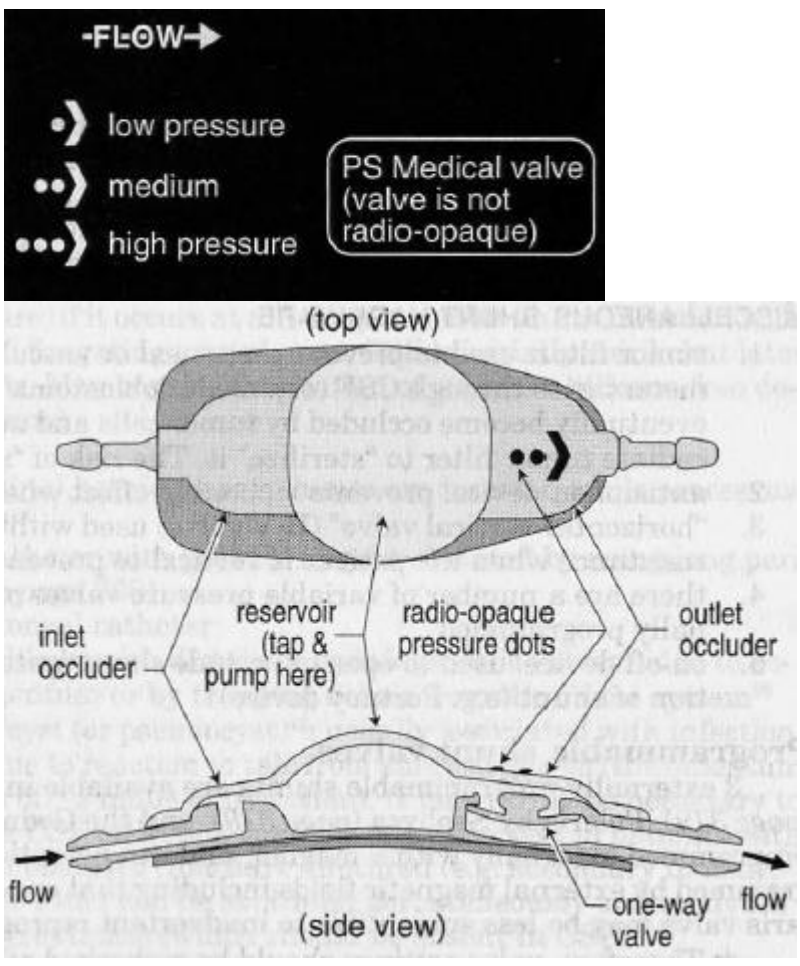

HOLTER valve

(dual slit valve mechanism)

- usually used in combination with Rickham or **SALMON-RICKHAM** reservoir:

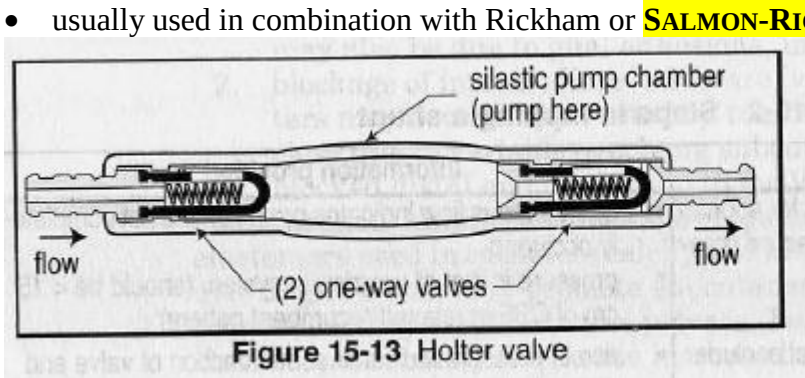

Figure 15-13 Holter valve

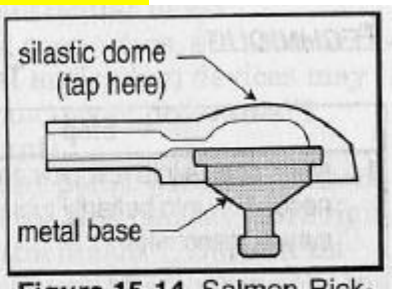

Figure 15-14 Salmon-Rickham Reservoir

HAKIM valve

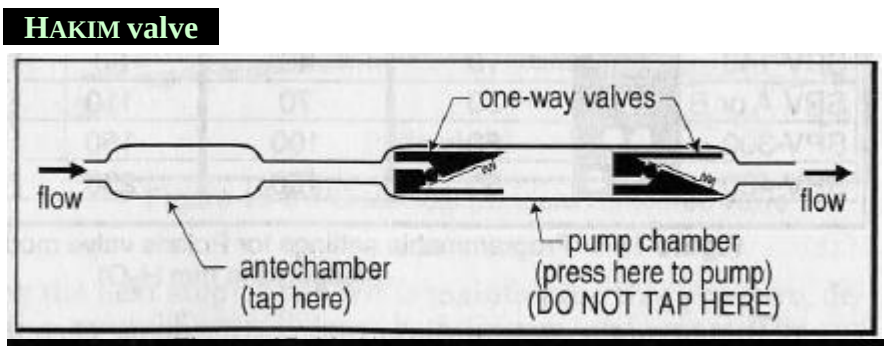

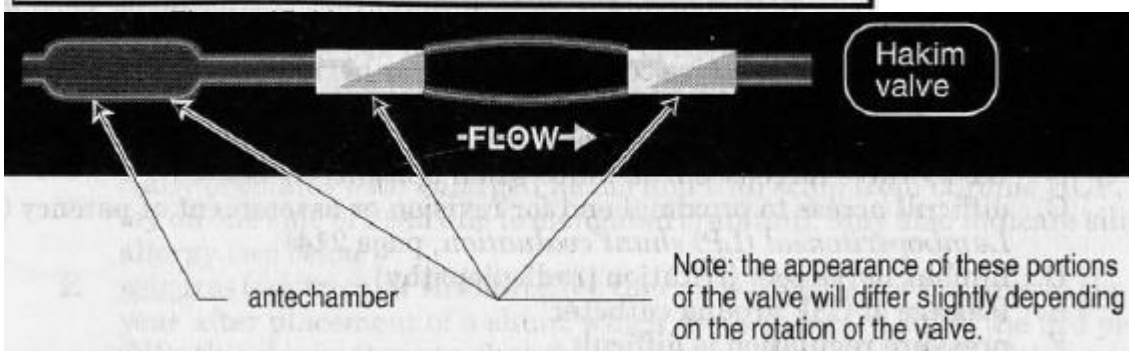

PROGRAMMABLE, NON-MRI-RESISTANT (1ST GENERATION)

PS MEDICAL (MEDTRONIC)

STRATA II

- small and regular sizes:

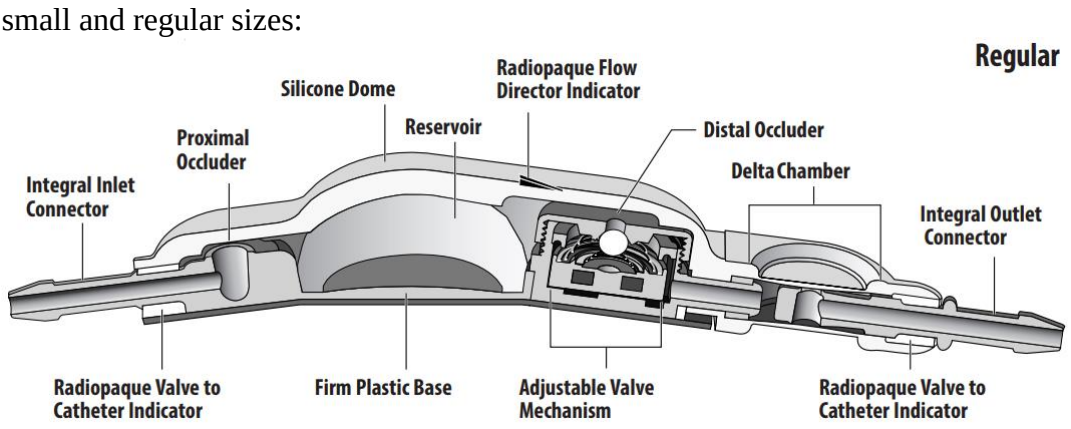

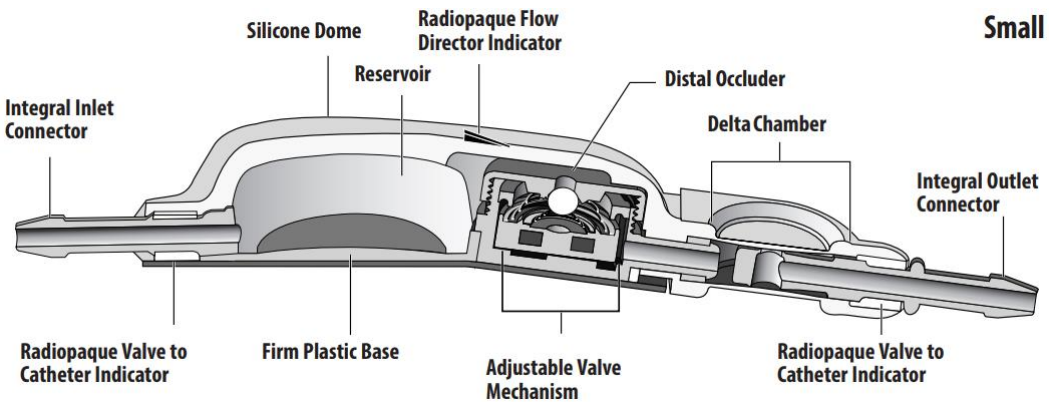

Optional **Delta Chamber** – closed mechanism which opens in response to positive ventricular pressure, but stays closed in response to negative distal pressure – allows pressure in the brain to be maintained within a certain range, regardless of body position – i.e. antisiphon feature.

- MRI up to 3.0 T may be used any time after implantation and will not damage the Strata II valve mechanism, but can change the performance level setting.
- provide the full range of Performance Levels: 0.5, 1.0, 1.5, 2.0, and 2.5:

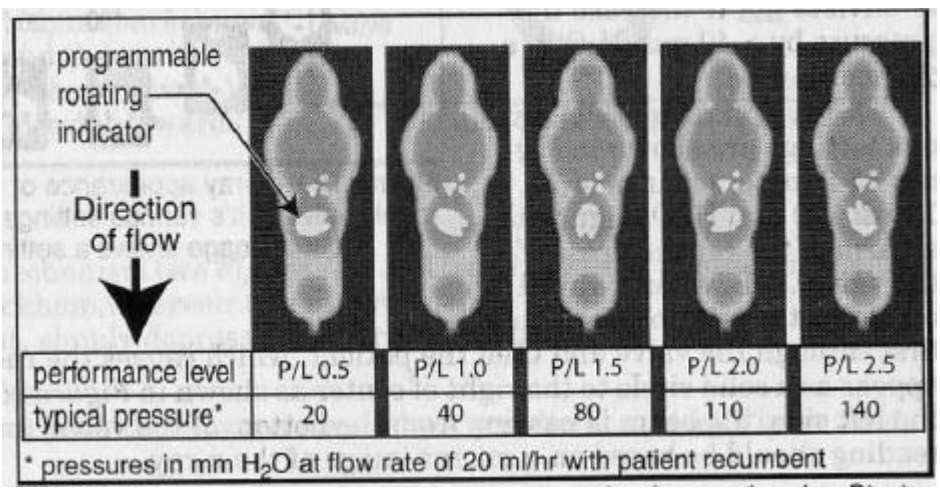

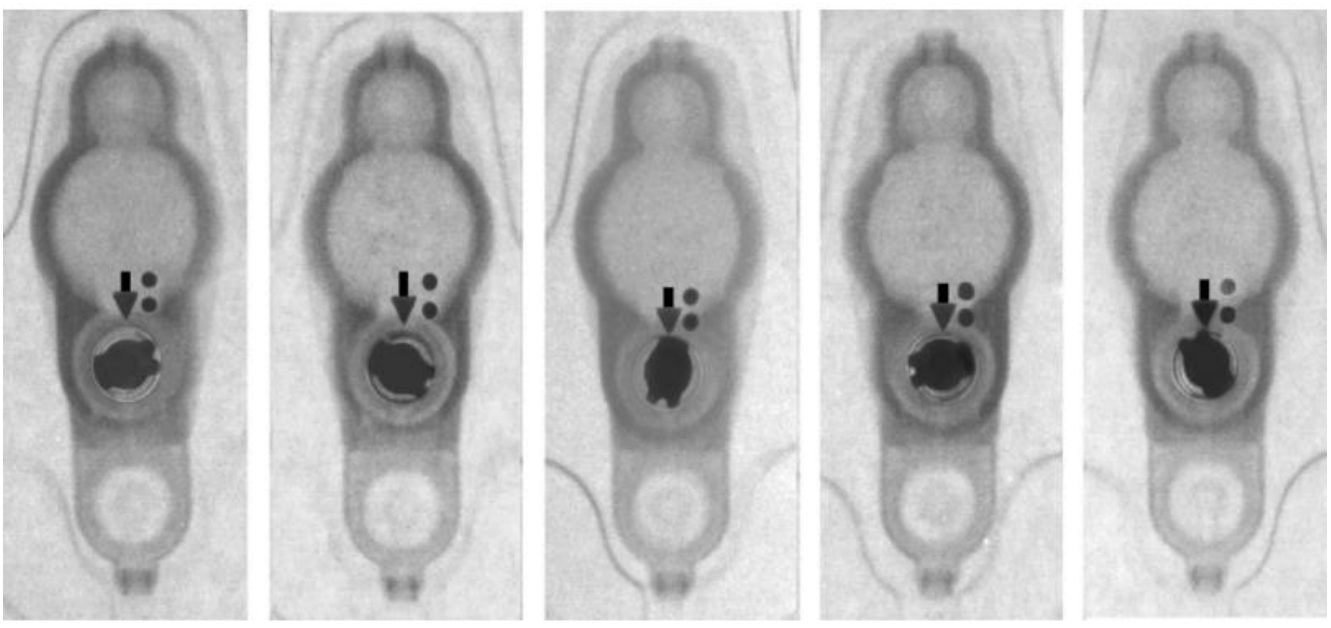

P/L 0.5 P/L 1.0 P/L 1.5 P/L 2.0 P/L 2.5

Strata II Valve Performance at 0 cm H_2O Distal Hydrostatic Pressure

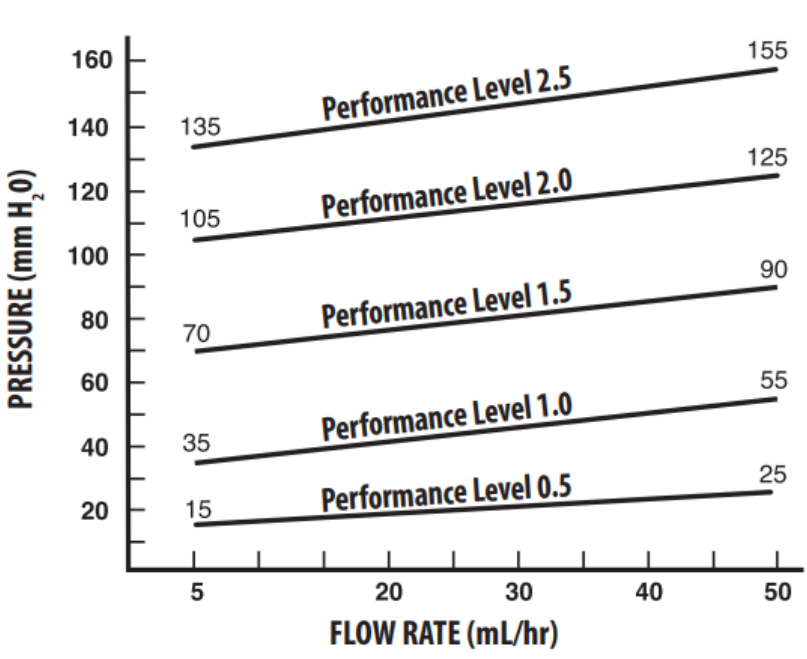

0 cm H_2O HP*

NOTE: Levels depicted are median values. All valves perform within a tolerance range of these median values when tested at time of manufacture as follows:

Performance Level 0.5:
+/- 15 mm H_2O (5 mL/hr)
+/- 25 mm H_2O (50 mL/hr)

Performance Level 1, Level 1.5, Level 2, and Level 2.5:
+/- 25 mm H_2O

*Hydrostatic Pressure

Strata II Valve Performance at -50 cm H_2O Distal Hydrostatic Pressure

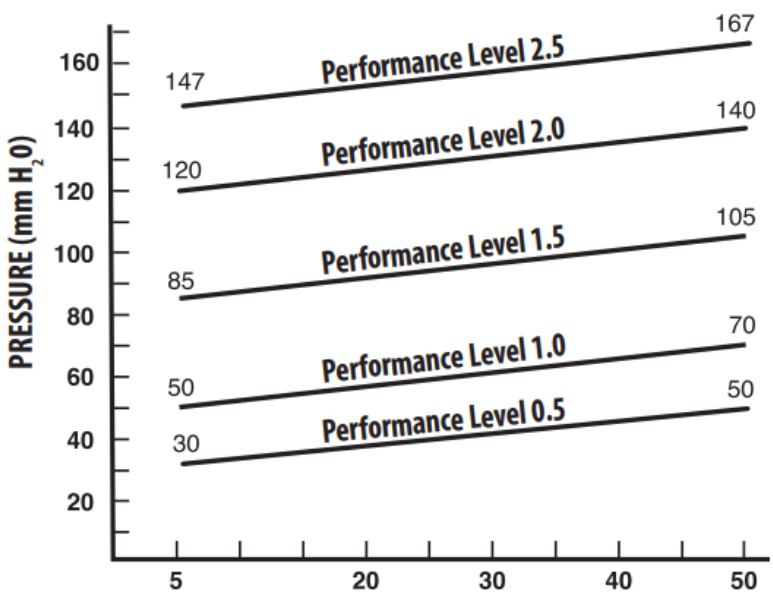

-50 cm H_2O HP*

NOTE: Levels depicted are median values. All valves perform within a tolerance range of these median values when tested at time of manufacture as follows:

Performance Level 0.5:
+/- 25 mm H_2O

Performance Level 1, Level 1.5, Level 2 and Level 2.5:
+/- 40 mm H_2O

*Hydrostatic Pressure

Strata Adjustment Kit:

StrataVarius adjustment system:



Medtronic Strata NSC (non-siphon-control)

CODMAN HAKIM PROGRAMMABLE VALVE

Hakim Programmable Valve >>

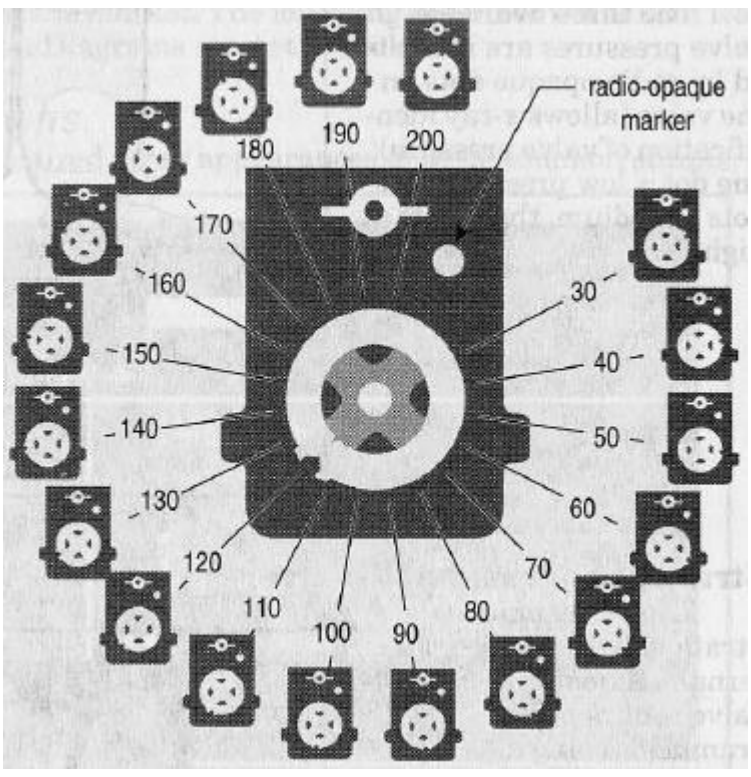

PROGRAMMABLE, MRI-RESISTANT (2ND GENERATION)

AESCULAP

MIETHKE PROGAV

- MRI compatible – do not need valve resetting.
- come preset at 5 cmH2O.
- two metal instruments ("sticks") to adjust valve; approach valve with button depressed – magnet will help to localize valve (may be hidden under scalp edema); valve setting can also be verified on XR.

SHUNTASSIST

ShuntAssist - antisiphon device choice according to patient height:

≥ 6 feet – 30 cmH2O
5-6 feet – 20 cmH2O
≤ 5 feet – 10 cmH2O.

ProSA – programmable antisiphon device.

- needs to be implanted in strictly vertical position – closes system when in vertical position and, thus, prevents siphoning.

CODMAN

CODMAN CERTAS PLUS

CERTAS Plus MRI Resistant Valve >>

1. A range of 8 settings including a 'Virtual Off' (Virtual Off ensures operating pressure setting 8 is consistently greater than 400 mm H20); can be adjusted and verified at bedside!
2. MRI Resistant up to 3 Tesla
3. Has flow regulating unit – spiral tiny canal – opens when pressure differential suddenly increases; N.B. it is more than just antisiphon device (prevents CSF overdrainage when distal pressure drops in vertical position), as it also prevents CSF overdrainage when proximal pressure suddenly increases (e.g. when child cries – CSF dump would cause slit ventricles); thus, "SiphonGuard" is a misnomer – it is more than just a guard against siphoning, it is a true **flow regulator**!
4. Position INDEPENDENT - can be placed anywhere (occipital, frontal, retro auricular, sub clavicular)
5. Has model with UNITIZED BACTISEAL Distal Catheter

CERTAS Plus Inline Valve with SiphonGuard Anti-Siphon Device:

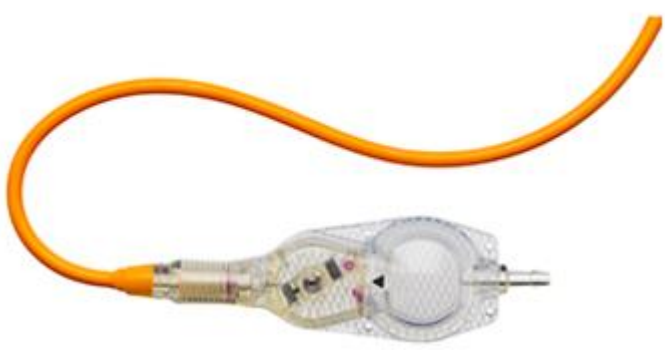

CERTAS Plus without the SiphonGuard Device:

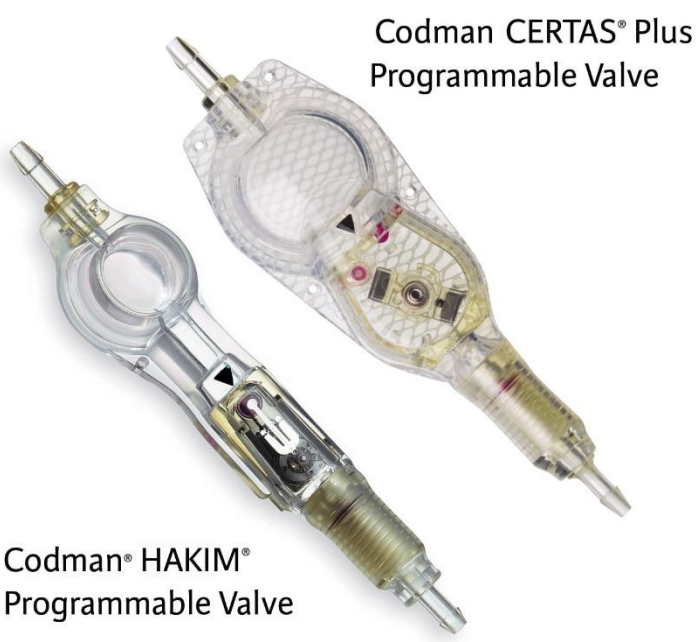

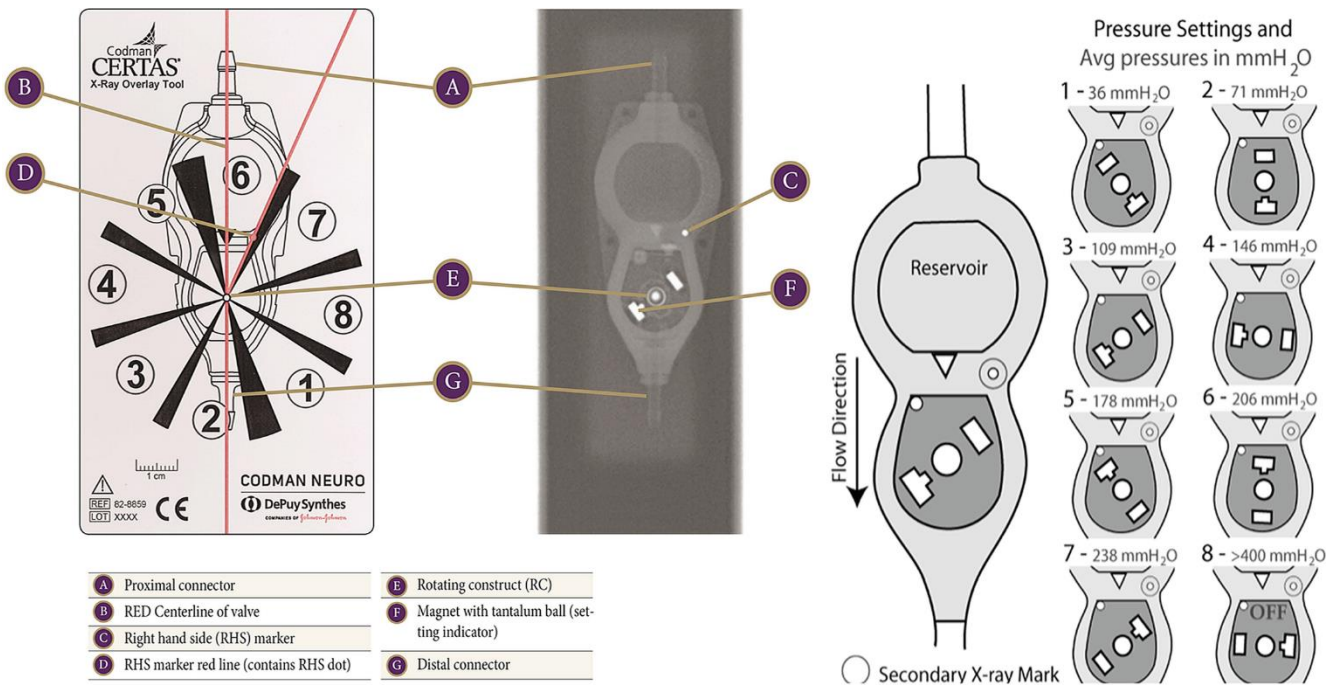

SOPHYSA

Polaris

MRI resistant up to 3T!

Valve	SPV-140	SPV	SPV-300	SPV-400
Identification of the pressure range	0 dot	1 dot •	2 dots ••	3 dots •••
X-ray identification of the pressure range				
mmH_2O	10-140	30-200	50-300	80-400

Direction of flow ↓	Radiopaque dots	Position 1 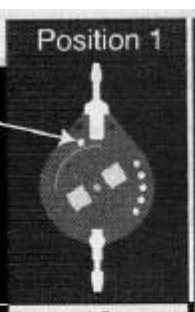	Position 2 	Position 3 	Position 4 	Position 5 
Model						
SPV-140	none	10	40	80	110	140
SPV A or B	●	30	70	110	150	200
SPV-300	●●	50	100	150	220	300
SPV-400	●●●	80	150	230	330	400

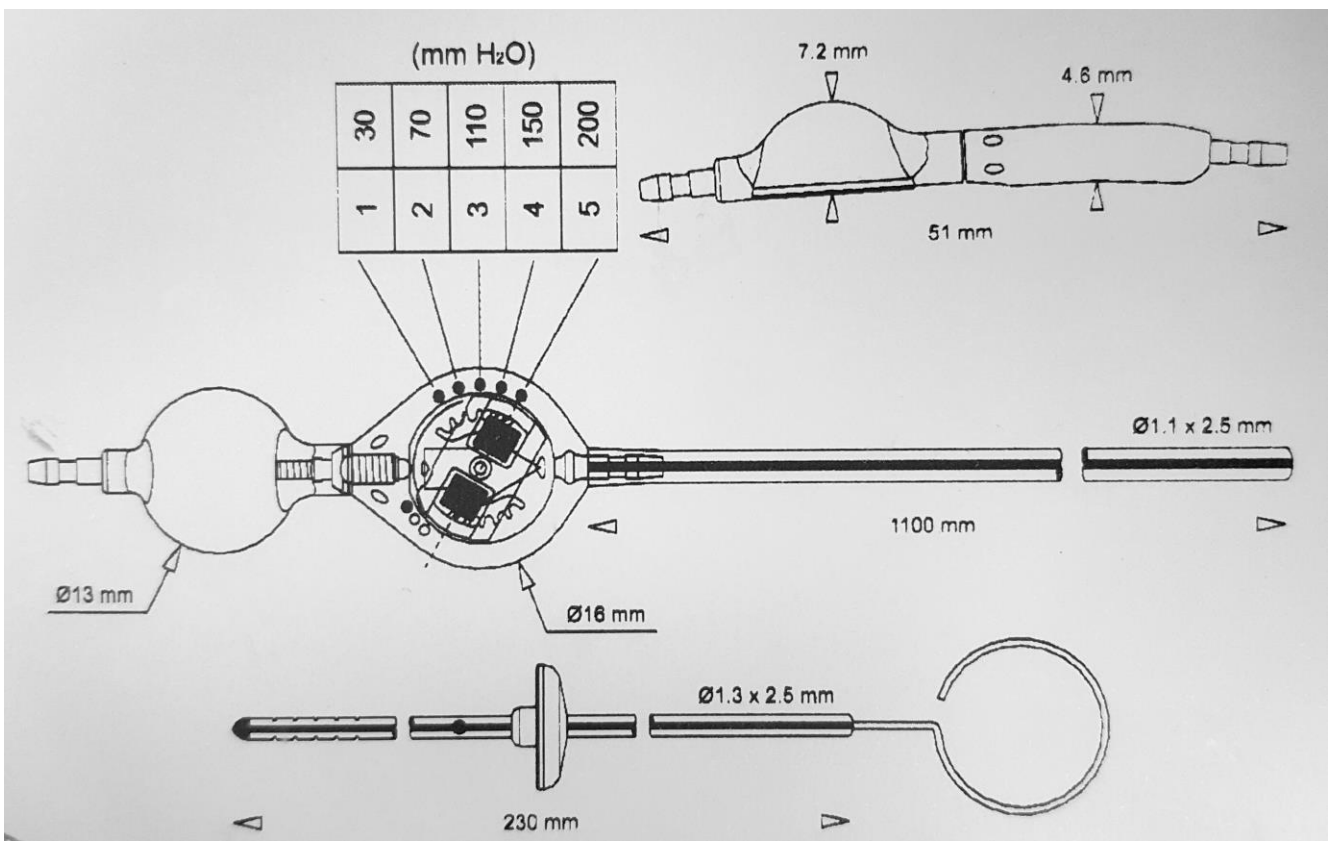

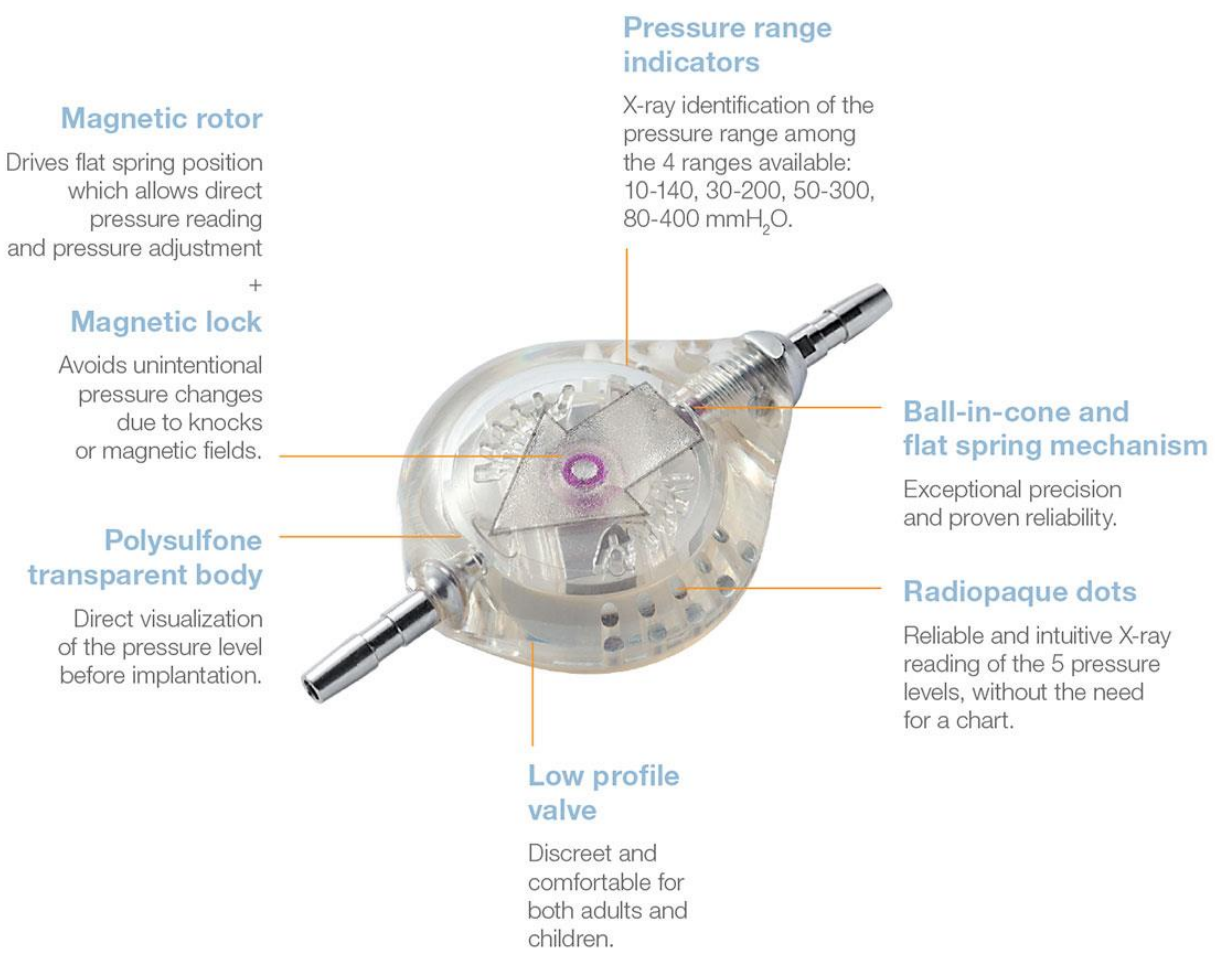

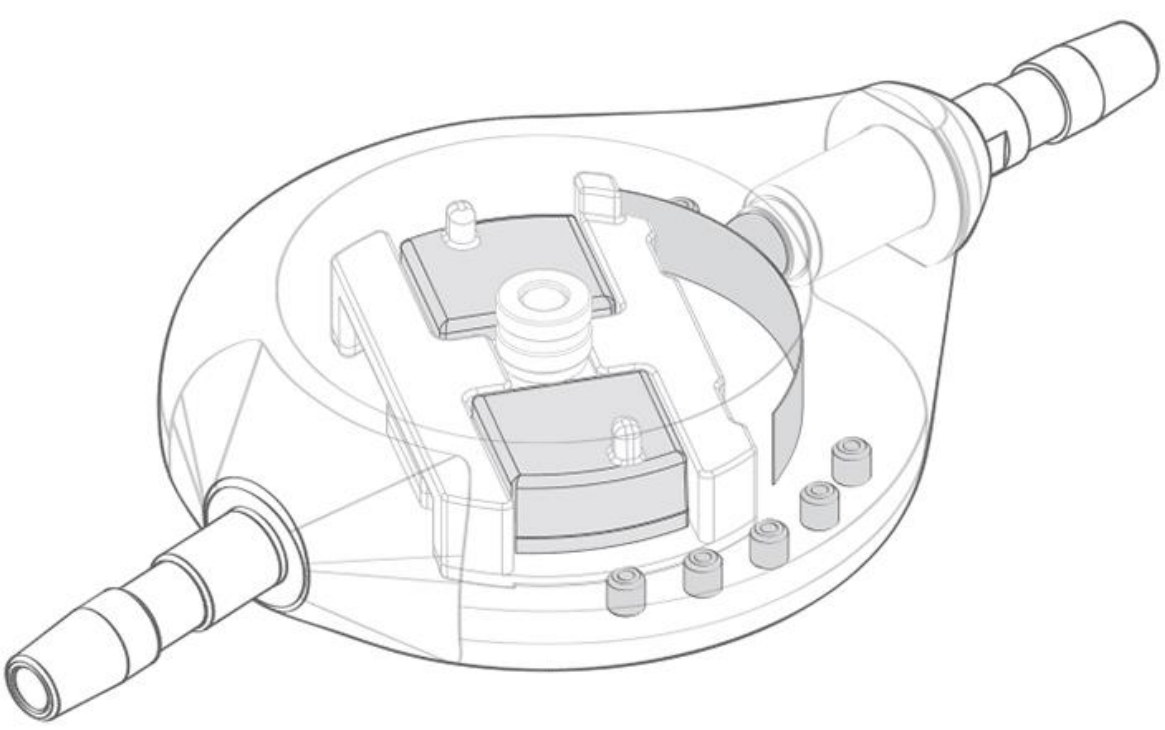

SIPHONX

The Polaris® valve can be associated with SiphonX®, an anti-siphon device, which adds 200 mmH2O in vertical position:

	Reference	Designation
	SX-200	Gravitational anti-siphon device SiphonX®
	SPV-SX	Polaris® Adjustable Valve, 30-200 with SiphonX®
	SPV140-SX	Polaris® Adjustable Valve, 10-140 with SiphonX®
	SPVA-SX	Polaris® Adjustable Valve, 30-200, Antechamber and SiphonX®
	SPVA140-SX	Polaris® Adjustable Valve, 10-140, Antechamber and SiphonX®

- tantalum weight ball presses on a ruby ball, which occludes the aperture for the passage of the CSF - when SiphonX® is in the ***vertical*** position, the ruby ball is subjected to the full weight of the tantalum ball, occludes the anti-siphon aperture and the device adds 200 mmH2O to the operating pressure of the valve; when SiphonX®is in the ***horizontal*** position, the ruby ball is not subjected to the weight of the tantalum ball and so does not occlude the aperture of the anti-siphon device (i.e. in horizontal position, the device is open and does not add any additional resistance to the operating pressure of the valve); for all ***intermediate*** positions, SiphonX® adds a resistance which depends on the angle of inclination.
- by design SiphonX®is not affected by the implantation height relatively to cerebral ventricles.

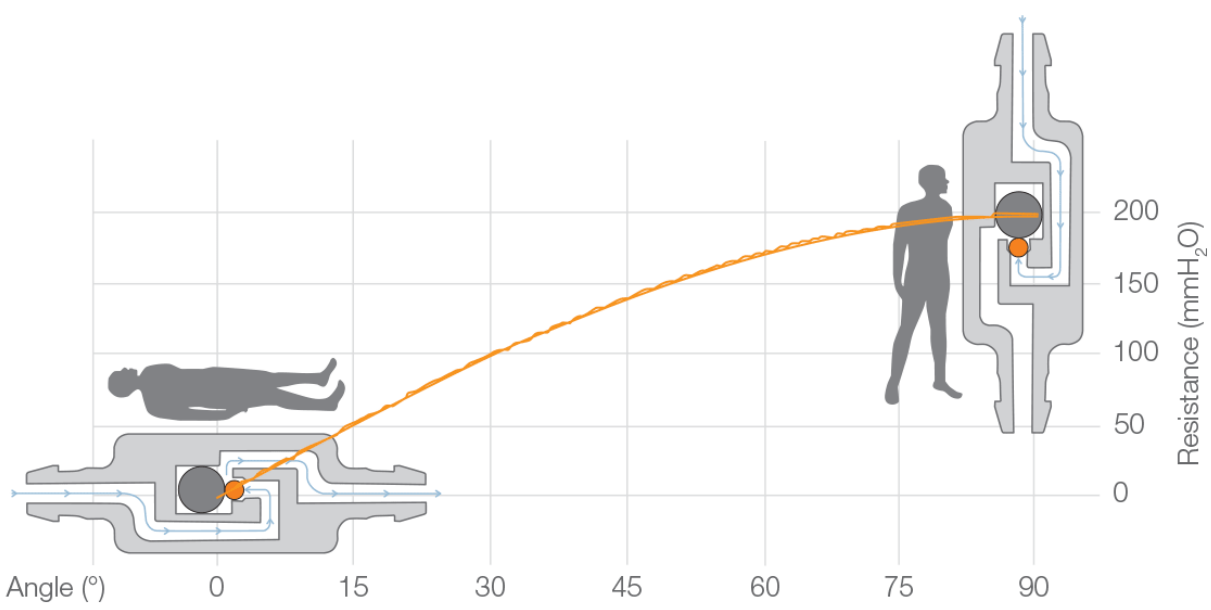

Sophy® Mini SM8

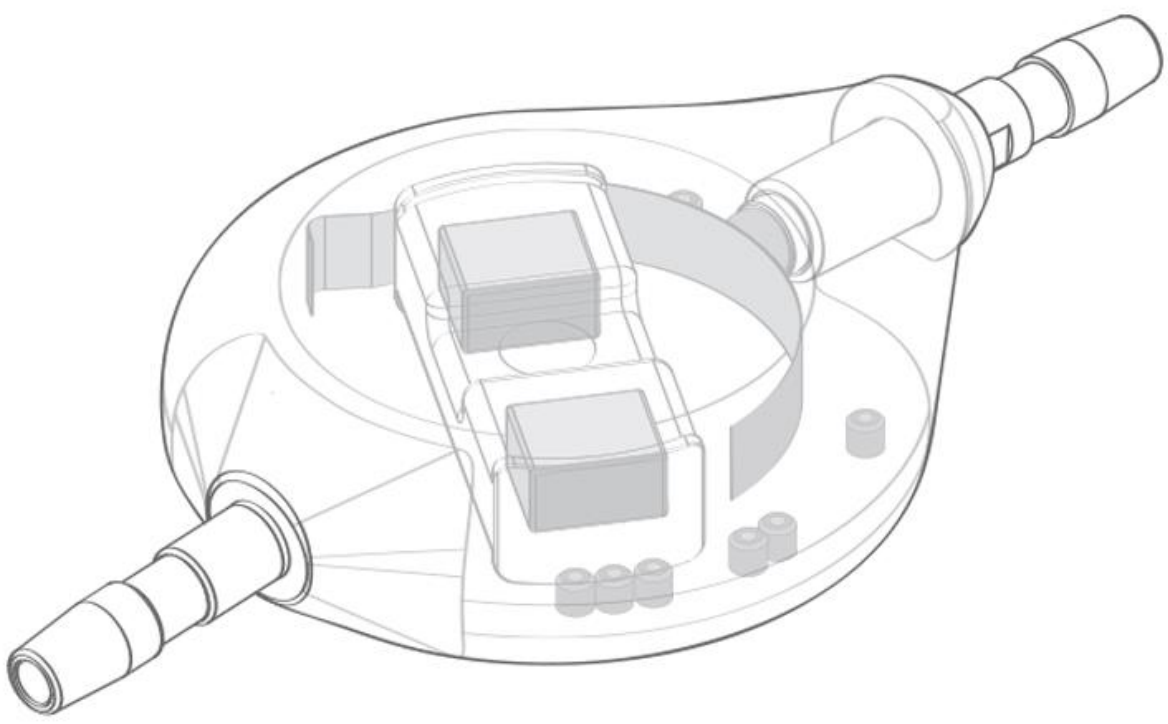

Programming

1 - Operating pressure range visible on Locator MUST match valve range:

2 - Valve location should determine optimum patient position for adjustment.
Having valve horizontal is recommended.

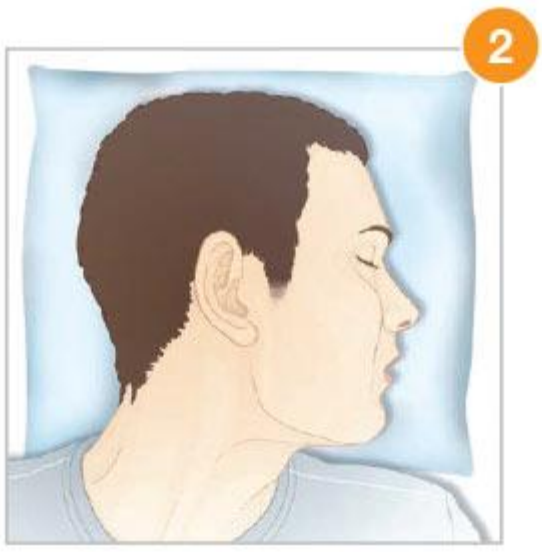

3 - Position Locator parallel to valve, with valve seated in center cut-out, and green arrow pointing in direction of CSF flow path, aligning Locator with valve axis.

4 - Place Compass within Locator.

5 - Adjust Locator orientation, in same horizontal plane as valve, so that Compass needle centers within white target circle, and aligns with current operating pressure setting. Note the valve's current operating pressure setting.

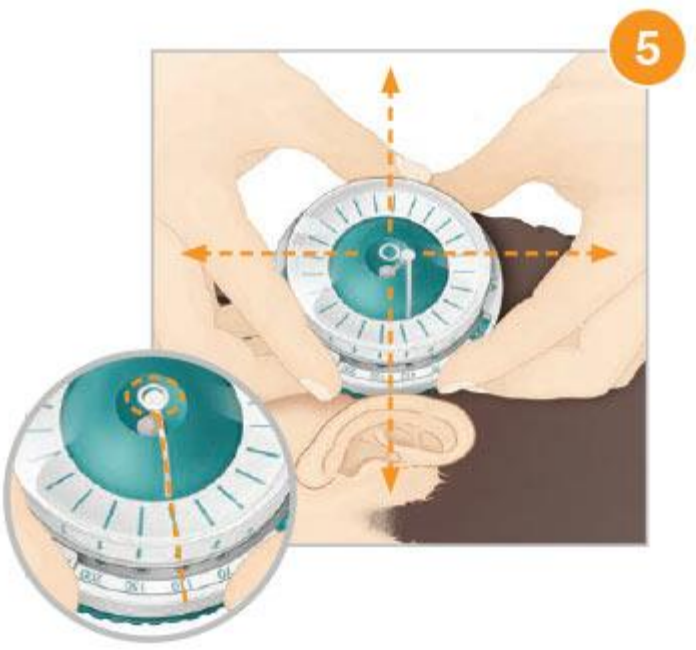

6 - Without moving Locator, remove Compass, then insert Magnet, with center line of Magnet aligned with current operating pressure setting.

7 - Without moving Locator, quickly slide Magnet, with back and forth motion, along the current operating pressure setting axis. With Magnet again centered inside Locator, turn magnet slowly, just beyond the highest or lowest operating pressure setting, whichever is furthest from the initial operating pressure setting.

Without moving Locator, remove Magnet vertically, and place Magnet 0.5 meters away from valve, then insert Compass into Locator. If Locator orientation is accurate, Compass needle aligns exactly with the highest or lowest operating pressure setting, providing a reference point for calibration of the Locator along the valve's axis. If the Compass needle does not align exactly with the highest or lowest operating pressure setting, re-calibrate Locator, by turning it slightly, in same plane as valve, until the Compass needle does align exactly with the highest or lowest operating pressure setting.

8 - Without moving Locator, remove Compass, then re-insert Magnet, with center line of Magnet aligned with current (highest or lowest) operating pressure setting. Without moving Locator, quickly slide Magnet, with back and forth motion, along the current operating pressure setting axis, and, with Magnet once again centered inside Locator, turn Magnet slowly to new operating pressure setting.

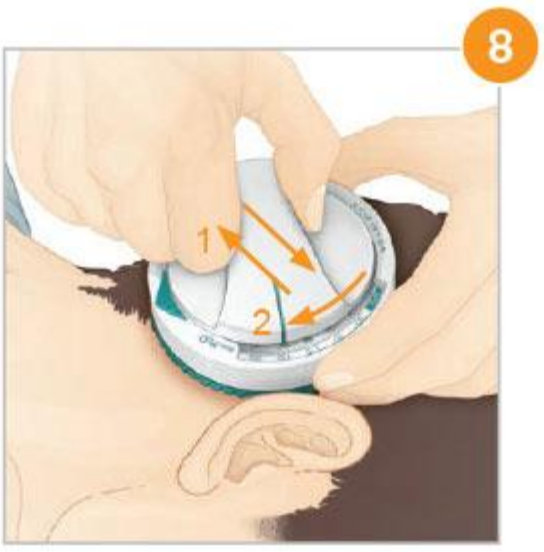

9 - Without moving Locator, remove Magnet vertically (place Magnet 0.5 meters away from valve).

10 - Without moving Locator, re-insert Compass, confirming that needle aligns with new operating pressure setting.

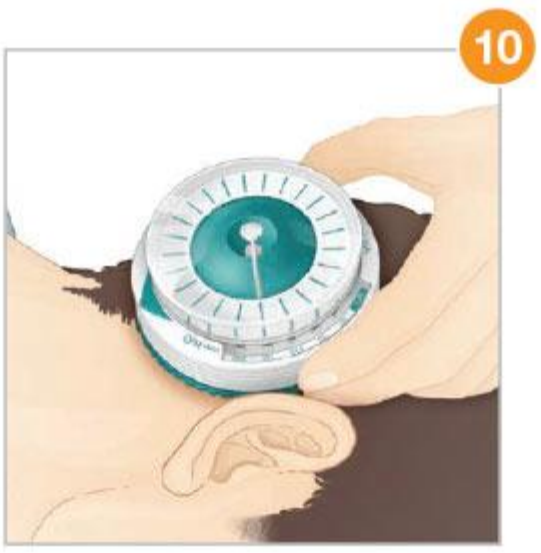

ANTI-SIPHON FEATURE

- prevents overdrainage in vertical position (i.e. keeps intraventricular pressure within physiological range when patient is upright) – especially for tall slender elderly people (brain atrophy predisposes to SDH from overdrainage). Caution in obese people – may impede CSF flow.

Codman Certas with SiphonGuard – spiral canal opens when pressure differential suddenly increases - regulates flow independent of position (i.e. not just anti-siphon as also prevents overdrainage due to sudden ICP increase); Position INDEPENDENT implantation

Sophysa SiphonX – true anti-siphon device, which adds 200 mmH2O in vertical position

Aesculap ShuntAssist – must be implanted in strictly vertical position
Aesculap ProSA - programmable

Medtronic valves with **Delta Chamber** (e.g. Strata valves) – closed mechanism which opens in response to positive ventricular pressure, but stays closed in response to negative distal pressure – allows pressure in the brain to be maintained within a certain range, regardless of body position – i.e. antisiphon feature.

VALVES WITH NO ANTI-SIPHON FEATURE

Medtronic Strata NSC (non-siphon-control)

VENTRICULO-PLEURAL SHUNT

- perform early postoperative chest radiograph - large effusions can occur in short periods (→ respiratory problems), esp. in children < 10 yo.

VENTRICULO-ATRIAL SHUNT (VAS)

a) into **INTERNAL JUGULAR** using Seldinger technique – IR (interventional radiologist) places guidewire as if placing central line → pass peel-away sheath over it → tunnel catheter into neck and exit at guidewire skin entry site → flush entire shunt system with heparinized saline → insert distal catheter into **atrium-SVC junction** (use XR to verify).
b) into **FACIAL VEIN** – incision parallel and 2 fingerbreadths below mandible (at the angle).
– ligate distal venous inflow.
– obtain control of proximal vein (pass silk loop), longitudinal incision, insert "hockey stick" (yellow) shunt passer into vein → flush distal catheter (special **VA** [needs stepdown connector due

to smaller diameter] or **Bactiseal**) with heparinized saline → advance catheter into IJ until it is at **atrium-SVC junction** (use XR to verify) → tie lightly silk loop (holds catheter in place and stops venous bleeding).

- consider preop cardioECHO.
- *fluoroscopic guidance* - to prevent catheter thrombosis (short distal catheter) or cardiac arrhythmias (long distal catheter).
- additional tubing cannot be inserted to allow for growth – anticipate electively scheduled VAS lengthening procedures (educate patient parents about it!).
- complications are serious - renal failure (shunt nephritis), great vein thrombosis & pulmonary embolism, septicemia, cardiac arrhythmia, pulmonary hypertension, and even atrial perforation and cardiac tamponade have been reported.
- historically, VAS was 1st choice over VPS until polyethylene distal catheters were replaced by silicone distal catheters – choice shifted back to the peritoneum as the preferred terminus for CSF reabsorption in 1970s.

VPS vs. VAS

Rymarczuk et al. A Comparison of Ventriculoperitoneal and Ventriculoatrial Shunts in a Population of 544 Consecutive Pediatric Patients. Neurosurgery, Volume 87, Issue 1, July 2020, Pages 80–85

- retrospective analysis
- 544 pediatric shunt patients (459 VPS and 85 VAS) followed for at least 90 d (VPS: 5.9 yr; VAS: 5.3 yr).
- **VPS** has significantly greater survival in patients < 7 yo (P = .001), but showed no difference in older children (P = .4), more frequent shunt infection (4.0% vs 0.01% VAS; P < .05).
- **VAS** had a significantly lower rate of infection (P < .05) and proportion of proximal failure as a reason for shunt failure (29% vs 53% with VPS, P < .001).
- no statistical difference in rate of distal catheter failure (P = .08) or valve malfunction (P = .9).
- complications related to placement occurred at a rate of 5.5% VPS vs 3% VAS.
- no mortality attributed to shunt insertion.
- 54% of VPS and 60% of VAS required at least 1 revision. VPS demonstrated superior survival overall; however, if electively scheduled VAS lengthening procedures are not considered true "failures," no statistical difference is noted in overall survival (P = .08):

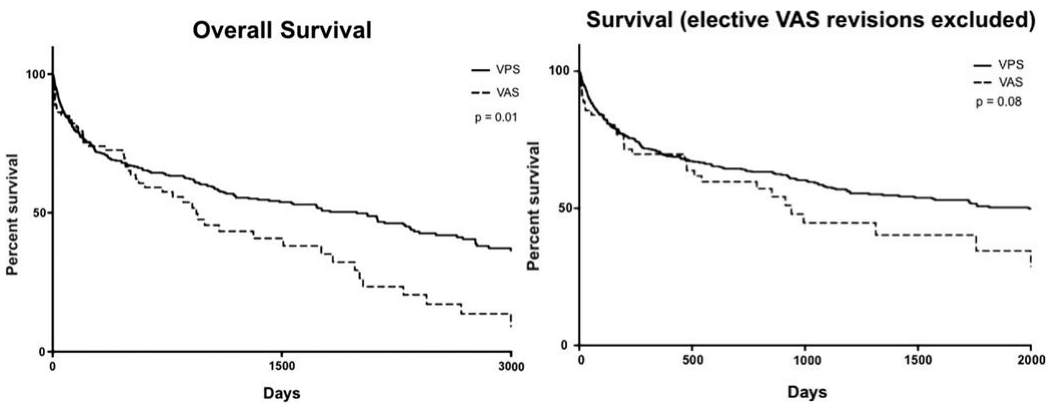

Authors, Year	Population	Findings	Conclusions
Ignelzi and Kirsch, 1975	300 adult and pediatric patients.	VAS required fewer revisions: 58% vs 48%.Infections occurred 1.6x as frequently in VAS.	VPS exhibited a trend towards more revisions being necessary. VAS was prone to more serious complications. **VPS** is preferable due to ease of insertion and more favorable complication profile.
Keucher and Mealey, 1979	288 pediatric patients with nontumoral etiologies.	22% overall rate of infection.97% of VAS vs 62% VPS required revision at last follow-up.	If a child reaches 5 yr of age without a shunt infection, **VPS** performs better than VAS (41% vs 17% nonrevision rate).
Mazza et al, 1980	165 pediatric patients.	VAS associated with greater morbidity.45.8% vs 51% revision rate in favor of VAS.Greater reliability of VPS overall.	**VPS** is preferable to VAS due to greater morbidity from VAS.
Borgbjerg et al, 1980	884 adult and pediatric patients.	Statistically greater rate of VAS revision (51 vs 38.5).Trend towards greater durability of VPS.Rate of revision declined with age: 69% in infants, 31% in adults.	Young children are the most likely to require revision. Pudenz shunts are less durable than Hakim models. VPS may not be superior in all facets due to patient variables.
Lam and Villemure, 1997	122 adults with NPH and carcinomatous meningitis	Overall complication rate of 40.5%, including 2 deaths.2.5% infection rate.Distal failure rates: 4.6% VPS, 6.8% VAS.	**VPS** is preferable due to ease of insertion and lower morbidity.

VENTRICULO-GALLBLADDER SHUNT

- check HIDA scan to make sure bladder empties.
- purse string suture on fundus.
- cut catheter and use straight connector where catheter goes through bladder wall – prevents dislodgement (→ bile peritonitis).

VENTRICULO-SUBGALEAL SHUNT

- temporary measure until newborn reaches 2 kg for a permanent VPS.
- repeated trans-fontanel taps – too high risk of infection

SHUNT REVISION

- prep entire system – may need to open abdomen.
- ***open scalp incision at valve and proximal catheter junction***, medial* and parallel to the valve (blue – old scar; red – current incision):

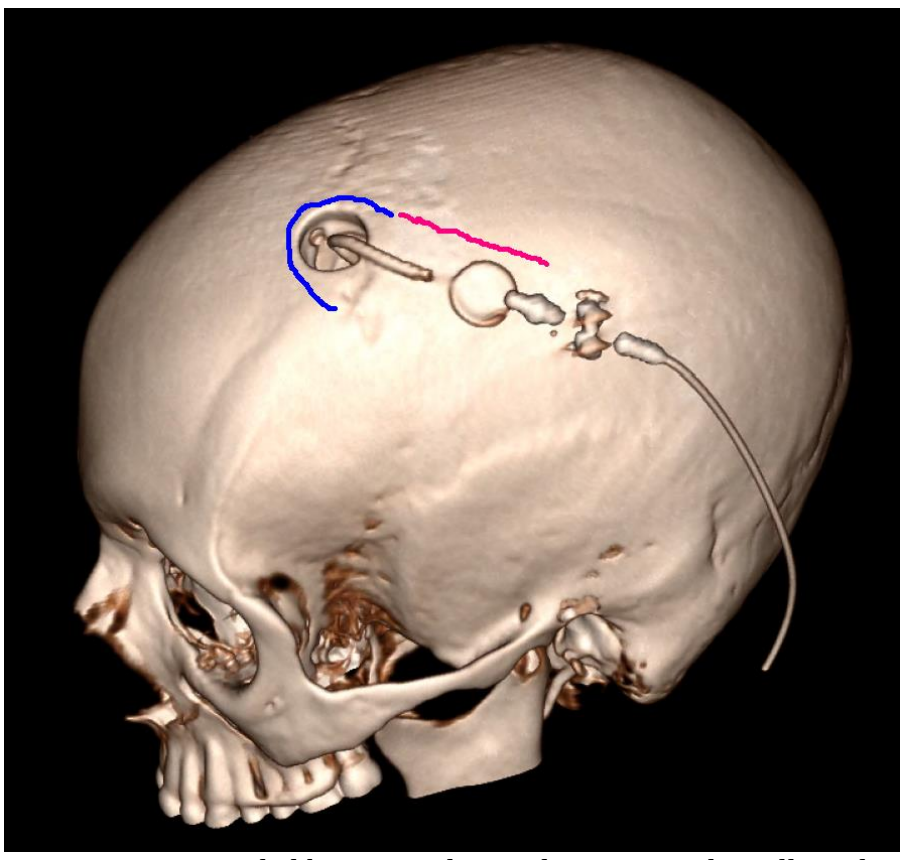

*medial because valve tends to migrate laterally and you want to keep valve away from healing incision

- check for CSF egress from proximal catheter.
- attach 14G Angiocath* to valve, then attach 3-way stopcock and manometer with saline syringe: fill manometer with saline, check for runoff through valve and distal catheter (may gently flush distally but not too forcefully – may damage valve mechanism).

  *alternative - use blunt needle and small piece of catheter on valve inlet

- if distally no flow, ***extend cranial incision alongside of valve*** – can reach valve in situ – check distal runoff on catheter.
- replace obstructed component.
  - if unable to retrieve proximal catheter (stuck in parenchyma or with choroid plexus ingrowth), either leave it or insert Bugbee monopolar cautery and coagulate inside catheter lumen all catheter holes by advancing wire inside catheter (error to insert stylet and coagulate on it – electrical current is diverted through proximal hole!).
- replacing ventricular catheter – *never soft pass* (catheter easily gets deflected).

VENTRICULAR ENDOSCOPY

Pending
Jandial, procedure 47

Dr. Collins, Dr. Ritter sometimes use Stealth navigation and pin patient into Mayfield

for infants – use Mayfield Infinity system – very shallow pins (Dr. Ritter always uses adult pins regardless of age) – just keep head steady without skull perforation while head weight rests on horseshoe.

- establish scalp entry point with navigation
- open skin:
  a) simple slit incision
  b) in horseshoe and pericranium in horseshoe in opposite direction (at the end will help to seal CSF leak)
- drill skull hole with matchstick just large enough to fit introducer sheath and perfectly aligned to trajectory.
- use "Dr. Collins' shunt passer" (hollow metal tube with attached SureTrak) to align to trajectory and pass Becker catheter to ventricle (note beforehand how deep catheter should go from shunt passer tip, then note were is stop mark on Becker catheter flush to shunt passer's port edge).
- remove Becker stylet and shunt passer.
- use 10F peel away introducer sheath (remove plastic stylet) – advance it over Becker catheter into ventricle; remove Becker catheter; some attendings would staple peel away sheath arms to scalp (Dr. Collins does not like it).
- use endoscope (continuous irrigation with warm (!!!) Lactated Ringer solution);
  about endoscopes – see p. Op140 >>
- align endoscope to 12 o'clock, adjust focus and white balance.
- select on camera "Flexiscope".
- monopolar cautery:
  1) soft, blunt ended (Bugbee) to coagulate – ***touch an twist*** (helps to shrink membranes).
  2) stiff and sharp ended
- hemostasis may be achieved with monopolar cautery and vigorous irrigation (to verify hemostasis, pinch irrigation hose to stop irrigation – watch for blood wisp in CSF).
- at the end, put dry Gelfoam (squeezed into cone) through the sheath – to plug parenchymal path and bur hole – to minimize CSF leak.
- postop – HOB up.

ENDOSCOPIC THIRD VENTRICULOSTOMY (ETV)

Pending video:
https://expertconsult.inkling.com/read/schmidek-sweet-operative-neurosurgical-quinones-6th/videos/chapter-96-video-1---endoscopic

ETV may not work if patient has extensive metastatic deposits in subarachnoid spaces (absorptive capacity↓) H: regular VP shunt.

Classical bur hole site – just in front of the right coronal suture, in midpupillary sagittal plane (allows straight trajectory via right lateral ventricle to foramen of Monro).

- use sharp **monopolar probe** (without cautery current) to perforate 3rd ventricular floor in several spots just anterior to mamillary bodies; then keep **Fogarty catheter ballon** inflated a little bit for hemostasis and tissue hole expansion (use 0.2 mL then may add 0.75 mL balloons); ± use microforceps to remove tissue debris.

  N.B. do not go too anterior – will damage pituitary stalk and cause DI!
- then advance Fogarty catheter – need to perforate Liliequist arachnoid membrane below 3rd ventricle floor – should clearly see dorsum sellae and basilar artery.

  Liliequist membrane – see p. A40 >>
- may use monopolar cautery (Bugbee) to coagulate choroid plexus.
- may place **Ommaya reservoir** with *catheter in ventriculostomy orifice* – keeps orifice open and also gives access to CSF in case ETV fails; alt - may leave clamped EVD in place postoperatively.
- may take *biopsy* during same procedure by endoscopic guidance.
- at the end, may close dura completely with running 2-0 silk.

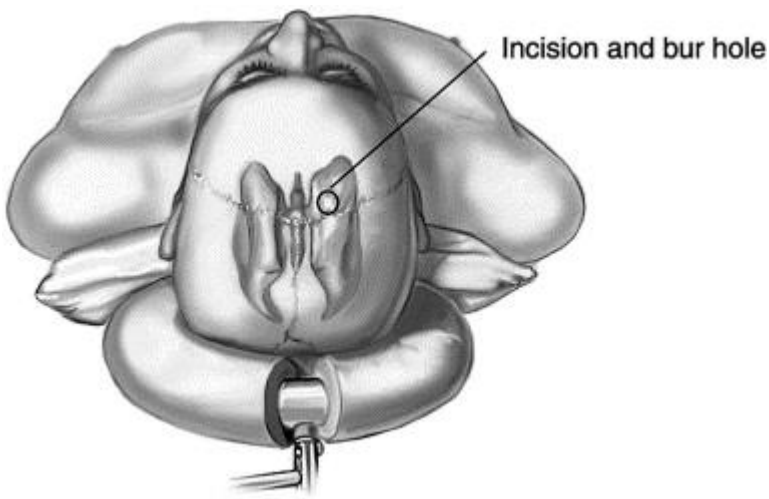

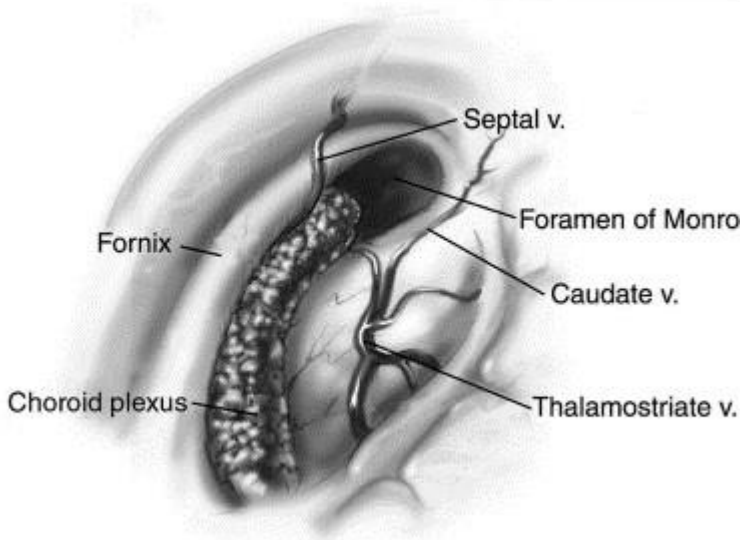

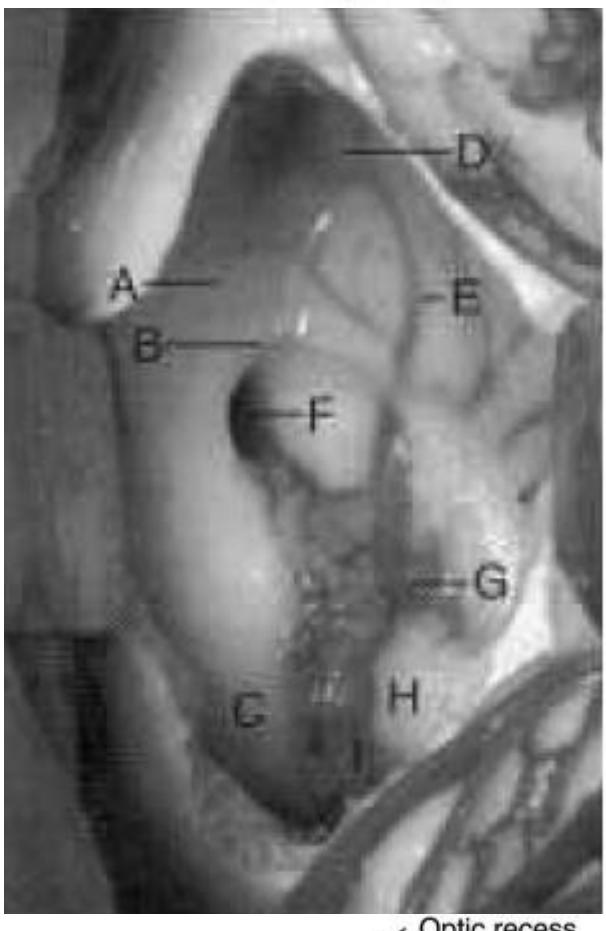

A. Septum pellucidum
B. Column of fornix
C. Body of fornix
D. Caudate nucleus
E. Anterior caudate vein
F. Foramen of Monro
G. Thalamostriate vein
H. Thalamus
I. Choroid plexus

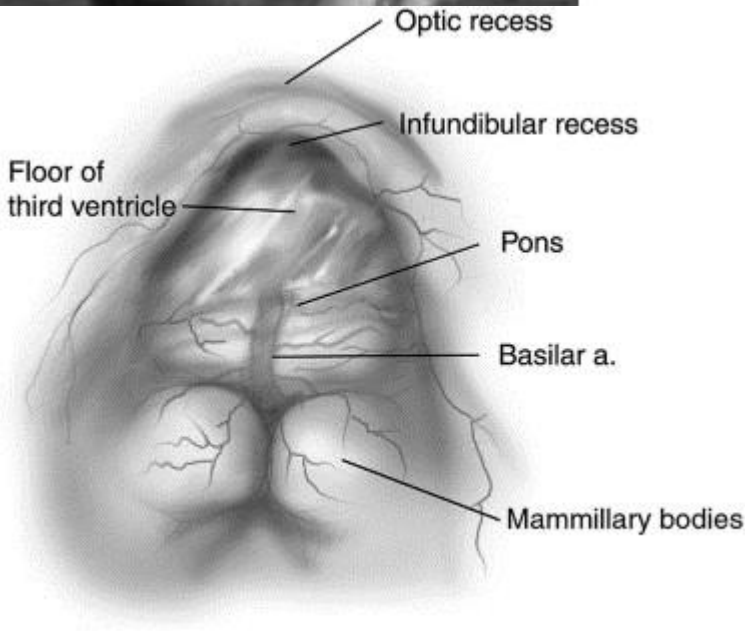

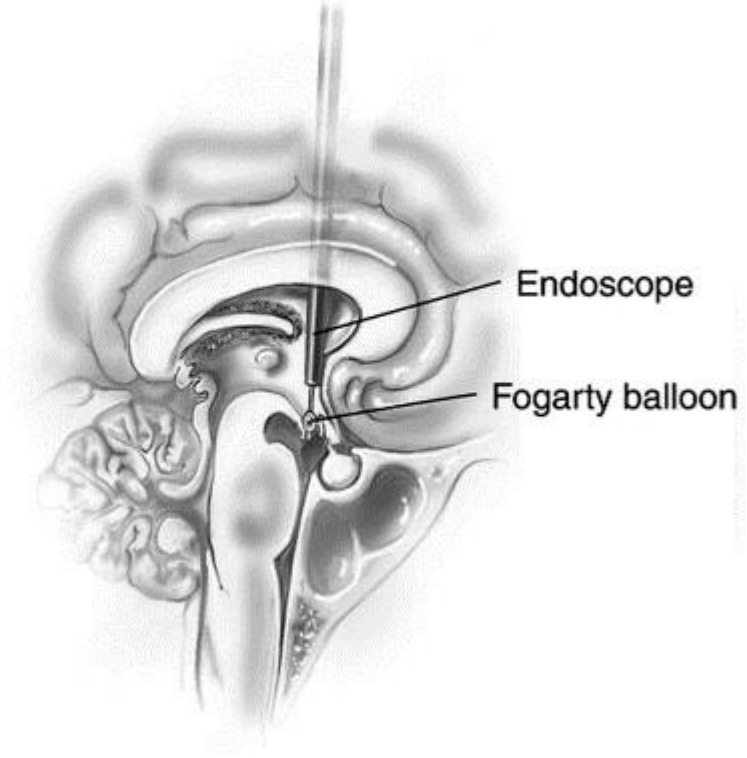

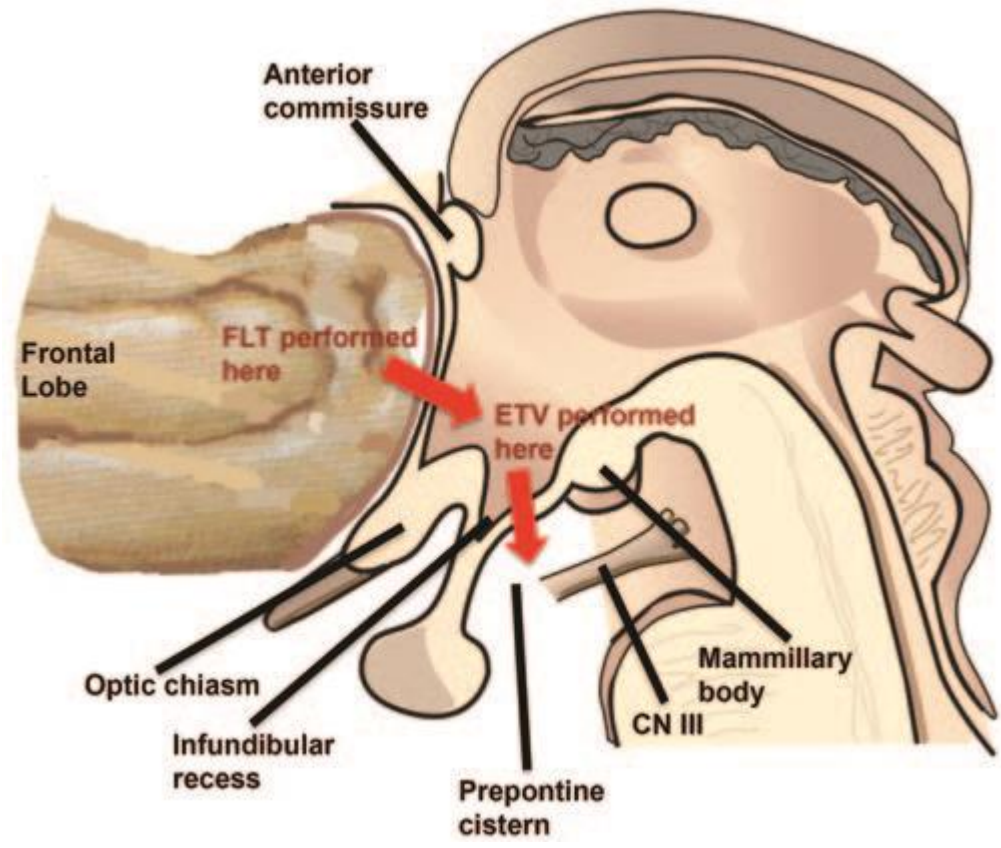

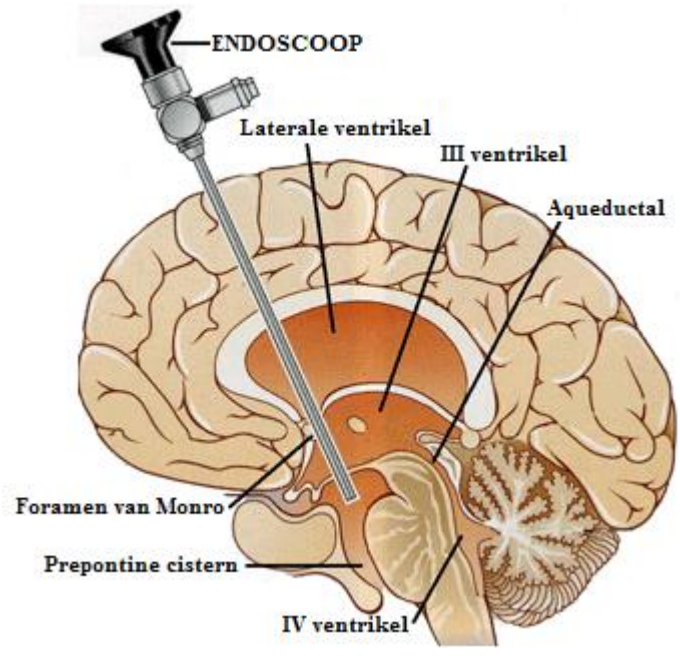

SEPTOSTOMY

Need more lateral bur hole than for Kocher approach (classically – **lateral eye canthus**); use endoscope and Fogarty balloon.

Dr. Collins:

- uses navigation for better orientation (e.g. to avoid injury to fornices) – chose entry and target points so trajectory spans frontal horn (important if ventricles are slit).
- uses SureTrak attached to "Dr. Collins shunt passer" secured in Mitaka robotic arm.
- measure the distance (on Stealth) from Dr. Collins shunt passer tip to target; insert Becker catheter through shunt passer so that exact length exits, then mark Becker at proximal end flush to shunt passer hub; align shunt passer to trajectory and pass Becker; remove shunt passer; advance 10F peel-away sheath (aka introducer) on the Becker catheter; staple peel-away sheath hands to the skin; insert endoscope through sheath.
- locate septum and poke with sharp monopolar tip (use coagulation intermittently) or just mechanically with blunt Bugbee tip; hemostasis with monopolar Bugbee; then insert 2F Fogarty ballon and dilate the opening with balloon (also helps with hemostasis).

LUMBO-PERITONEAL (LP) SHUNT

SPETZLER CATHETER

(Integra™ Spetzler™ Lumbar-Peritoneal Shunt) >>
Pressure control is achieved through combination of *double slit valve* at peritoneal end and small *inner diameter* catheter:

INDICATION

Pseudotumor cerebri

- may consider preop ICP monitoring, LPs with opening pressure measurements.

PROCEDURE

- left lateral position on bean bag.
- use loupes and headlight (usually midline incision sags downward – need to look upwards and no OR light will help).
- sit on chair.
- incise skin in midline over L4 and L5 spinous processes.
- dissect down to fascia.
- 14G Tuohy needle is inserted at L4-5 interspace (under optional fluoroscopic guidance – usually don't need it).
- **Spetzler lumbar catheter** is advanced to lumbar subarachnoid space (if have fluoro available, may inject contrast to verify myelographic effect); place 2-0 silk purse string on fascia around catheter (while needle is still in – protects catheter); suture 1-2 butterfly plastic anchors (around catheter) to fascia.
- good distal CSF egress must be verified (if needed, attach blunt needle and aspirate air bubbles)
- tunnel catheter from spine to abdomen using bent tunneler.
- place into peritoneal cavity (e.g. laparoscopically).
- if using valve (often Spetzler is enough and no valve is needed).
  - create pocket for valve in flank subcutaneous fat with big Kelly clamp
  - tunnel distal **Bactiseal catheter** from spinal incision to lateral abdominal incision

- connect **valve** to Bactiseal
- connect short segment of Bactiseal to proximal valve inlet, then **stepdown connector** (as Spetzler lumbar catheter is of smaller diameter).
- trim Spetzler lumbar catheter short and connect to stepdown connector.
- pull Bactiseal catheter to abdomen while situating valve in pocket.