

# Syringomyelia Surgery (TECHNIQUES)

Last updated: February 16, 2023

SHUNTS..... 1  
 CONTRAINDICATIONS..... 1  
 COMPLICATIONS ..... 1  
 TECHNIQUE..... 1  
     T-tube catheter..... 2  
 OUTCOMES..... 4  
 OTHER METHODS ..... 5

## SHUNTS

- a) *syringoperitoneal*
  - b) *syringopleural*
  - c) *syringo-subarachnoid* (e.g. Heyer-Schulte-Pudenz system) - requires normal CSF flow in subarachnoid space, therefore cannot use in arachnoiditis or not decompressed Chiari malformation
- syrinx diameter must be at least 3-4 mm.

## CONTRAINDICATIONS

- 1) presence of spinal **tumors** (fluid contained within cystic tumors has higher protein content and may not flow through system)  
 Any spinal cord lesion which contains anything other than clear, colorless fluid should be examined carefully for evidence of associated tumor!
- 2) **infections** along course of shunt (meningitis, ventriculitis, skin infections, bacteremia, septicemia or peritonitis).

## COMPLICATIONS

- 1) may produce **traction on spinal cord** with potential for further injury; 10% incidence of **posterior column dysfunction** with shunting  
 N.B. risk of iatrogenic neurologic worsening!
- 2) shunt associated, low-grade **peritonitis** - obscure fever, gram-negative ventriculitis occurs, recurs, or persists
- 3) if peritoneal catheter becomes **disconnected**, peristaltic action may draw catheter into abdominal cavity.
- 4) prone to **obstruction**: 50% at 4 years

## TECHNIQUE

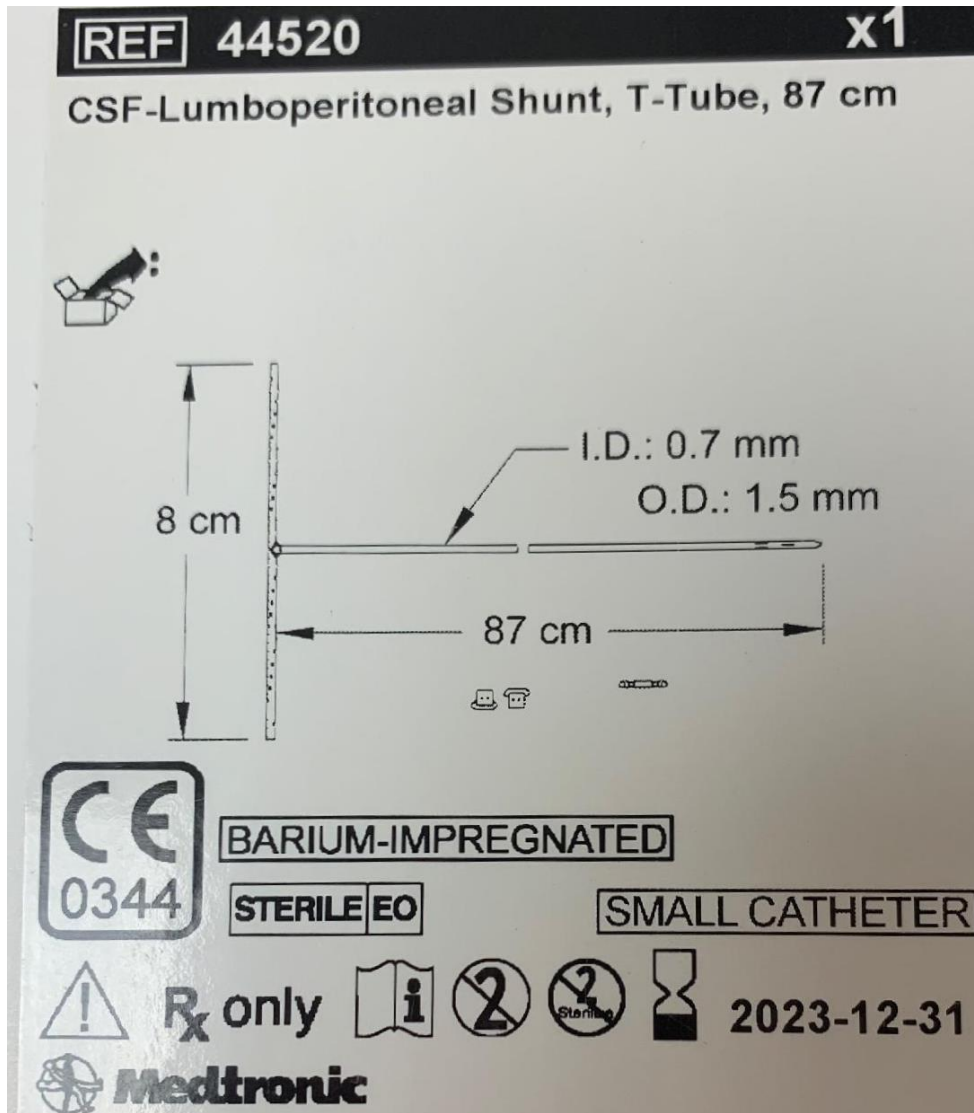
- laminectomy
- US may be useful to localize cyst or septations
- insert Silastic K or T-tube through small separate *paramedian hole in dura* – this allows to close midline durotomy watertight.
- *myelotomy*:

- Rhoton suggests performing the myelotomy in the **dorsal root entry zone (DREZ)**, between the lateral and posterior columns (instead of midline as with a tumors) because this is consistently the thinnest part and there is usually already an upper extremity proprioceptive deficit from the syrinx.
- cut T-tube arms to desired length
- insert tube directly into syrinx cavity
- valveless Silastic catheter
- silicone tubing may be easily cut or torn when instruments are used to secure it to connector.
- place Foltz CSF Reservoir over bone (e.g. rib) – can easily be palpated and depressed
- distal end into cavity of lower pressure
  - with syringosubarachnoid shunts, be sure the distal shunt tip is subarachnoid (and not just subdural) or else it will not function.
  - with syringopleural shunt, the pleural opening can be made posteriorly, adjacent to one of the ribs.

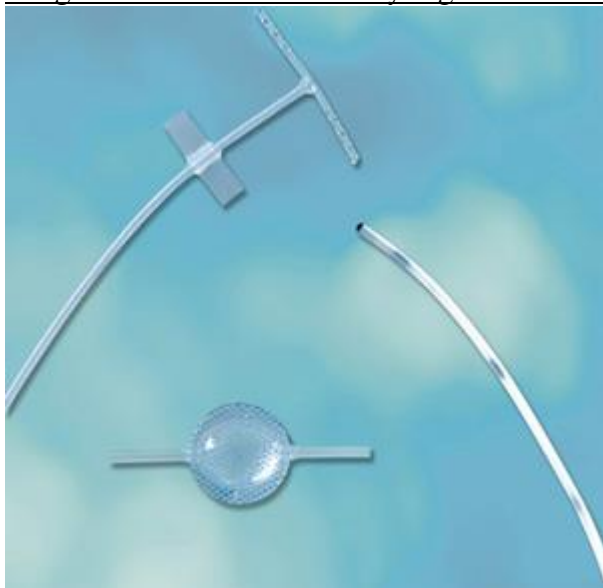### **T-TUBE CATHETER**

- provides continuous drainage of fluid from syrinx to peritoneum.
- small T-tube diameter (approximately 5 FR) minimizes size of myelotomy
- T-shape allows drainage from above and below myelotomy site, minimizing risk of kinking and migration
- multiple perforations reduce chance of catheter occlusion

### Medtronic



Integra™ Edwards-Barbaro Syringo-Peritoneal Shunt Kit

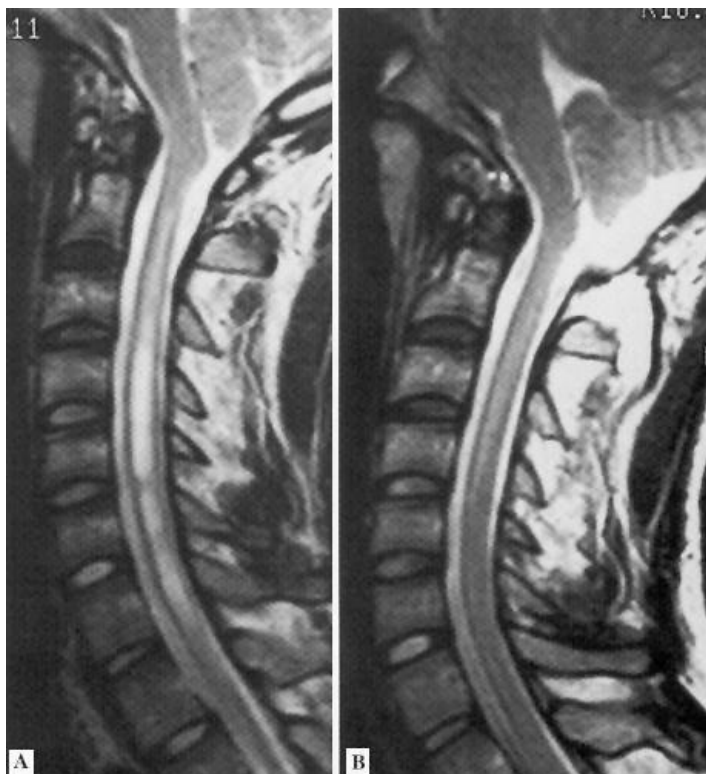


- 5 FR T-tube
- 90 cm peritoneal reflux control catheter
- Step-down connector
- Foltz CSF Reservoir

## OUTCOMES

- clinical stabilization rate with shunting: 54% at 10 yrs.
- five most common clinical manifestations of syringomyelic patient are sensory deficit, motor weakness, sub-occipital pain, dysesthetic pain and spasticity.
  - headache and spinal pain responded best to surgery, presumably because pressure and distension of the dura were relieved.
  - weakness of lower limbs and spasticity improvement can be seen in 2/3 of patients
  - weakness and atrophy of hands often failed to improve.

**MRI-T2 (syringomyelia):**  
 (A) mild cerebellar ectopia and syrinx (white) in cervical spinal cord.  
 (B) same case 1 year post foramen magnum decompression - syrinx has partially collapsed.



### Meta-analysis of syrinx shunts

*Robert J Rothrock, Victor M Lu, Allan D Levi. Syrinx shunts for syringomyelia: a systematic review and meta-analysis of syringosubarachnoid, syringoperitoneal, and syringopleural shunting. J Neurosurg Spine . 2021 Jul 30;1-11. PMID: 34330095 DOI: 10.3171/2020.12.SPINE201826*

- 22 studies, 473 syrinx shunt procedures: 193 (41%) by syringosubarachnoid shunt, 153 (32%) by syringoperitoneal shunt, and 127 (27%) by syringopleural shunt.
- overall median clinical follow-up of 44 months.

	syringo-subarachnoid	syringo-peritoneal	syringo-pleural
revision surgery	13%	28%	10%
rate of clinical improvement	61%	64%	71%
rate of clinical deterioration	13%	13%	10%

## OTHER METHODS

- a) *percutaneous needle aspiration* (can be repeated)
- b) *open syringo(s)tomy* - fails to remain patent (H: myringostomy tube through 3 mm myelotomy) - no longer recommended!
- c) *plugging the obex* with muscle, Teflon, or other material - no longer recommended!
- d) opening the subarachnoid space & *removing inferior tonsils* - no longer recommended!
- e) endoscopic fenestration of septations