# *Focused Ultrasound*

# *(s. MRgFUS, transcranial MRI-guided Focused US)*

Last updated: August 8, 2020


**HISTORY** ..... **1**
**MODERN ERA** ..... **1**
**MECHANISMS OF ACTION** ..... **1**
HEAT GENERATION ..... 1
MECHANICAL EFFECTS ..... 2
**BIOEFFECTS AND THEIR ROLE IN NEURO-ONCOLOGY** ..... **2**
DIRECT CYTOTOXICITY (TISSUE DESTRUCTION) ..... 3
INDIRECT CYTOTOXICITY ..... 3
Radiosensitization ..... 3
Sonodynamic therapy ..... 3
Enhanced delivery of therapeutic agents ..... 3
Immunomodulation ..... 8
COMPLETED CLINICAL TRIALS ..... 8
ONGOING CLINICAL TRIALS ..... 8
**BIOEFFECTS AND THEIR ROLE IN FUNCTIONAL NEUROSURGERY** ..... **9**
COMPLETED CLINICAL TRIALS ..... 9
ONGOING CLINICAL TRIALS ..... 9
**BIOEFFECTS AND THEIR ROLE IN VASCULAR NEUROSURGERY** ..... **9**
**BIOEFFECTS AND THEIR ROLE IN PEDIATRIC NEUROSURGERY** ..... **10**
**STATE OF RESEARCH AND REGULATORY APPROVAL BY DEVELOPMENT STAGE** ..... **10**
**FDA-APPROVED COMMERCIALLY AVAILABLE PLATFORMS** ..... **11**
**PROCEDURAL DETAILS** ..... **12**
**COMPLETED TRIALS** ..... **14**
ESSENTIAL TREMOR TRIAL ..... 14
**CONCLUSIONS** ..... **15**
ADVANTAGES ..... 15
DISADVANTAGES / CHALLENGES ..... 16
**OTHER FACTS** ..... **17**


## HISTORY

- FUS has been investigated for > 60 years for the potential of applying to cerebral tissue (Fry brothers in the 1950s at University of Illinois along with Iowa neurosurgeon Russell Meyers).
- clinical use, however, was limited by the need for a craniectomy for acoustic window - intact skull causes beam distortion (defocusing) and energy absorption.
- at the same time, gamma knife was advanced by Lars Leksell; as a result, FUS for the brain was largely abandoned for several decades.

## MODERN ERA

Three revolutionary technological advances that created new opportunities for FUS:

- correction for skull inhomogeneities that defocus the acoustic energy
- real-time monitoring

1) **phased-array transducers** – each transducer can be independently controlled ("phase shifted") to correct for the phase aberrations produced by the variable thickness of the skull.
2) **CT technology and algorithms** – allow for the compensation of irregular skull thickness and density to minimize US deflection and absorption.
3) **MR thermometry** – real-time tissue temperature monitoring – safety and confirmation of energy delivery to the target; thus, modern FUS is sometimes called MR-guided FUS (MRgFUS).

## MECHANISMS OF ACTION

Depend on:

1. Intensity (power) of sonication – high-intensity (HIFUS) vs. low-intensity (LIFUS)
2. Duration of sonication
3. Mode – continuous, pulsed

### HEAT GENERATION

- FUS in continuous-wave mode generates frictional energy → raises tissue temperature at the focal point - can be monitored with MR thermography.

A. LIFUS can generate a low level temperature rise over several minutes or hours (**local hyperthermia**).

B. HIFUS can generate a short (seconds) temperature rise ≥ 60ºC that causes protein denaturation (**thermal ablation**).

- FUS can create a true lesion in the brain – the term "noninvasive" is inaccurate; the appropriate term – "incisionless" or "minutely invasive" (vs. "minimally invasive" – needs bur hole").
- lesions can be very sharply delineated with lethal and sublethal effects being separated by only several cell thicknesses.
- target zone size: from 1x1.5 mm (1/6 of a grain of rice) to 10x16 mm; for larger structures, lesions can be combined (but with cooling period between sonications to prevent unwanted heating of surrounding tissue – time-consuming)

Tissue effects with temperature and exposure times:

As the temperature increases the exposure time needed to achieve thermal tissue destruction decreases exponentially.
At 100ºC, tissue boils regardless of the exposure time

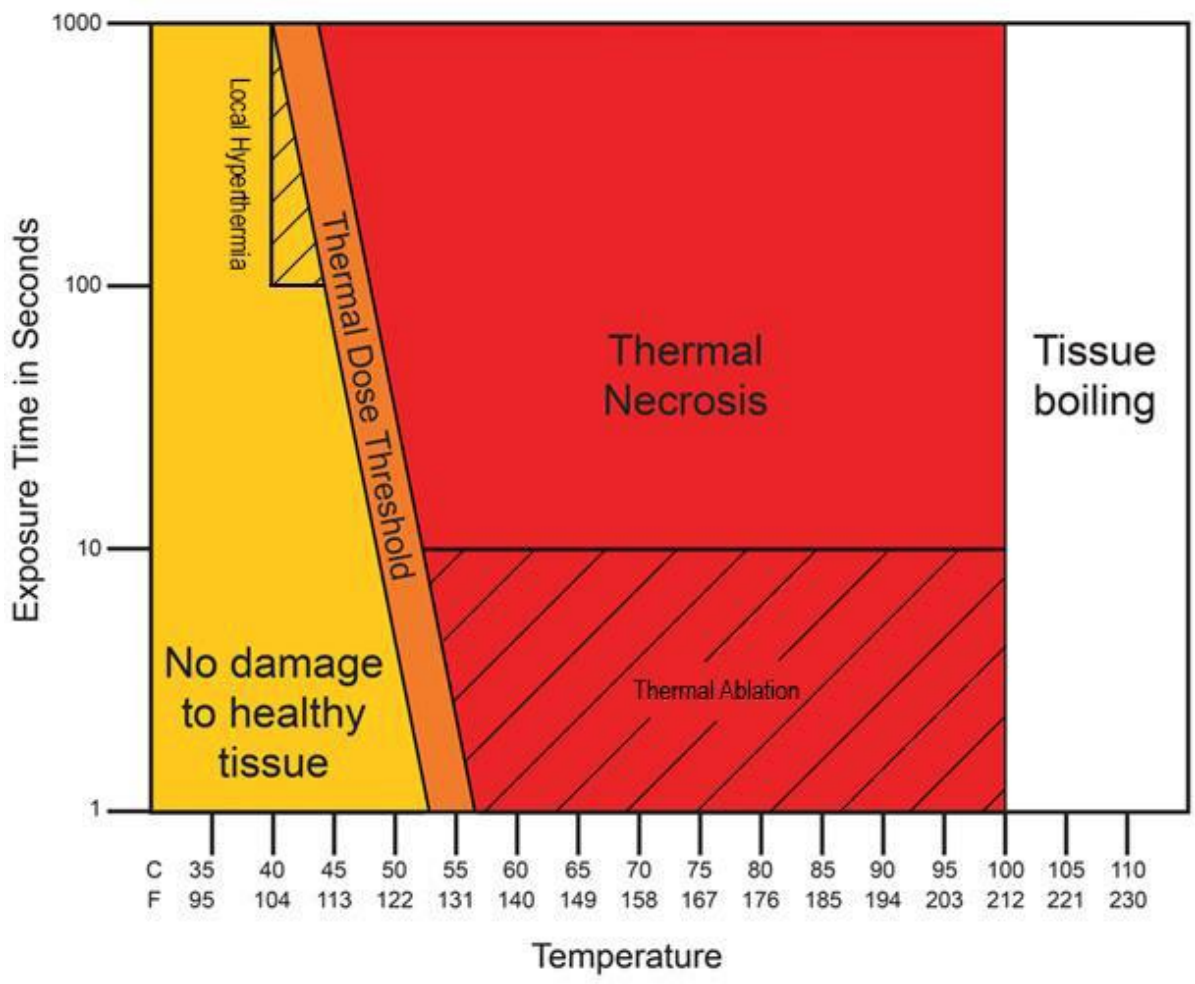


(Marie Dauenheimer, year MA, CMI, FAMI)

## MECHANICAL EFFECTS

- FUS application in pulsed manner (high power and very short pulses) leads to a low energy deposition in the tissue (minimal thermal rise), however, it creates a large pressure change in the tissue → various mechanical effects, from vibration to cavitation.

1. **Acoustic cavitation** - most prominent mechanical effect of FUS

- US is a pressure wave consisting of positive (compressive) and negative (rarefactive) components.
- as US waves propagate through tissue, they interact with dissolved gases.
- the negative component generates gas-filled microbubbles.
- as the US exposure continues, the microbubbles continue to oscillate (noninertial or stable cavitation at 0.3 MPa); if the pressure wave amplitude increases to high power (0.9 MPa), the bubbles collapse (inertial cavitation) → violent shock waves and high-velocity jets → purely mechanical cell disruption or liquefaction (histotripsy).
- likelihood of cavitation increases as the ultrasound frequency decreases.
- cavitation microbubbles are easily visible with ultrasound imaging - accurate monitoring.
- ***systemic injection of microbubbles*** lowers the threshold for inertial cavitation at the target - reduced damage to adjacent tissue.

  N.B. time-averaged acoustic power required for cerebral ablation can be decreased by more than 90% with the use of microbubbles
- cavitation lesions are very precise.

Google: US cavitation images

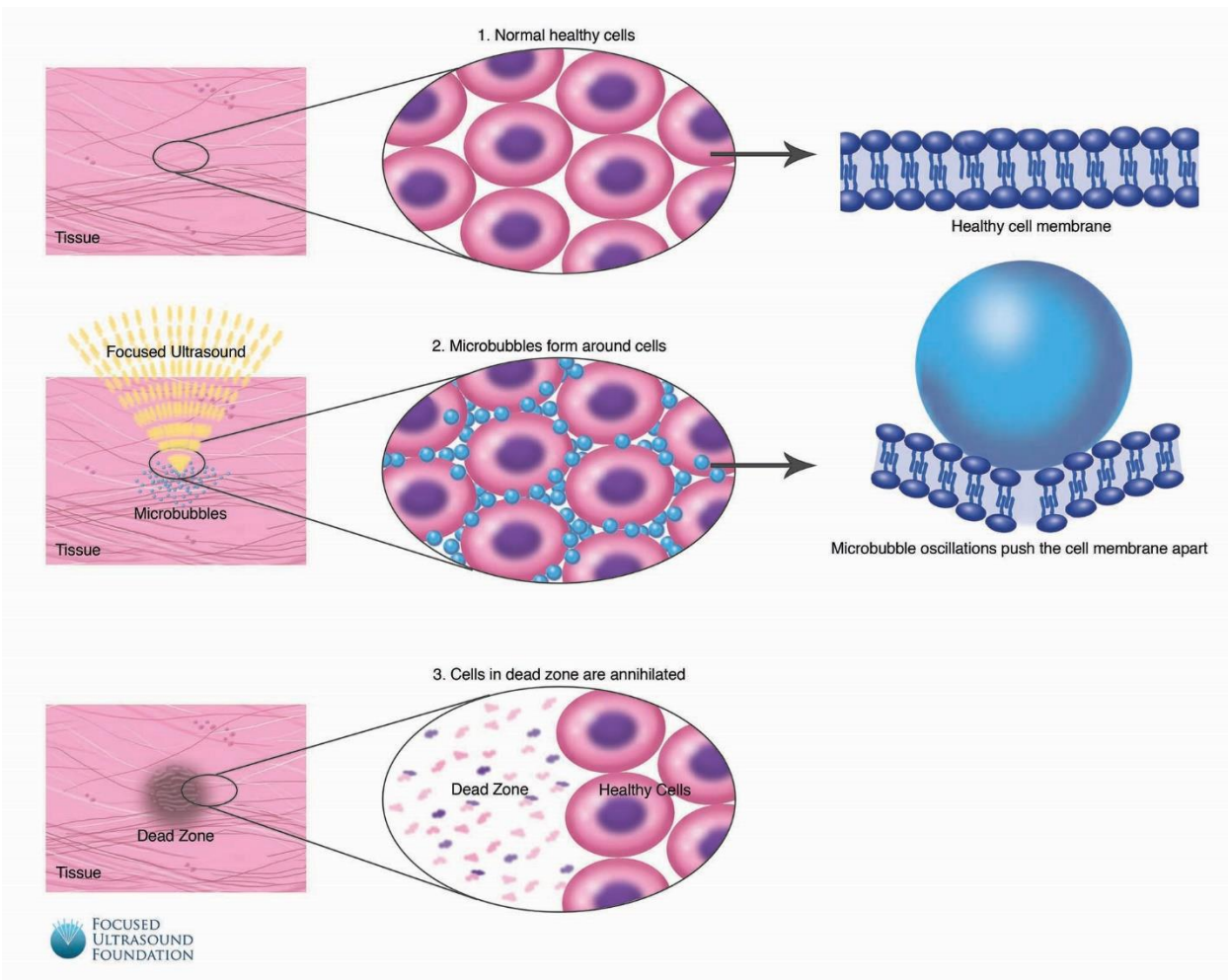


(Marie Dauenheimer, year MA, CMI, FAMI)

2. **Acoustic radiation forces**

- LIFUS beam momentum transfers to a reflecting or absorbing surface → small, steady, unidirectional radiation force along the direction of the beam → ***tissue displacement*** without destruction – can be seen on MRI.

3. **Acoustic streaming**

- results from the radiation forces that take place specifically within a liquid medium; resulting circulation may enhance ***convection***.

## BIOEFFECTS AND THEIR ROLE IN NEURO-ONCOLOGY

MRgFUS is a versatile tool!

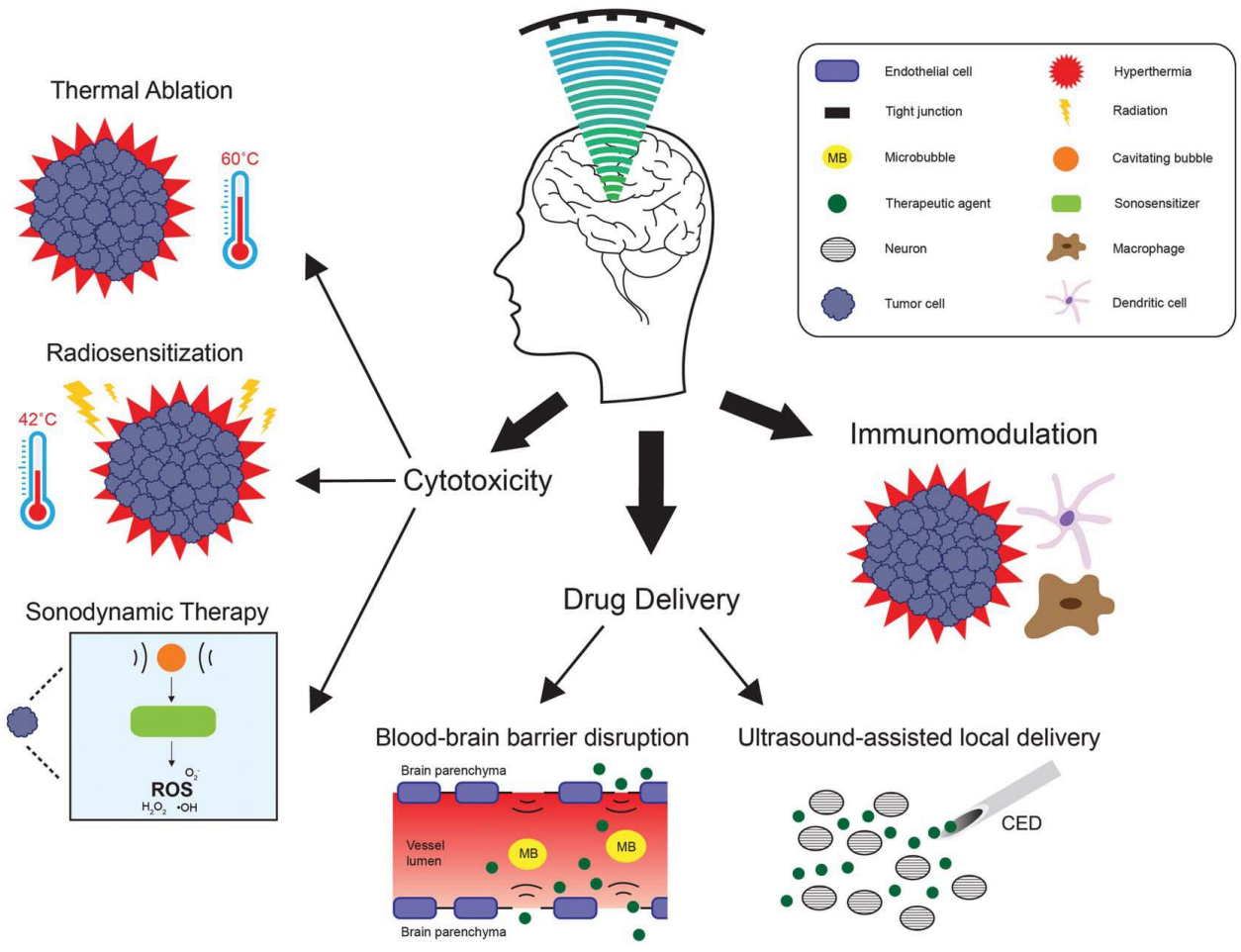


(Hersh et al. 2016)

## DIRECT CYTOTOXICITY (TISSUE DESTRUCTION)

- acoustic cavitation → **non-thermal ablation (histotripsy)**
- heat generation → **hyperthermia (> 55ºC)** → coagulative necrosis → **thermal ablation**
- 3 ongoing phase I/II clinical trials (NCT01698437, NCT00147056, NCT01473485) to study thermal ablation of high-grade gliomas or brain metastasis.

  Exclusion criteria
  1. Bleeding diathesis, vascular tumors - to minimize the risk of intracranial hemorrhage.
  2. Skull reconstructions, dural patches, clips / implants in the sonication path, cystic areas adjacent to the tumor - to maintain precise control over the energy deposition along the ultrasound beam path.
  3. Signs of intracranial hypertension or tumor mass effect - to avoid transient increase in symptomatic cerebral edema.

## INDIRECT CYTOTOXICITY

### RADIOSENSITIZATION

Heat generation → **hyperthermia (42ºC)** → interference with DNA repair, increased blood flow with tumor reoxygenation → **radiosensitization;**

- currently, it is technically difficult to administer FUS and radiotherapy simultaneously.
- Guthkelch et al. 1991 (FUS-induced hyperthermia as an adjunct to radiation therapy for the treatment of high grade gliomas) – FUS was delivered after craniectomy with temperature monitored via implanted probes – difficulties in achieving uniform power deposition – highly heterogeneous structure of some tumors, effect of blood flow in vascular tumors.
- clinical effect of radiosensitization was demonstrated* with microwave-based hyperthermia but not with FUS-induced hyperthermia.

  *Sneed et al. 1998: Hyperthermia was associated with significantly longer time to progression (P = 0.045) and survival (P = 0.02). Median survival was 76 weeks vs 85 weeks and 2-year survival was 15% vs 31% for the control vs hyperthermia groups, respectively.

### SONODYNAMIC THERAPY

Cavitation / heat generation → activation of sonosensitizers, generation of reactive oxygen species (free radicals, singlet oxygen) → cellular damage (**sonodynamic therapy**)

- it is a noninvasive alternative to photodynamic therapy (light has poor tissue penetration requiring implantable interstitial fiberoptic sources).
- sonodynamic therapy mechanism in brain is demonstrated in animal studies only; however, hematoporphyrin monomethyl ether, protoporphyrin IX, and ATX-70 have been shown to have sonodynamic effects in sarcoma, hepatocellular carcinoma, osteosarcoma, and endometrial cancer

Effect of sonodynamic therapy with 5-ALA and FUS for intracranial glioma in rat:

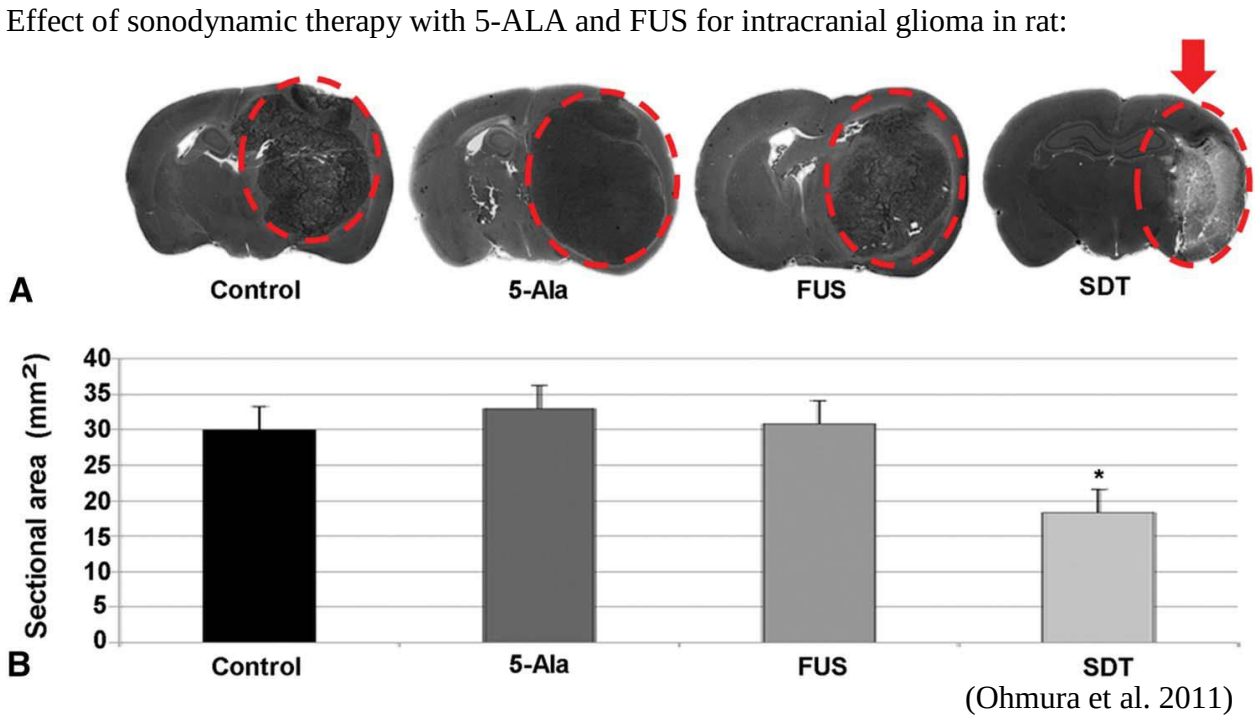


(Ohmura et al. 2011)

### ENHANCED DELIVERY OF THERAPEUTIC AGENTS

a) acoustic pressure change at a precise location → endothelium releases nitric oxide → **vasodilation** → increased amount of drug delivered to the target).

b) drug is encapsulated in / bonded to a carrier vehicle (e.g. microbubble, liposome, nanoparticle) that is sensitive to either elevated temperatures or pressures* → carrier vehicles are injected systemically → drug is only released in the area targeted by FUS (**targeted drug release**).

*e.g. low temperature sensitive liposomes (LTSLs), acoustic pressure-sensitive carriers.

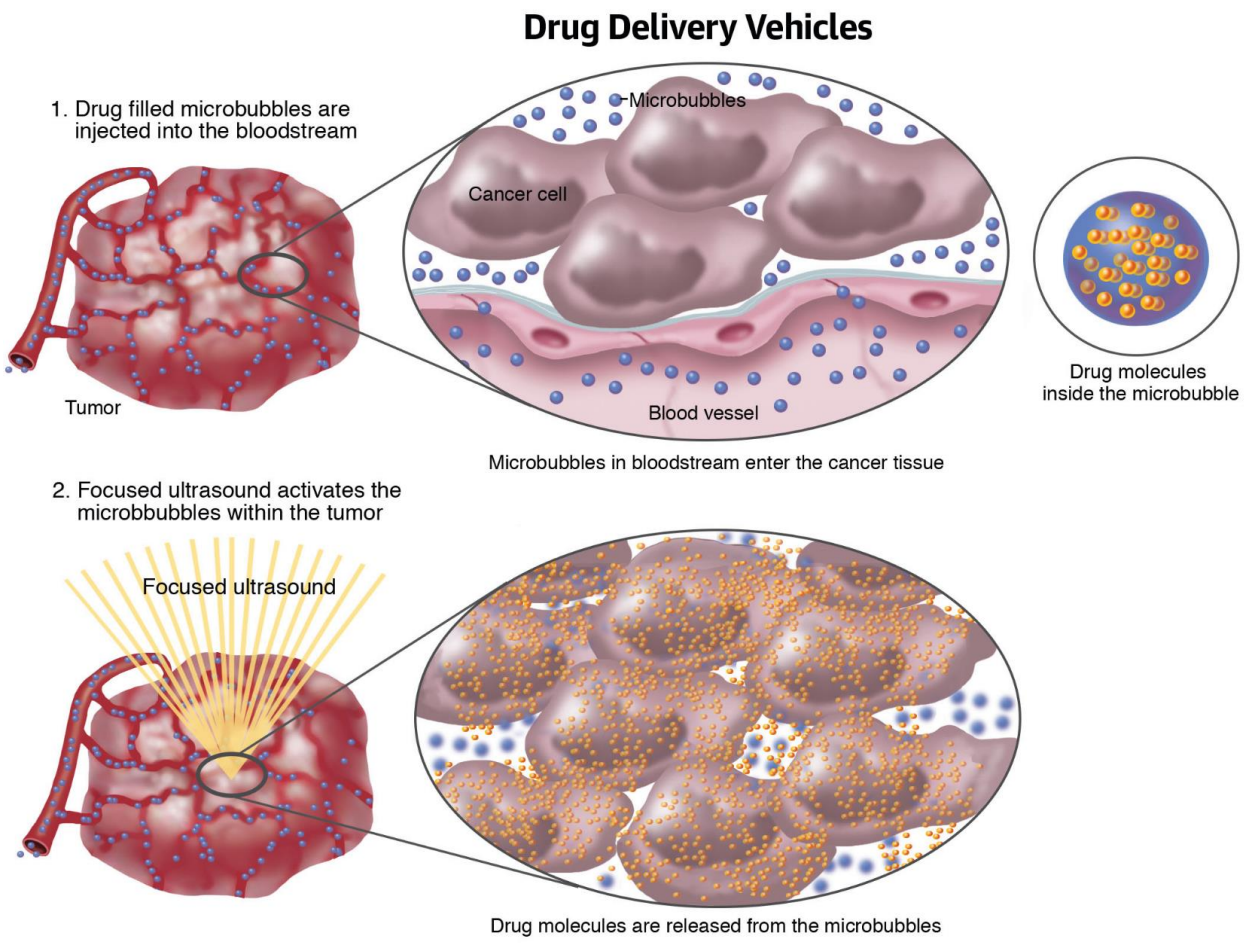


(Marie Dauenheimer, year MA, CMI, FAMI)

c) IV administration of US contrast agents (microbubbles that concentrate by the capillary walls) → pulsed LIFUS (low pressure, low frequency 500 kHz) → formation of cavitation bubbles → disruption of tight intercellular junctions in endothelium → **transient selective opening the blood-brain barrier** (happens immediately, may endure up to 4-6 hours with reversal to its original structure without permanent damage)

N.B. although the BBB is disrupted in many gliomas, it often remains intact at the periphery of the tumor, where invading tumor cells are interspersed with healthy brain cells.

Normal BBB is impermeable to molecules > 400 Da; disrupted BBB allows delivery of molecules as big as antibodies.

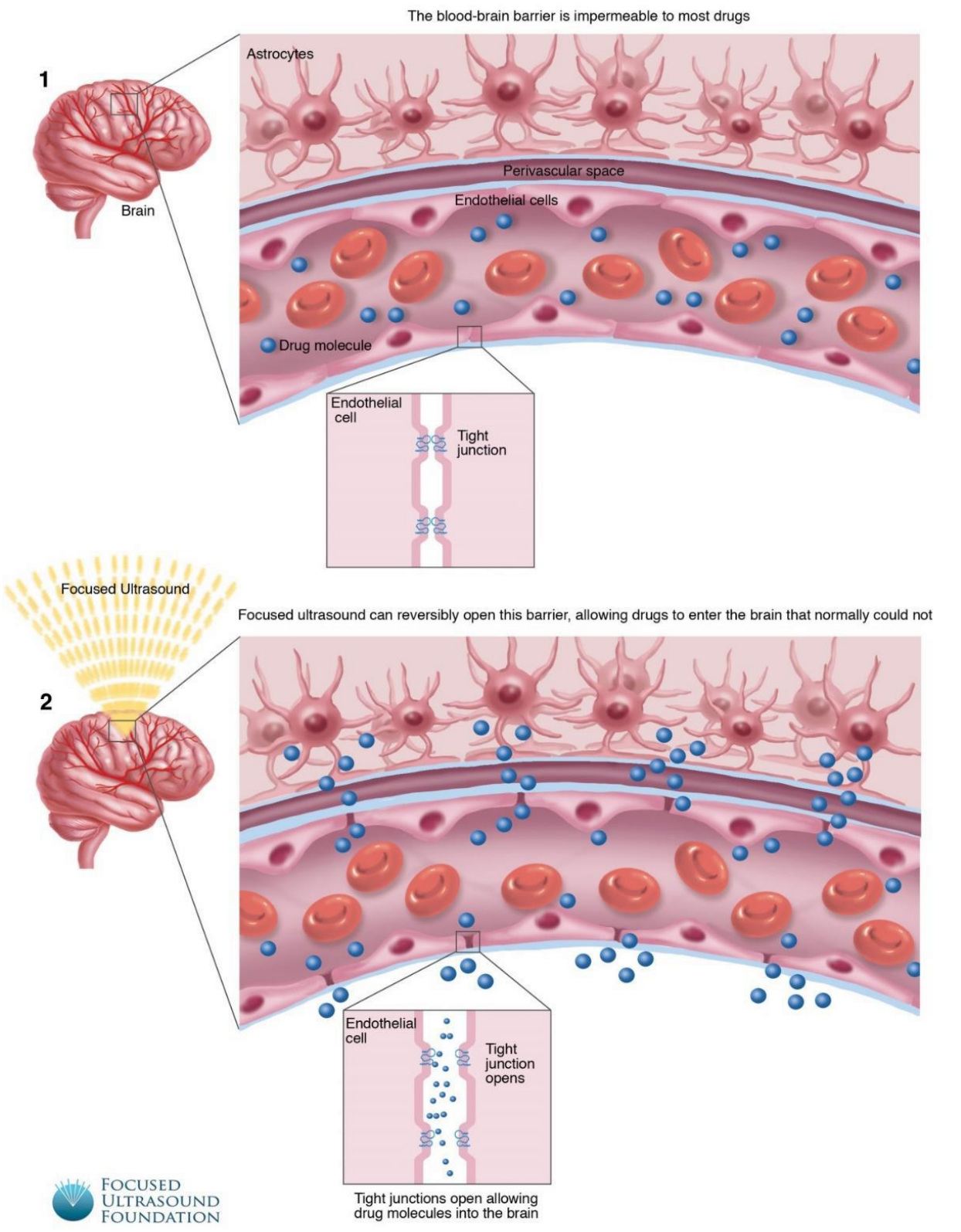


(Marie Dauenheimer, year MA, CMI, FAMI)

Microbubble size effect – 4-5 micron bubbles better match brain capillary diameter (4-10 μ) with better BBB opening

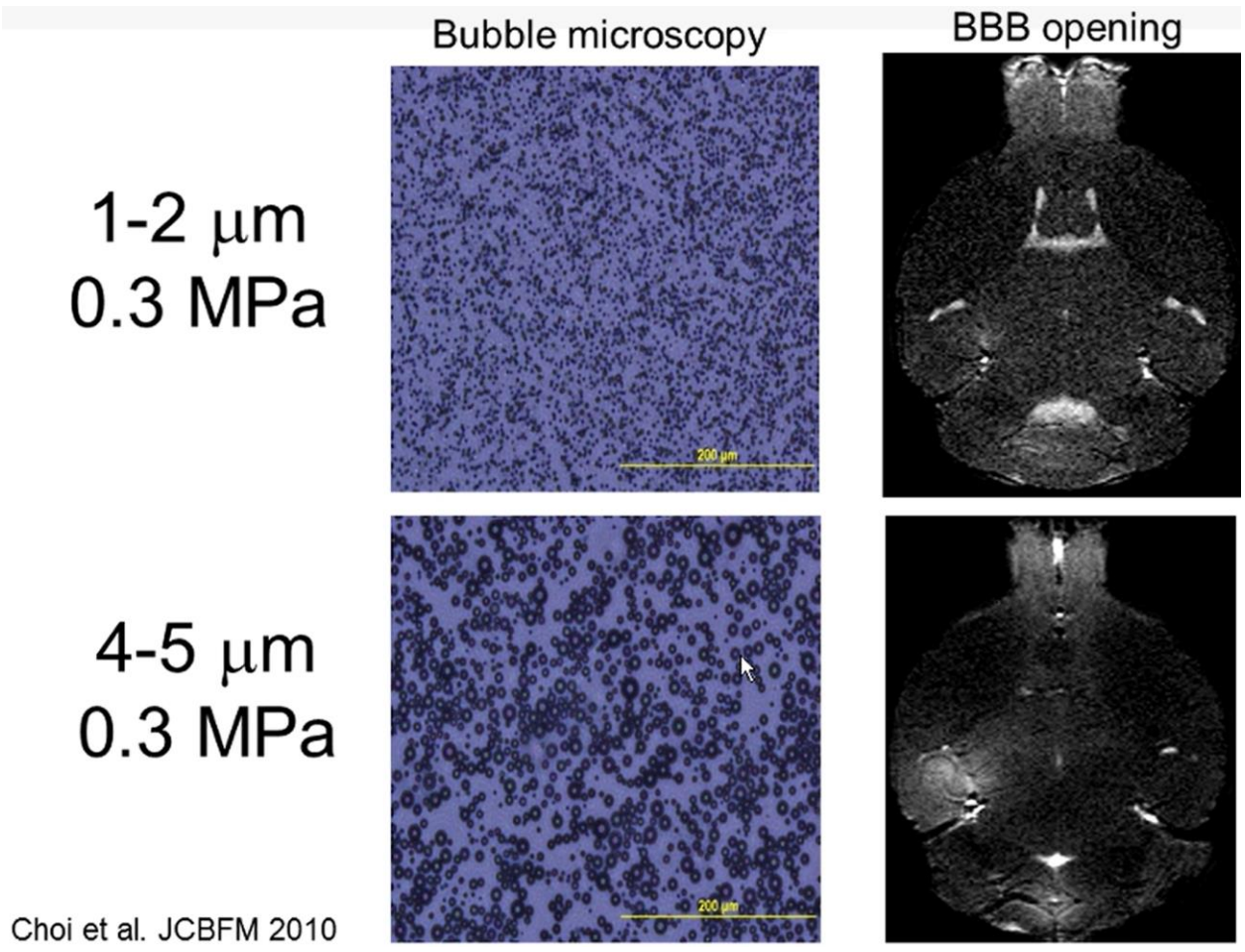


Microbubble size and US acoustic pressure effect (e.g. 1-2 μ microbubbles with 0.3 MPa do not open BBB):

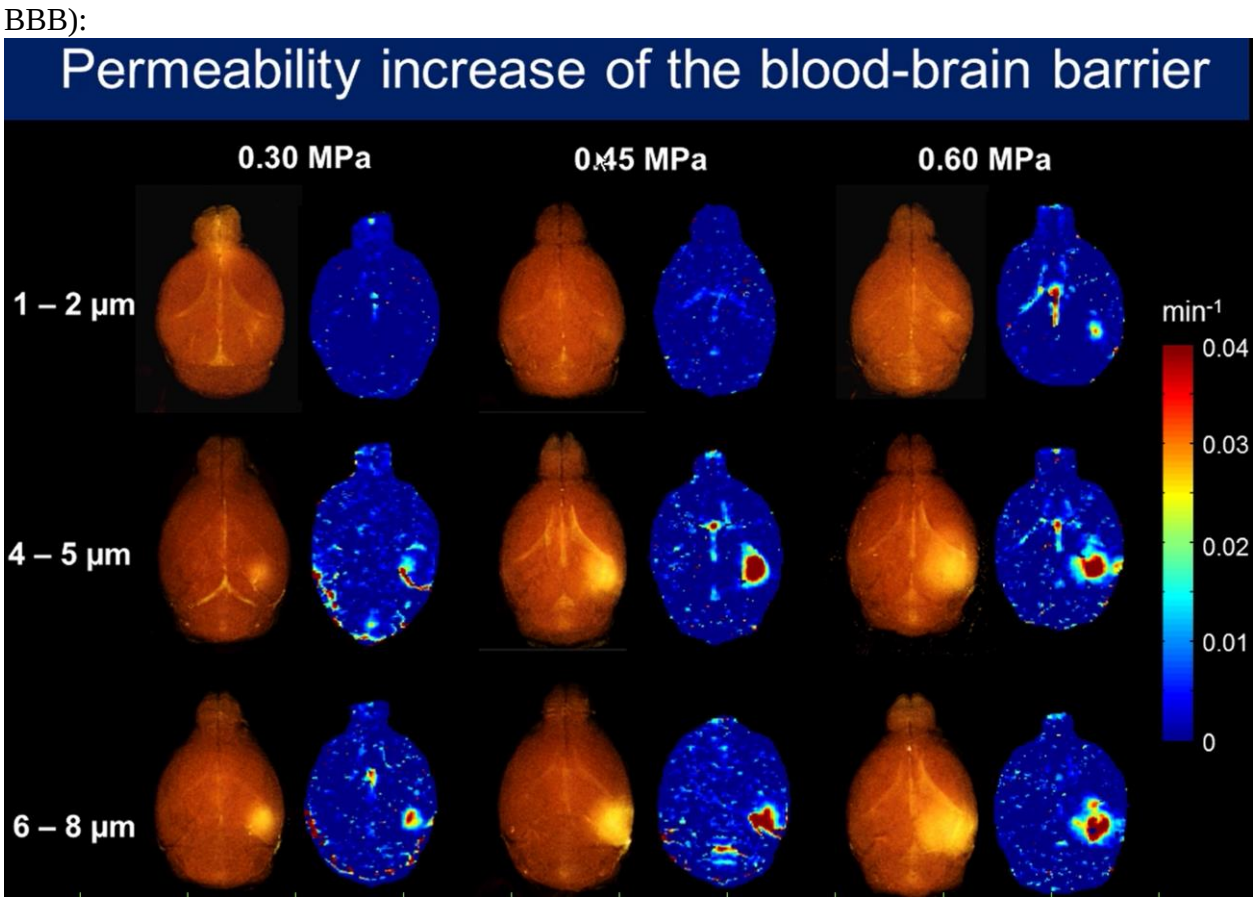


(Sun et al. 2013)

BBB opening with smaller microbubbles and less acoustic pressures lasts shorter:

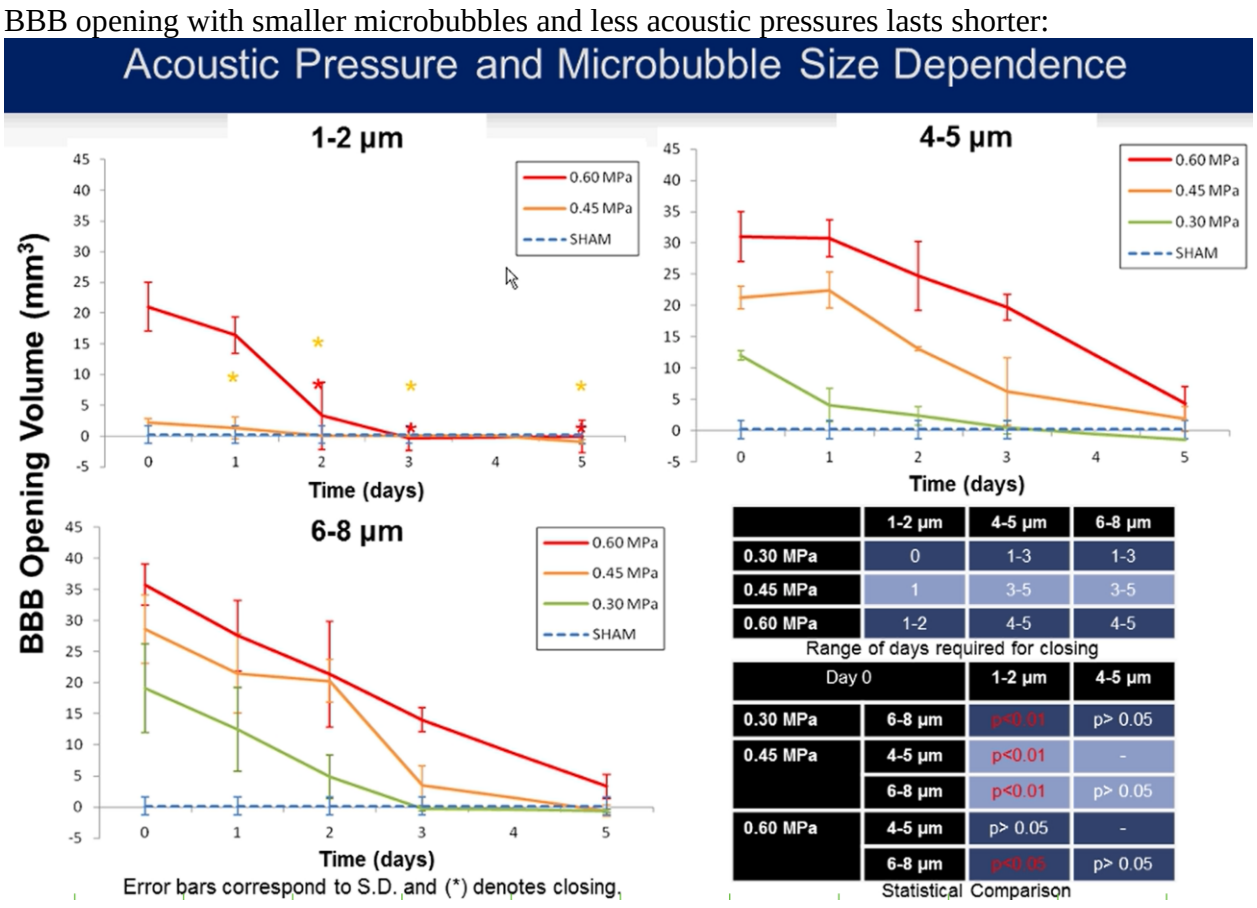


| | 1-2 μm | 4-5 μm | 6-8 μm |
|---|---|---|---|
| 0.30 MPa | 0 | 1-3 | 1-3 |
| 0.45 MPa | 1 | 3-5 | 3-5 |
| 0.60 MPa | 1-2 | 4-5 | 4-5 |

| Day 0 | | 1-2 μm | 4-5 μm |
|---|---|---|---|
| 0.30 MPa | 6-8 μm | p<0.01 | p> 0.05 |
| 0.45 MPa | 4-5 μm | p<0.01 | - |
| | 6-8 μm | p<0.01 | p> 0.05 |
| 0.60 MPa | 4-5 μm | p> 0.05 | - |
| | 6-8 μm | p<0.05 | p> 0.05 |

Larger acoustic pressures make BBB openings larger – larger molecules can penetrate BBB to the larger area:

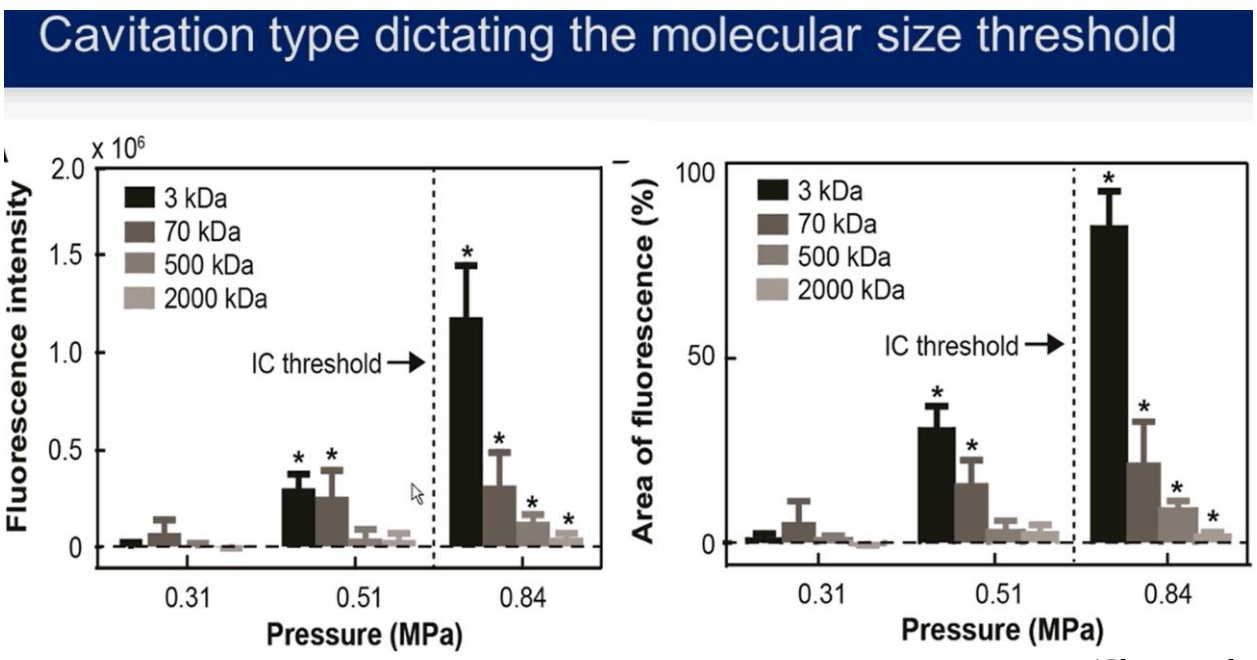


(Chen et. al. 2014)

Fluorescein-dextran (70 kDa) penetration into mouse hippocampus (higher magnification shows that uptake is into actual neurons):

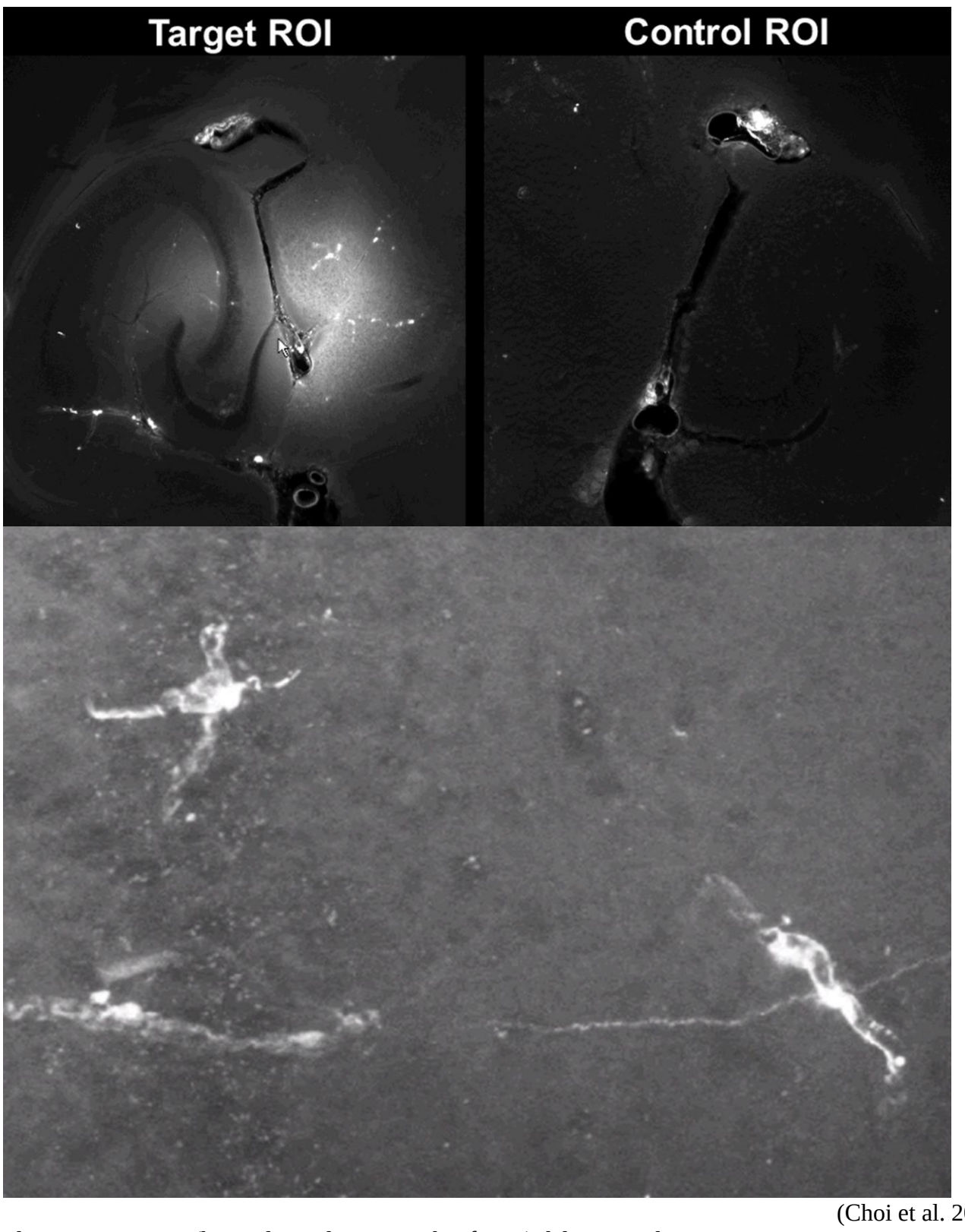


(Choi et al. 2011)

Fluorescent BDNF (brain-derived neurotrophic factor) delivery under sonication:

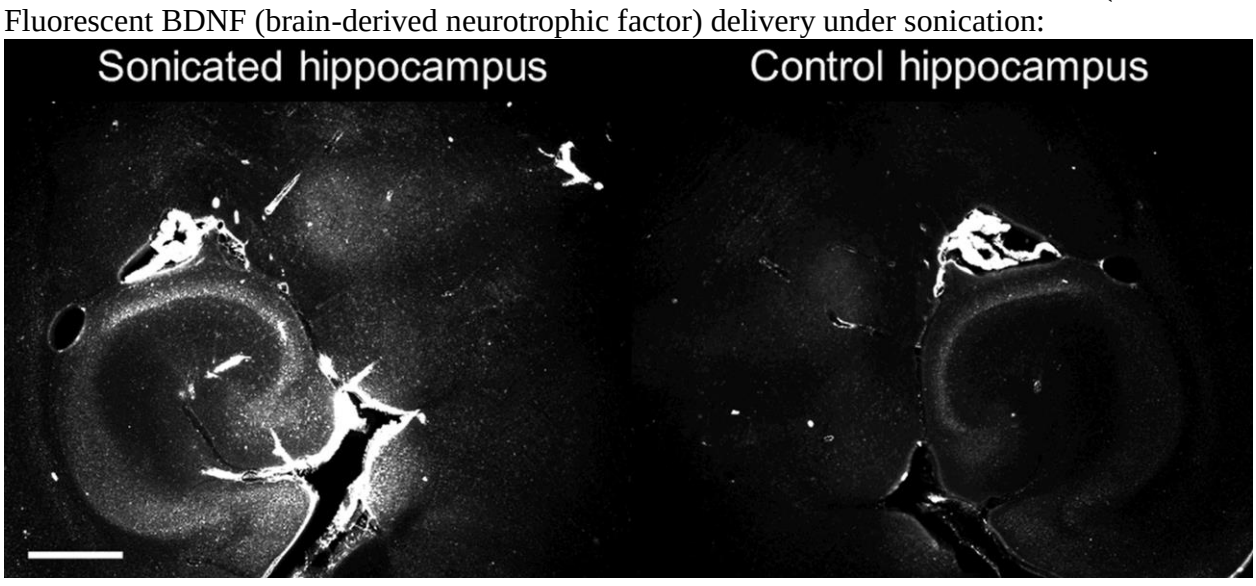


(Baseri et al. 2012)

BBB opening is larger in awake state vs. sedated (anesthesia) state in nonhuman primate brain (mechanism unknown):

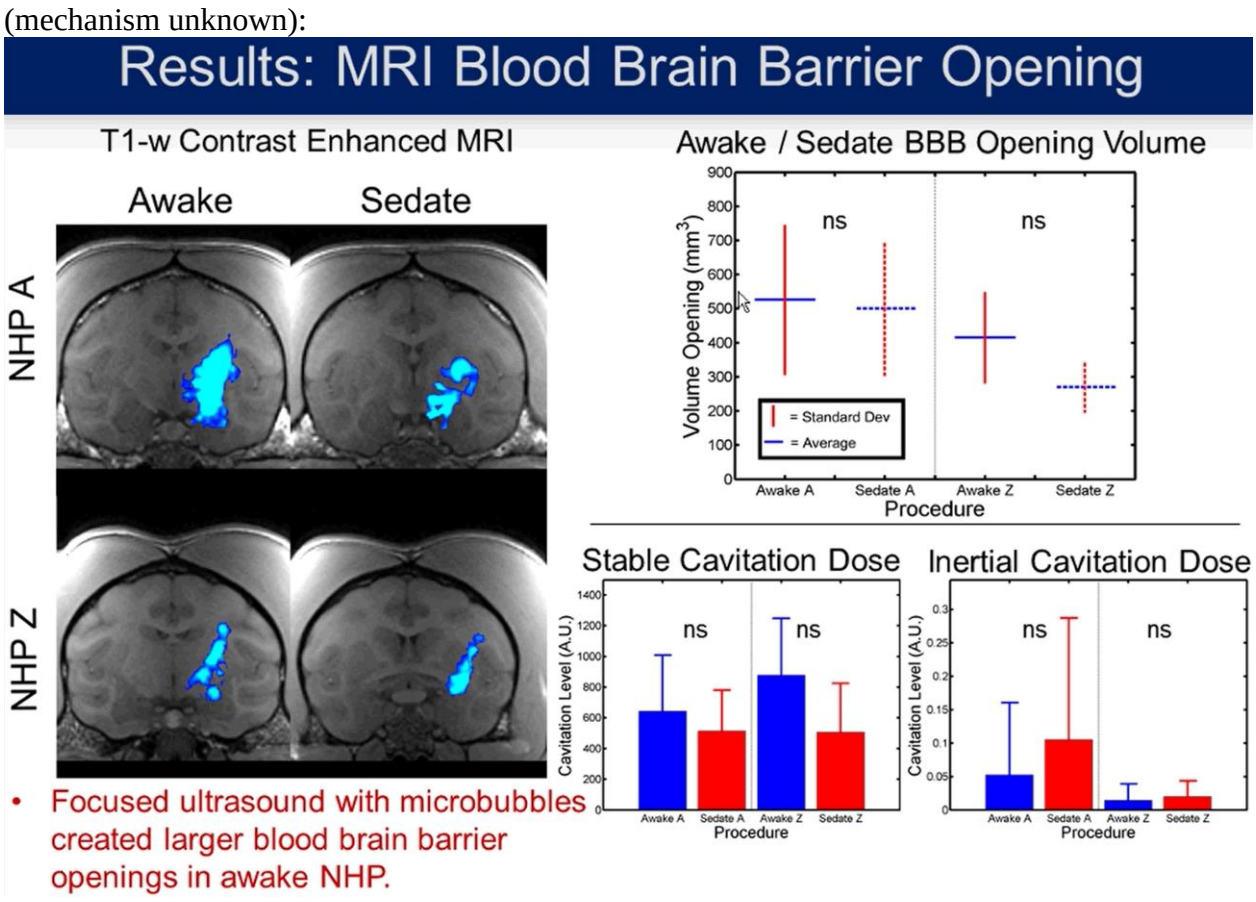


(Konofagou 2015)

- BBB closure time is independent of the volume of BBB opened (O'Reilly MA et al. 2017) – important for safety opening BBB in large areas.
- ongoing phase I trial (NCT02343991) in patients with GBM who are being treated with doxorubicin; the first patient was treated, and the BBB was successfully opened (confirmed with contrast enhancement on the postsonication MRI).

SonoCloud device (CarThera) - 1 MHz ultrasound implant for BBB opening; does not need MRI for thermography:

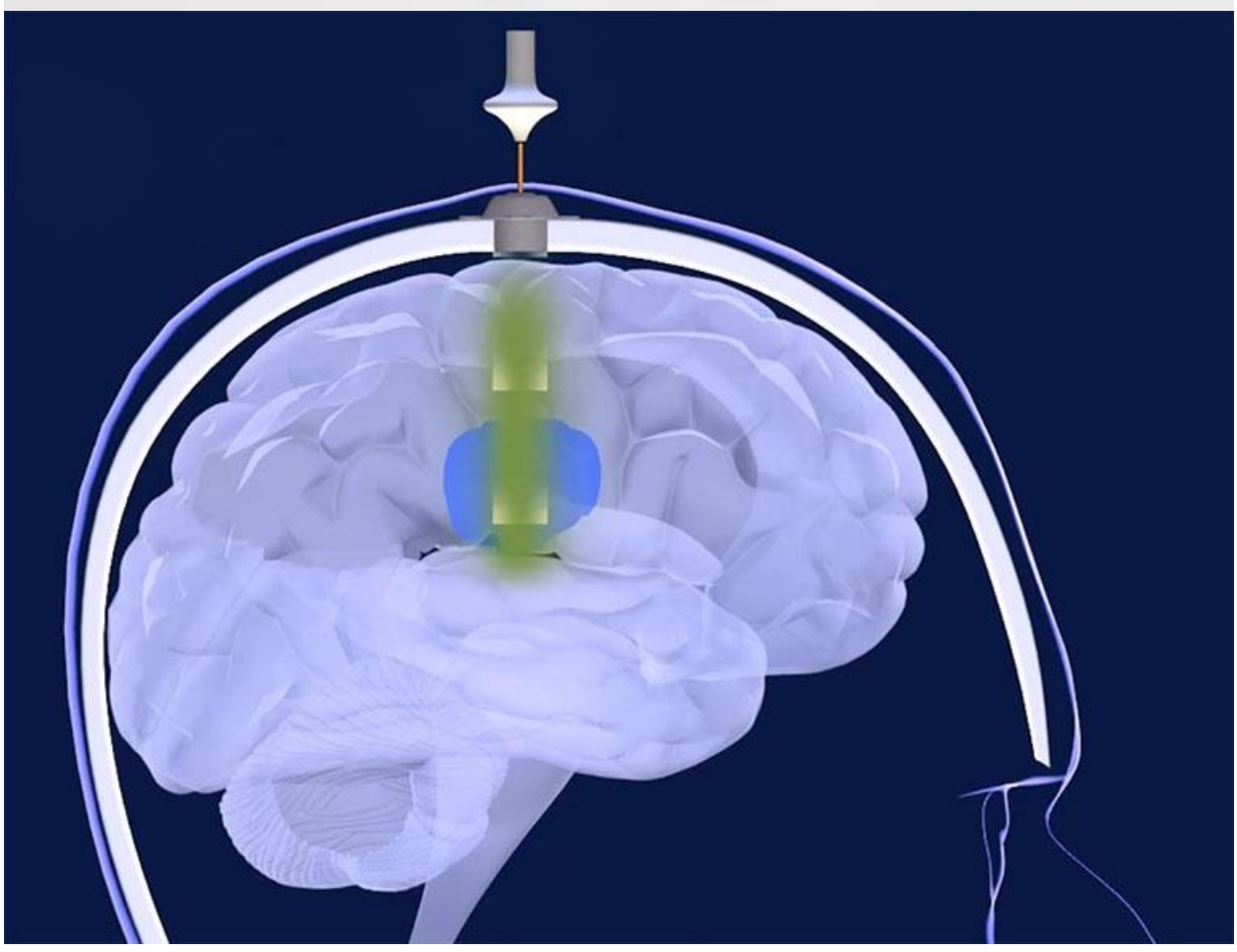

d) acoustic radiation and acoustic streaming → tissue shear and displacement, fluid circulation → **US-assisted enhanced local drug delivery** (distribution through the extracellular space, penetration of tissue-tumor barrier).
   - mechanism demonstrated in preclinical studies only.
   - possible to combine with "brain-penetrating" nanoparticles with a dense polyethylene glycol coating that prevents nonspecific binding to components of the brain extracellular matrix.

Distribution of catheter infused Evans blue dye by convection-enhanced delivery (CED) without and with unfocused ultrasound exposure:

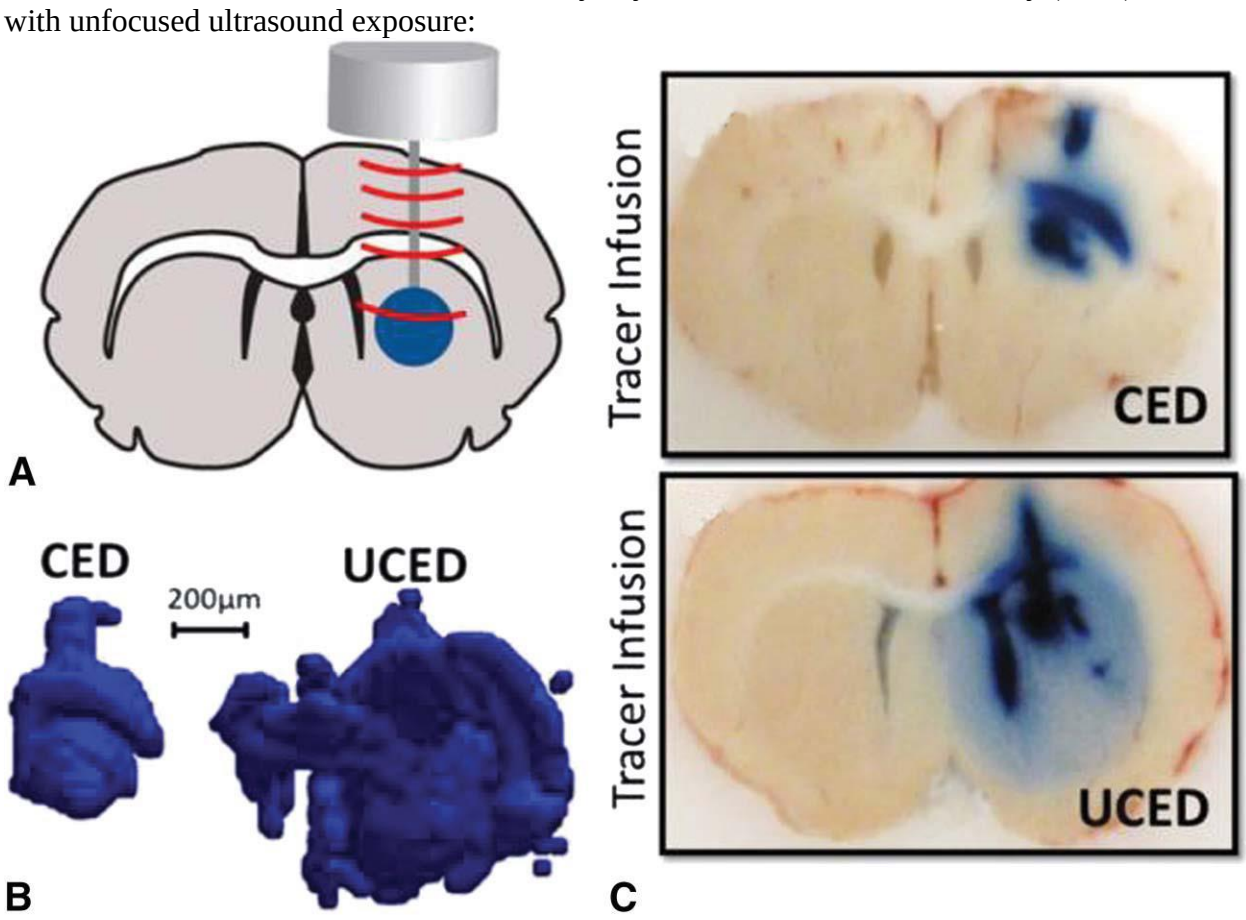


(Lewis et al. 2011)

e) stable cavitation → pores in cell membranes → ↑permeability of cell membranes (**sonoporation**) → enhanced drug absorption into cells → intracellular drug trapping after termination of sonoporation

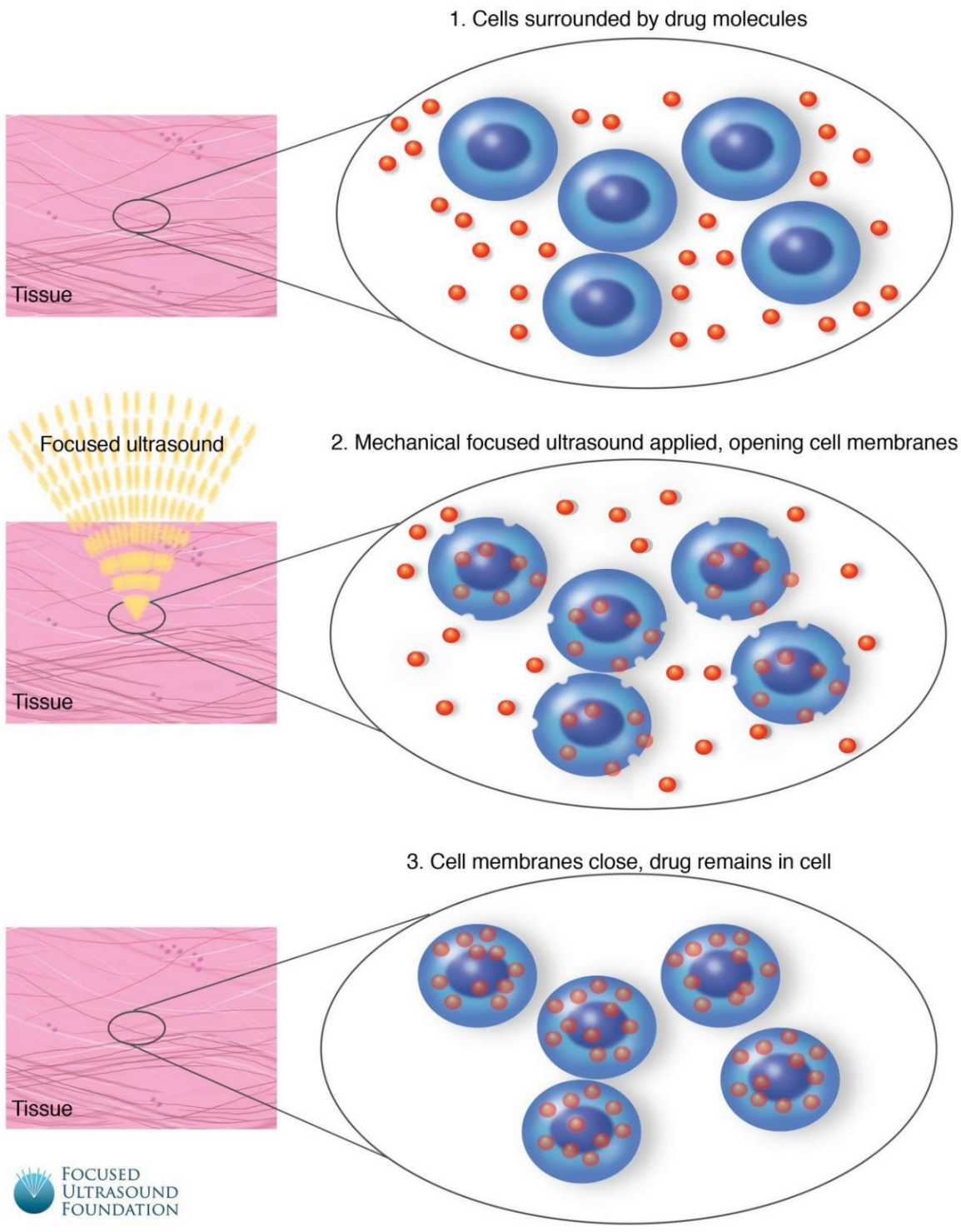


(Marie Dauenheimer, year MA, CMI, FAMI)

## IMMUNOMODULATION

Immunomodulation of the tumor microenvironment.

- thermal < mechanical effects → tumor cellular debris → presentation of tumor-specific antigens, changes in chaperone expression, and cytokine secretion → **enhanced immune recognition and tumor clearance**
- mechanism demonstrated in preclinical and clinical studies but clinical outcome studies are lacking.
- added benefit: FUS tumor ablation causes amplified release of cellular debris with tumor biomarkers into systemic circulation – potential for diagnostics.

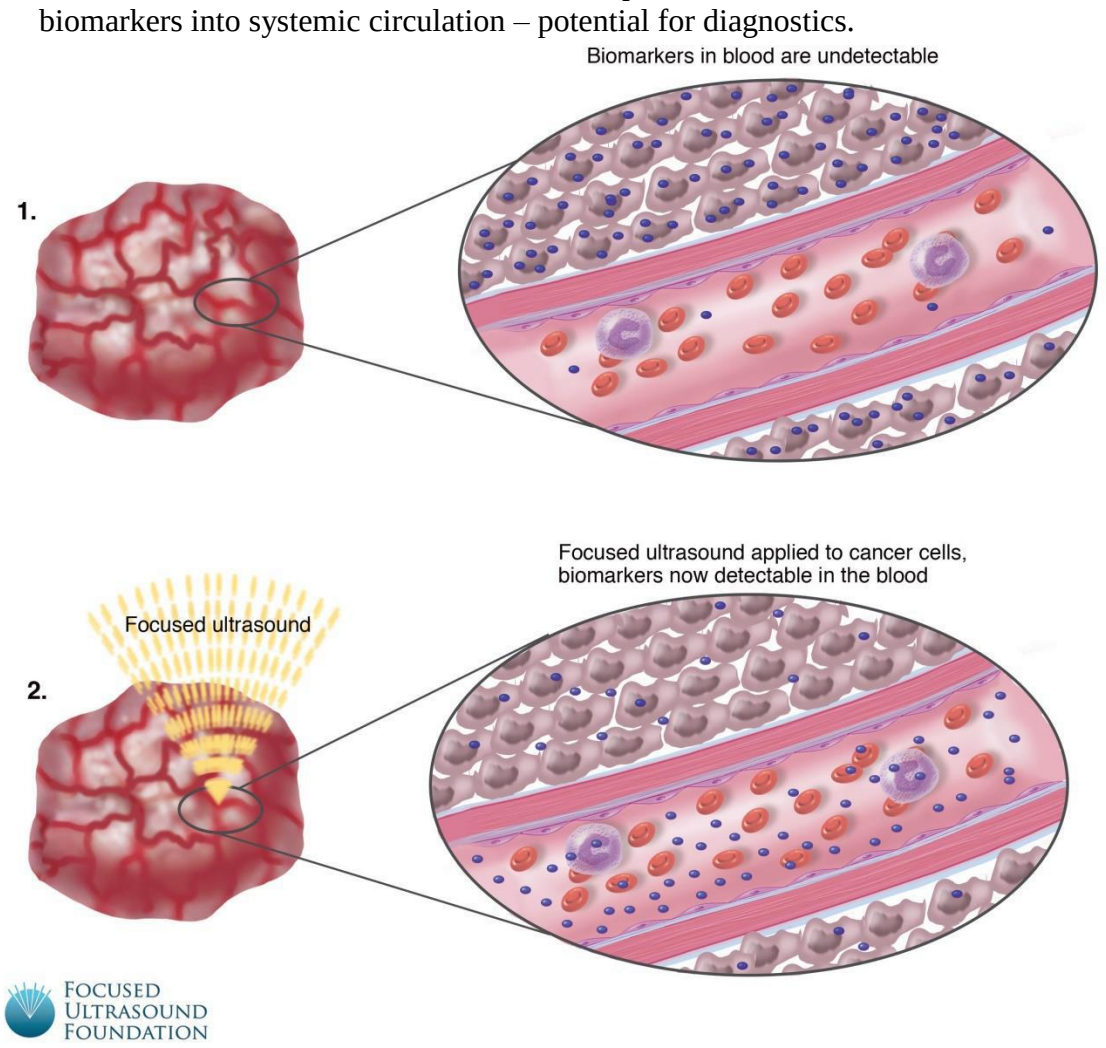


(Marie Dauenheimer, year MA, CMI, FAMI)

## COMPLETED CLINICAL TRIALS

New / recurrent glioma or metastatic brain tumors when conventional surgery is not an option: NCT01698437 (University Children's Hospital, Switzerland) - **MR-guided Focused Ultrasound in the Treatment of Brain Tumors**
No study results posted yet

## ONGOING CLINICAL TRIALS

Recurrent metastatic brain tumors: NCT00147056 (Brigham & Women's Hospital, Swedish Medical Center) - **FUS Feasibility Study for Brain Tumors, Phase 1 trial**

Glioma, Metastatic Brain Cancer: NCT01473485 (Sunnybrook Health Sciences Centre, Canada) - **ExAblate FUS Treatment of Brain Tumors**

Safety of BBB disruption using transcranial MRI-guided focused ultrasound in conjunction with a contrast agent to increase doxorubicin in brain tumors
NCT02343991 (Sunnybrook Health Sciences Centre, Canada)

# BIOEFFECTS AND THEIR ROLE IN FUNCTIONAL NEUROSURGERY

1. **Thermal ablation**
   Women's Medical University in Tokyo – Nov 2016 – first hand dystonia patient treated with FUS to target ventrooralis (Vo) nucleus of the thalamus – 35-yo guitar player (MRI-compatible guitar):

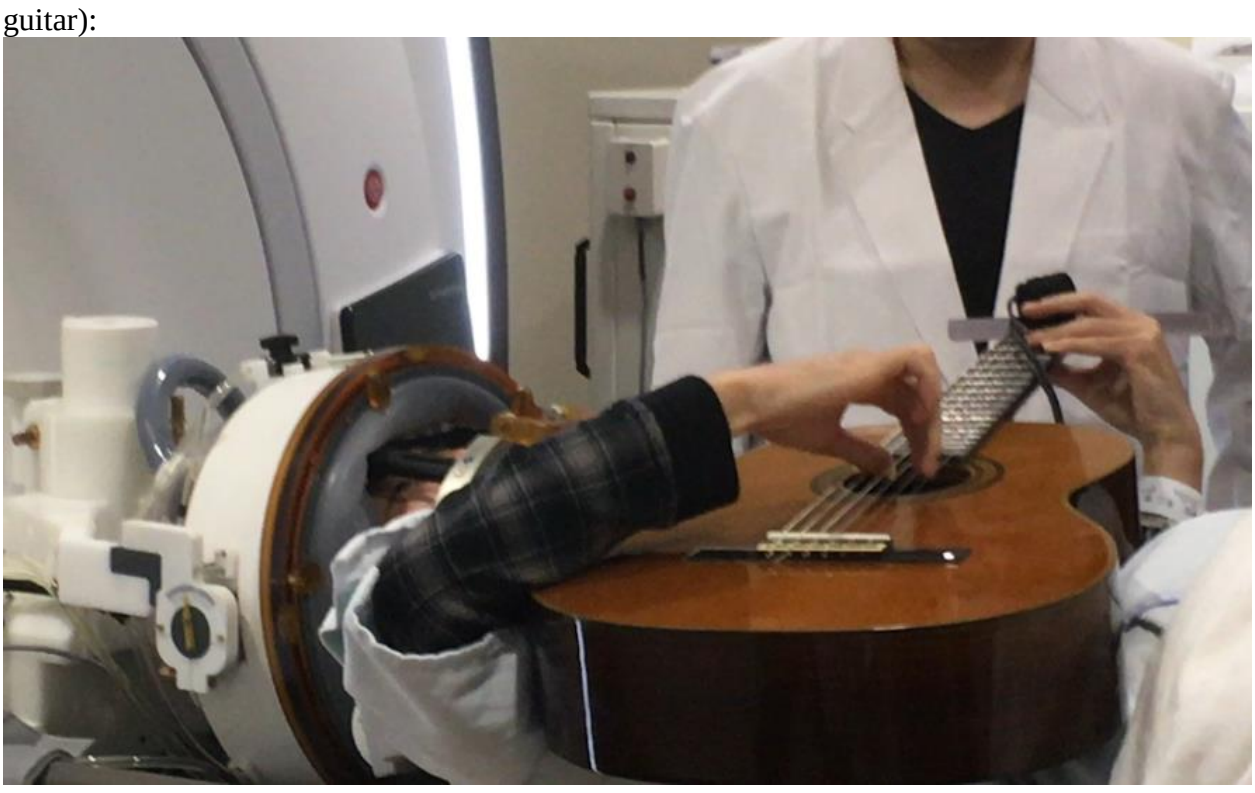

2. **BBB disruption** (e.g. for delivery of anti A-beta antibodies to decrease amyloid burden in Alzheimer's disease – demonstrated in animal studies with improvement in functional performance along with increased neurogenesis).
3. **Neuromodulation** – exact mechanism unknown but likely by mechanical effects; depending on parameters chosen, FUS can reversibly:
   a) inhibit neurons → test "lesion" prior to therapeutic FUS (i.e. clinical target confirmation)
   b) stimulate neurons* → brain mapping with high precision
      *mechanism of this action may be through the mechanical alteration of voltage-sensitive ion channels or by causing bursts of action potentials by causing changes in neuronal cell membrane permeability
      Lee at al. group (2016) induced phosphenes by FUS stimulation of V1 accompanied by EEG and fMRI changes in that area
4. FUS induces release of chemoattractant molecules, expression of cellular adhesion molecules on endothelial cells → **stem cell homing** (demonstrated in preclinical studies) - targeting stem cell delivery for neurodegenerative diseases.
5. **Remyelination** in MS - completed preclinical in vivo pilot study at the University of Washington in Seattle (Mourad et al. 2017) – pulsed FUS (only one side of the brain for 30 minutes every day for 5 days) increased corpus callosum myelination by 5% (relative to untreated side) in 6 out of 7 animals.

## COMPLETED CLINICAL TRIALS

Essential tremor: NCT01304758 (UVA) - ExAblate FUS in the Treatment of Essential Tremor

## ONGOING CLINICAL TRIALS

ET: bilateral staged or retreatment thalamotomy for ET (a trial is underway, NCT03465761)

Parkinson disease:
1) NCT01772693 (UVA, Swedish Medical Center) - ExAblate FUS for Parkinson's Disease
2) NCT02246374 (UVA) - ExAblate FUS of STN for Parkinson's Disease
3) NCT02263885 (UVA, Univ of Maryland, Ohio State Wexner Medical Center) - ExAblate FUS of GPi for Parkinson's Disease

Dystonia: pallidotomy

Epilepsy:
1) NCT02151175 (UCLA) - LIFUS Pulsation for Temporal Lobe Epilepsy; Device: BrainSonix Inc.
2) NCT02804230 (UVA) - ExAblate thermal ablation of a subcortical focal epileptic targets.

OCD: NCT01986296 (Yonsei University, Korea) - ExAblate FUS for Medication Refractory Obsessive Compulsive Disorder

Depression: NCT02348411 (Yonsei University, Korea) - ExAblate FUS for Bilateral Anterior Capsulotomy (anterior limb of internal capsule) for Medication-Refractory MDD

Neuropathic pain: NCT01699477 (University Children's Hospital, Switzerland) – FUS Thalamotomy for Neuropathic Pain

Disorders of consciousness: NCT02522429 (UCLA) - Thalamic LIFUS in Acute Brain Injury

# BIOEFFECTS AND THEIR ROLE IN VASCULAR NEUROSURGERY

Inertial cavitation → mechanical clot disruption (**sonothrombolysis**); enhanced by microbubbles and/or thrombolytic agents
- potential noninvasive treatment for **intracranial hemorrhage**
- potential noninvasive augmentation of tPA effects in **stroke**
- **T2 MRI** is the optimal imaging for successful sonothrombolysis - thrombus becomes brighter (like serum).

Human cadaver. M1 clot was induced by injecting thrombin through endovascular microcatheter and flow was maintained by saline pumping system. FUS targeted M1 clot (arrows), and with total of four sonications, clot was completely sonothrombolyzed over 10 minutes:

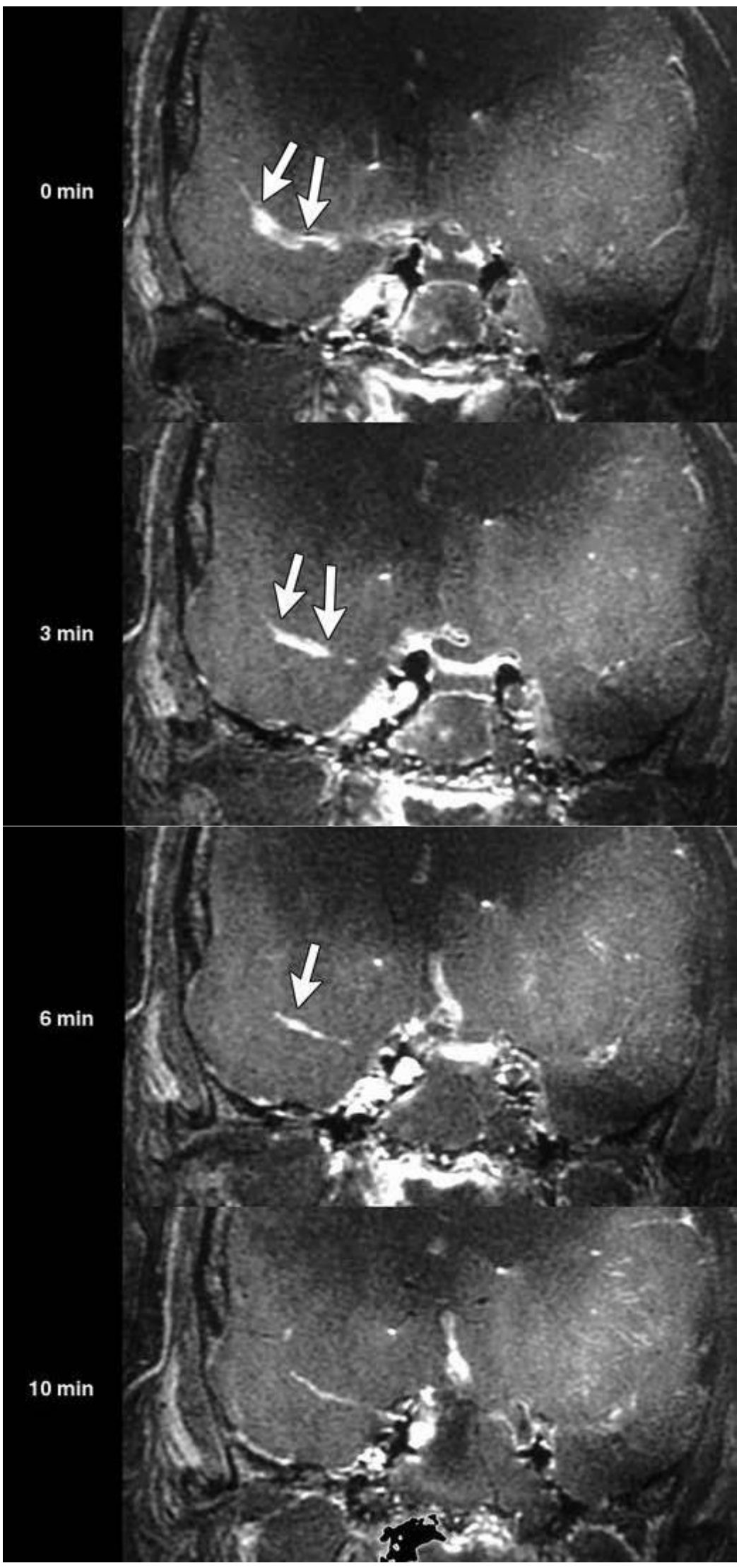


(Ghanouni et al. 2015)

## BIOEFFECTS AND THEIR ROLE IN PEDIATRIC NEUROSURGERY

- children have thinner skulls (difficult stereotactic frame pinning) but, neonates in particular, possess a natural acoustic window through their fontanelle.
- neonates require MR-compatible incubators and dedicated neuro-interventional coils for imaging.

J. Drake et al. group (Canada) developed HIFU for Pediatric Operations (HOPE) – a pediatric neurosurgical treatment system for:

1) focal brain ablation/disconnection for medical refractory epilepsy
2) lysis of intra-ventricular hemorrhage.

- HOPE system integrates MR-compatible robot positioning device (positions the US transducer to an accuracy of 0.59 +/- 0.25 mm) and imaging coil integrated into the incubator.




Fig. 22 (abstract A22).
HOPE Concept (1 – incubator, 2 – coil, 3 – neonatal patient, 4 – transducer, 5 – robot and 6 – MR bore)

(Drake et al. 2016)

## STATE OF RESEARCH AND REGULATORY APPROVAL BY DEVELOPMENT STAGE

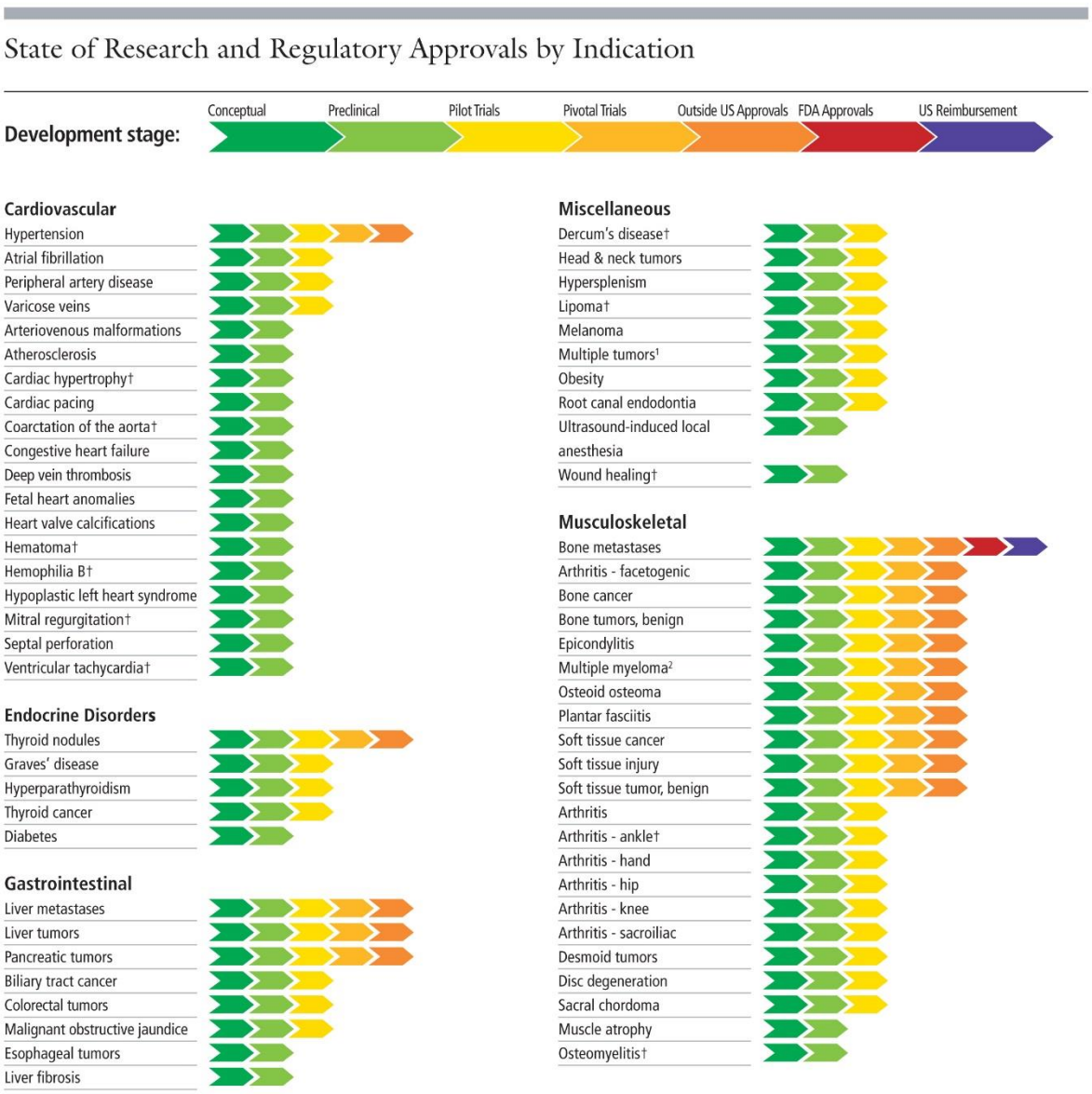

(FUS foundation, July 2020) >>

FUS is not approved by any regulatory bodies worldwide as a treatment for brain tumors!

November 15, 2016: Centers for Medicare and Medicaid Services (CMS) has set the institutional payment for FUS treatment for essential tremor at approximately $10,000.

- after 2 years CMS will reevaluate the payment level based on the actual costs of treatments performed during that interval.

## FDA-APPROVED COMMERCIALLY AVAILABLE PLATFORMS

**Sonablate** (SonaCare Medical, Charlotte, NC) – FDA-approved in 2015 for ablation of prostate tissue (BPH, prostate cancer)

**Ablatherm** (EDAP TMS S.A., France) – FDA-approved in 2015 for ablation of prostate tissue (BPH, prostate cancer)

**ExAblate Neuro** (InSightec LTD, Israel) – FDA-approved for bone metastasis and uterine fibroids; FDA-approved for essential tremor in July 2016 (cf. DBS for essential tremor was FDA approved in 1997).

- 13 centers in USA (June 2018 data).
- price approx. 2 mln.
- approved in Europe and Korea also for the Parkinsonian tremor, neuropathic pain, depression, obsessive-compulsive disorder, osteoid osteoma.
- hemispheric, 650 kHz, 1024 element, phased-array transducer that is coupled to 3T MRI:

## PROCEDURAL DETAILS

- head is shaved.
- patient is placed in a stereotactic frame that is coupled to MRI-compatible FUS transducer.
- elastic barrier is placed over the frame that is filled with chilled, degassed water in order to prevent excessive scalp heating and minimize acoustic scatter:

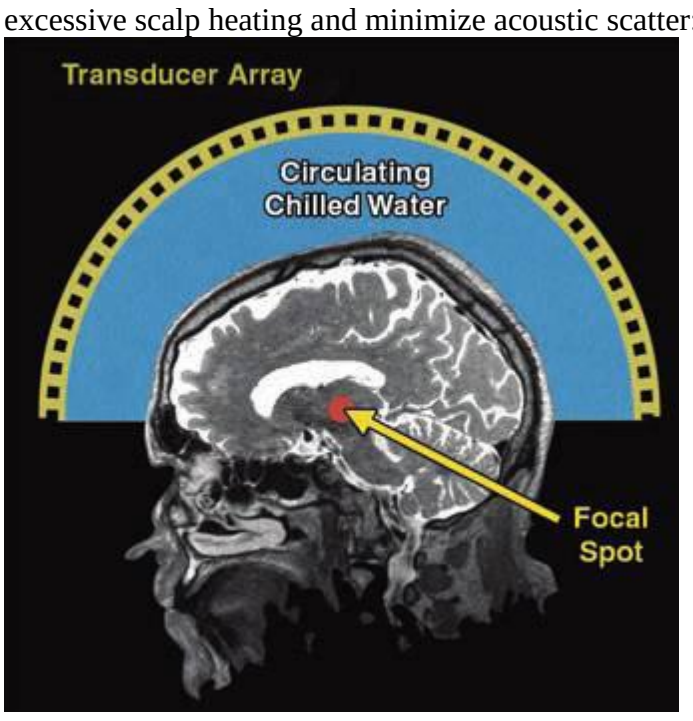


- anatomical MRI scans → fusion with preoperative CT (to allow for correction of skull thickness and density) → planning of stereotactic target:

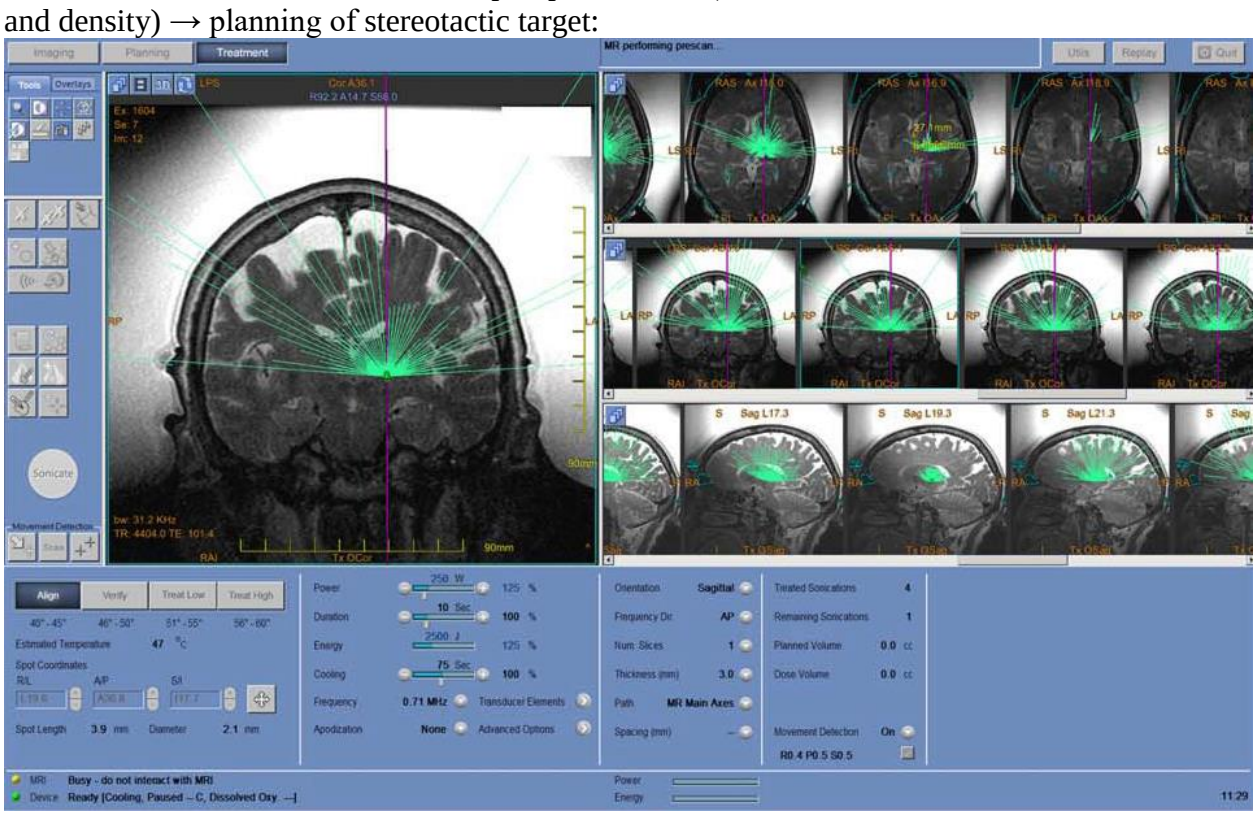

- treatment planning images are also used to delineate a safe sonication pathway using:
  CT - to mark intracranial calcifications in the choroid plexus, falx cerebri, basal ganglia, or vessels;
  MR - to demarcate no-pass regions around the sinuses and any air trapped between the elastic membrane and the scalp (because of the risk of ultrasound absorption and heating in these locations).
- fiducial markers are placed on the images along the ventricular and cortical margins to aid in movement detection.
- treatment plan is assessed to confirm that at least 700 elements of the transducer are active and that the skull area to be sonicated is at least 250 $cm^2$, allowing adequate distribution of ultrasound energy over the skull.
- acoustic low-level energy is administered with incremental increases to reach target temperature 40-45°C
- each brief sonication is monitored with MR thermometry, and the awake patient is clinically assessed for tremor reduction and adverse effects (tissue stunning effect lasts few minutes after turning US off – enough time to test patient):

- once target is confirmed, acoustic energy is sequentially titrated to therapeutic range (60°C) for tissue ablation (energy required is 10,000-20,000 Joules) while monitoring heat map:

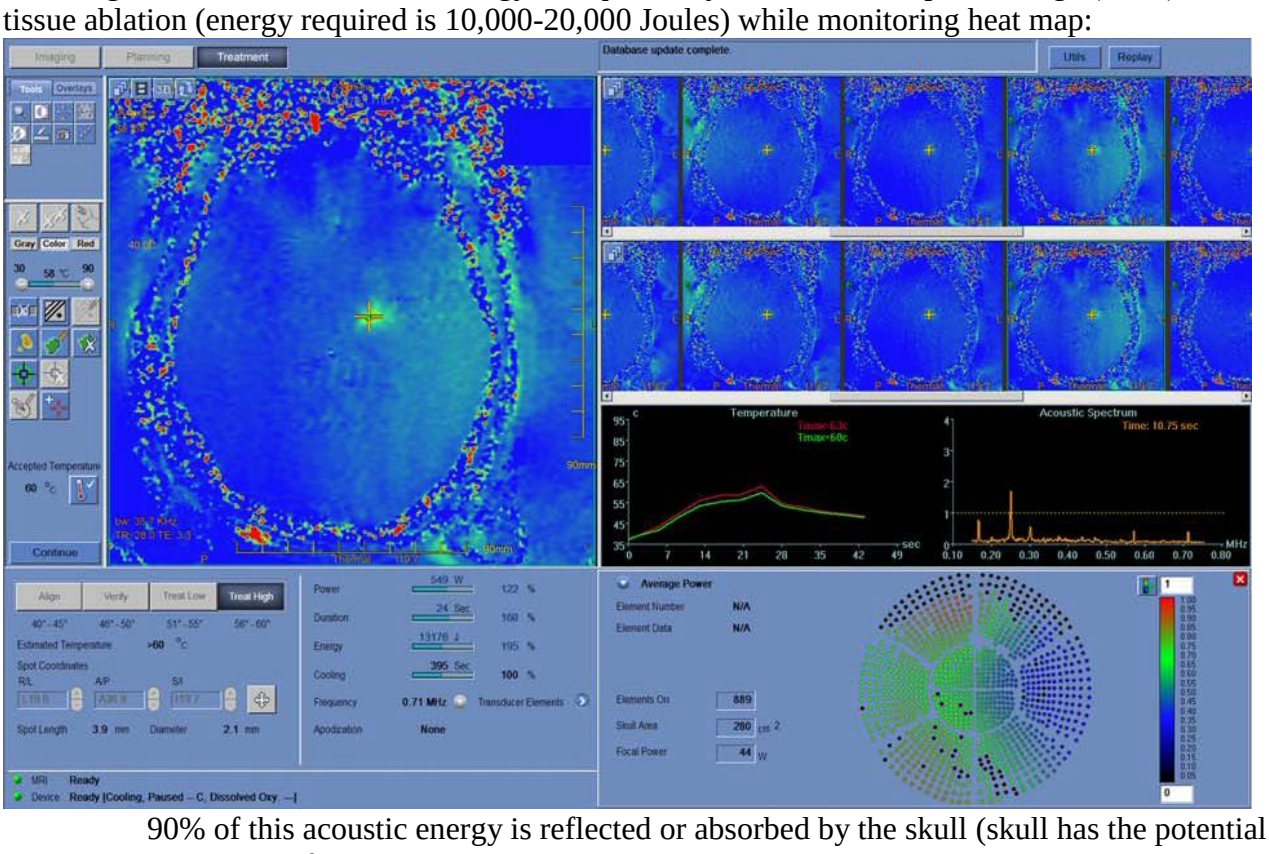


90% of this acoustic energy is reflected or absorbed by the skull (skull has the potential to heat significantly)
tremor suppression is usually first noted at ≈ 50°C (stunned brain target)
Cardioversion uses only 50-360 Joules!

- predictable changes in MRI (T2 and T1) on POD1:

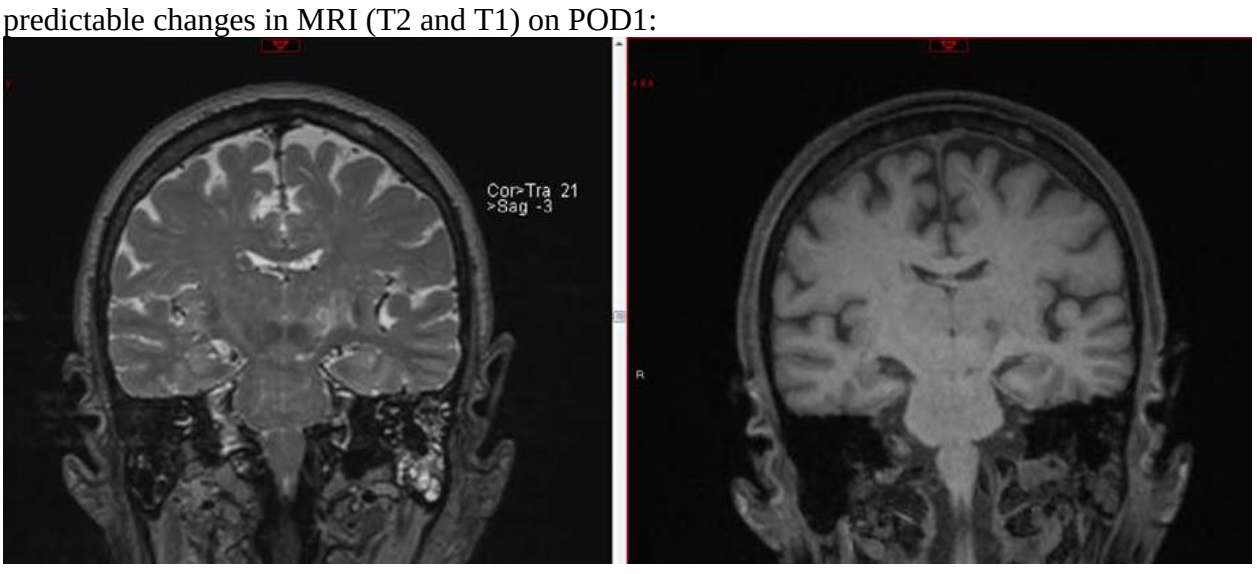


MRI features after MRg-FUS ablation of left VIM. FUS lesion (arrows) appears on T2-weighted images at 24 hours and initially restricts diffusion. It shows faint enhancement at 1 month, and cavity collapses by 3 months. Blood product staining is seen immediately after MRI-guided FUS treatment and persists over time:

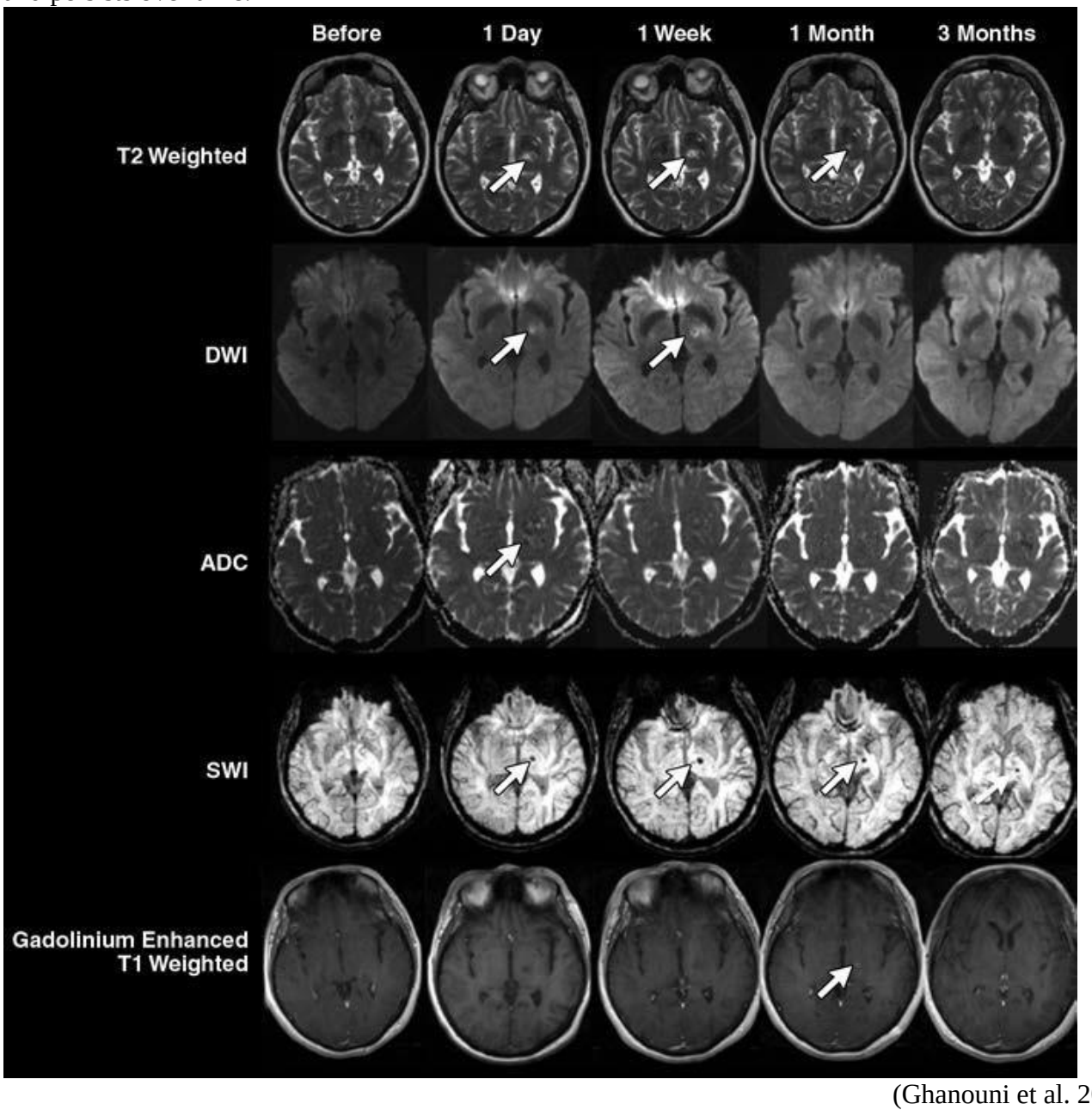


(Ghanouni et al. 2015)

T2: Zones 1 and 2 represent coagulation necrosis and cytotoxic edema; the poorly marginated slightly T2 hyperintense zone 3 at the periphery represents vasogenic edema. Zone 3 is typically seen between 24 hours and 1 week and then resolves. Zones 1 and 2 evolve into a round or oval cavity at 1 week and 1 month and collapse by 3 months. Small amounts of blood products, but no frank hemorrhage, are seen at the target site immediately after the MRI-guided FUS treatment and afterward. A few patients

displayed very mild and transient enhancement at the target site at 24 hours, likely resulting from the reversible alteration of the BBB caused by the MRI-guided FUS treatment. Enhancement reappeared by 1 week and peaked at 1 month, possibly related to neovascularization.

# COMPLETED TRIALS

## ESSENTIAL TREMOR TRIAL

The NEW ENGLAND JOURNAL of MEDICINE
N ENGL J MED 375;8 NEJM.ORG AUGUST 25, 2016

ORIGINAL ARTICLE

### A Randomized Trial of Focused Ultrasound Thalamotomy for Essential Tremor

W. Jeffrey Elias, M.D., Nir Lipsman, M.D., Ph.D., William G. Ondo, M.D., Pejman Ghanouni, M.D., Ph.D., Young G. Kim, M.D., Ph.D., Wonhee Lee, M.D., Ph.D., Michael Schwartz, M.D., Kullervo Hynynen, Ph.D., Andres M. Lozano, M.D., Binit B. Shah, M.D., Diane Huss, D.P.T., N.C.S., Robert F. Dallapiazza, M.D., Ph.D., Ryder Gwinn, M.D., Jennifer Witt, M.D., Susie Ro, M.D., Howard M. Eisenberg, M.D., Ph.D., Paul S. Fishman, M.D., Ph.D., Dheeraj Gandhi, M.D., M.B., B.S., Casey H. Halpern, M.D., Rosalind Chuang, M.D., Kim Butts Pauly, Ph.D., Travis S. Tierney, M.D., Ph.D., Michael T. Hayes, M.D., G. Rees Cosgrove, M.D., Toshio Yamaguchi, M.D., Ph.D., Keiichi Abe, M.D., Takaomi Taira, M.D., Ph.D., and Jin W. Chang, M.D., Ph.D.

International, multicenter, prospective, randomized, double-blinded, sham-controlled trial
ClinicalTrials.gov number: NCT01827904

Sites:
1) University of Virginia
2) Toronto Western Hospital
3) Sunnybrook Health Sciences Centre (Toronto)
4) Methodist Neurological Institute (Houston)
5) Stanford University
6) Swedish Neuroscience Institute (Seattle)
7) University of Maryland
8) University of Miami
9) Brigham and Women's Hospital
10) Yonsei University (South Korea)
11) Shin-yurigaoka General Hospital (Japan)
12) Tokyo Women's Medical University (Japan)

Trial design
- 76 patients with moderate-to-severe, medication-refractory* essential tremor.
  *failed at least two trials of medical therapy.
- skull density ratio (ratio of cortical to cancellous bone on CT) of ≥ 0.45.
- patients were blinded and randomly assigned in a 3:1 ratio to undergo:
  a) unilateral FUS thalamotomy with ExAblate Neuro (InSightec)
  b) sham procedure.
- there were no significant differences in baseline characteristics between the two study groups:

Table 1. Baseline Demographic and Clinical Characteristics of the Study Participants.*

| Characteristic | FUS Thalamotomy (N=56) | Sham Procedure (N=20) |
|---|---|---|
| Age — yr | 70.8±8.7 | 71.4±7.3 |
| BMI† | 26.9 | 27.9 |
| Male sex — no. (%) | 37 (66) | 15 (75) |
| Race or ethnic group — no. (%)‡ | | |
| White | 41 (73) | 16 (80) |
| Black | 0 | 0 |
| Asian | 14 (25) | 4 (20) |
| Hispanic | 0 | 0 |
| Other | 1 (2) | 0 |
| Disease duration — yr | | |
| From initial symptoms | 28.3±16.4 | 27.9±14.9 |
| From initial diagnosis | 16.4±13.1 | 17.8±10.2 |
| From start of medical therapy | 13.9±10.7 | 14.7±10.5 |
| Tremor score§ | | |
| Hand | 18.1±4.8 | 16.0±4.4 |
| Overall | 50.1±14.0 | 44.1±12.7 |

- only the treatment team was aware of the group assignments.
- tremor assessments by blinded neurologists - at baseline, at 1, 3, 6, and 12 months postop.
- 32-point tremor scale (higher scores = more severe tremor).
- primary outcome - the between-group difference in the change from baseline to 3 months in contralateral hand tremor.
- open-label extension cohort: after 3 months, patients in the sham-procedure group could cross over to active treatment group.

RESULTS
- hand-tremor scores improved:
  FUS group: 18.1 → 9.6 (delta 8.5 = 47% improvement)
  sham group: 16.0 → 15.8 (delta 0.2 = 0.1% improvement)
- between-group difference: 8.3 points (5.9-10.7 CI 95%; P < 0.001).

Individual tremor responses at 3 months:

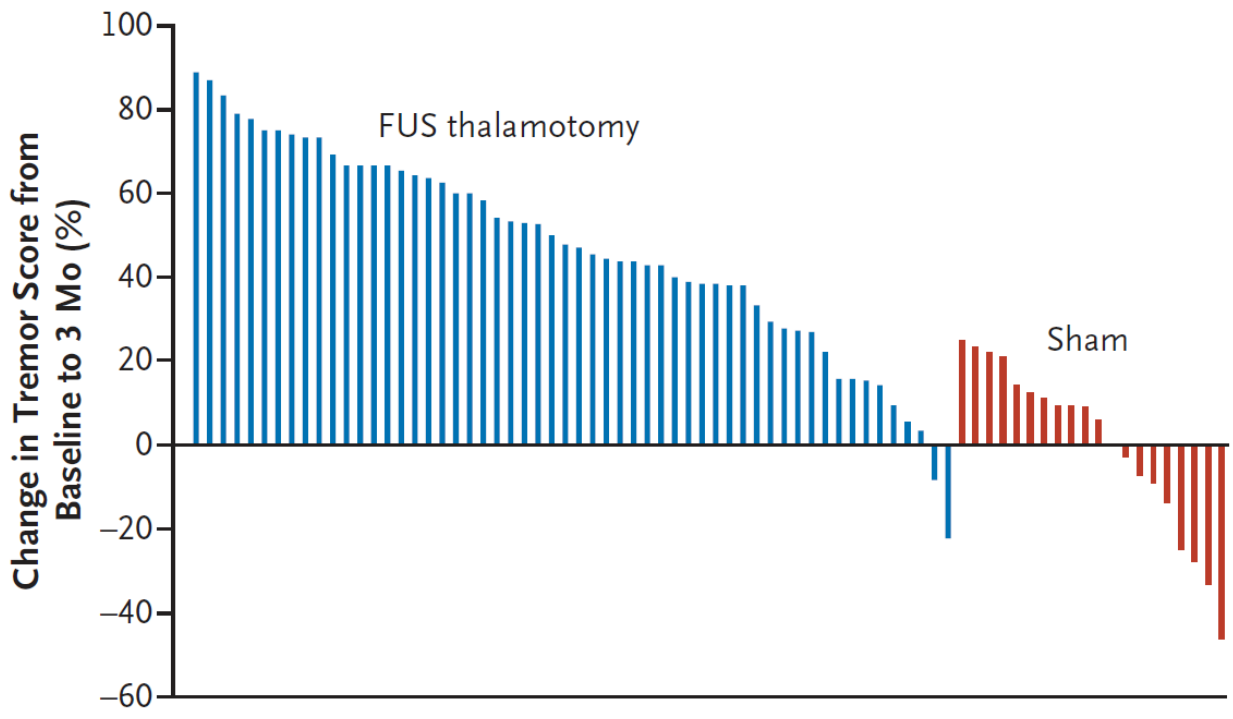

- improvement in the FUS group was still maintained at 12 months (change from baseline, 7.2 points = 40% improvement).
  Compare to pilot trial - mean tremor reduction of 75% at 1 year

Tremor scores at baseline and throughout the 12-month study period:

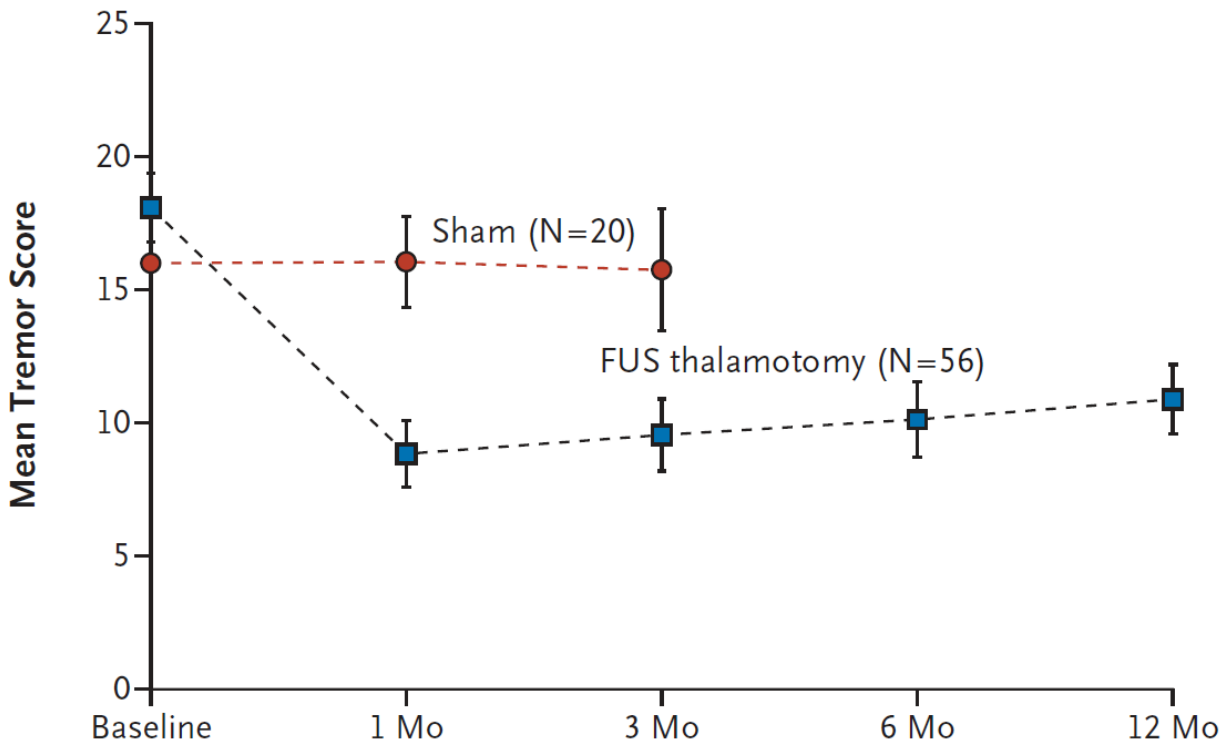


- cross-over group had tremor improvement by 55% at 3 months and by 52% at 6 months
- secondary outcome also improved with FUS treatment:
  disability – 62% vs. 3% reduction (P < 0.001)
  quality of life – 46% vs. 3% reduction (P < 0.001)
- 30% of patients in FUS group (vs. 0% in sham group) reported "heat" or "pressure" inside the head during procedure (resolved within seconds postop).
- in 5 patients, the full therapeutic temperature could not be achieved, despite adequate acoustic energy (probably due to individual cranial characteristics).
- the stereotactic target had to be adjusted (based on intraoperative clinical or imaging feedback) by 1.6±1.1 mm (range, 1.1 to 5.5) in 39 patients.
- adverse events in FUS group:
  1) gait disturbance - 36% patients (9% at 12 months)
  2) paresthesias or numbness - 38% patients (14% at 12 months)
  3) contralateral weakness (internal capsule effect) - 4% patients (2% at 12 months)
  4) no infectious or hemorrhagic events
  5) the intensity of side effects seemed to peak at approximately 1 week, corresponding to the maximal size of the lesion with perilesional edema.

Table 2. Adverse Events.*

| Adverse Event | FUS Thalamotomy (N=56) | | | | | | | Sham Procedure (N=20) |
|---|---|---|---|---|---|---|---|---|
| | Total | 1 Day | 7 Days | 1 Mo | 3 Mo | 6 Mo | 12 Mo | |
| | *number of patients (percent)* | | | | | | | |
| Paresthesia or numbness | | | | | | | | |
| Any region | 21 (38) | 18 | 17 | 16 | 14 | 11 | 8 (14) | 1 (5) |
| Both face and hand | 6 (11) | 5 | 5 | 5 | 5 | 5 | 5 (9) | |
| Face, lips, and tongue | 8 (14) | 7 | 6 | 6 | 6 | 4 | 2 (4) | |
| Hand and fingers | 6 (11) | 5 | 5 | 4 | 2 | 1 | 1 (2) | 1 (5) |
| Leg | 1 (2) | 1 | 1 | 1 | 1 | 1 | | |
| Taste disturbance | 3 (5) | 3 | 2 | 2 | 2 | 2 | 2 (4) | |
| Gait disturbance† | | | | | | | | |
| Any, objective or subjective | 20 (36) | 19 | 18 | 13 | 9 | 7 | 5 (9) | 1 (5) |
| Ataxia, noted objectively on examination | 11 (20) | 11 | 10 | 6 | 2 | 2 | 2 (4) | |
| "Unsteady" or "unbalanced," reported subjectively by examiner or patient | 9 (16) | 8 | 8 | 7 | 7 | 5 | 3 (5) | 1 (5) |
| Dysmetria, limb | 7 (12) | 7 | 7 | 5 | 5 | 4 | 2 (4) | |
| Weakness, contralateral | 2 (4) | 2 | 2 | 2 | 2 | 2 | 1 (2) | |
| Dysarthria | 1 (2) | 1 | 1 | 1 | 1 | 1 | | |
| Dysphagia | 1 (2) | 1 | 1 | 1 | 1 | 1 | | |
| Headache lasting >1 day | 8 (14) | 8 | 4 | 4 | 2 | 2 | | 4 (20) |
| Fatigue | 3 (5) | 3 | 3 | 2 | 1 | | | 1 (5) |
| Disequilibrium sensation | 5 (9) | 5 | 5 | 5 | 3 | 2 | 1 (2) | |
| Tinnitus | 3 (5) | 3 | 3 | 1 | | | | |
| Intraprocedural sensations or events‡ | | | | | | | | |
| Head discomfort: "heat" or "pressure" | 17 (30) | | | | | | | |
| Vertigo: "dizzy" | 12 (21) | | | | | | | |
| Nausea | 11 (20) | | | | | | | 2 (10) |
| Vomiting | 2 (4) | | | | | | | |
| Scalp tingling | 4 (7) | | | | | | | 1 (5) |
| Back pain | 5 (9) | | | | | | | 1 (5) |
| Anxiety | 3 (5) | | | | | | | 2 (10) |
| Pin-site pain, edema, or bruising attributable to placement of the stereotactic frame | 17 (30) | | | | | | | 7 (35) |
| No adverse events | 6 (11) | | | | | | | 8 (40) |

Conclusions

- thalamotomy significantly (nearly 50%) reduced hand tremor at 3 months, and the effect (40% improvement) persisted during the 12-month study period – these are results for advanced, medically-refractory ET and yet results are better than medical management at early disease stages.
- tremor reduction was related to treatment, not a placebo effect.
- FUS lesioning can result in permanent neurological deficits.

# CONCLUSIONS

Currently, only ***thermal*** ablation is in clinical practice!

## ADVANTAGES

- FUS can noninvasively transmit high-intensity acoustic energy with a high degree of accuracy, precision, and safety to the targets within the skull.
- FUS offers exciting options for the incisionless treatment of numerous neurological disorders through numerous mechanisms as either a stand-alone or (neo)adjuvant treatment modality:
  1) ablative applications of FUS in the brain are already implemented clinically.
  2) sonodynamic therapy, radiosensitization, drug delivery, and immunomodulation have been more extensively explored in other organ systems than in brain.
- the closest competitor is SRS; FUS advantages over SRS:
  1) SRS dose gradient is less sharp
  2) SRS does not allow intraoperative target validation (neither clinical nor imaging)
  3) SRS effects are delayed
  4) SRS carries risks of radiation side effects

- there are preliminary works of combining SRS and FUS for tumor treatment (Schlesinger et al. 2017) - FUS may be used to debulk the main tumor mass, and radiation to treat the surrounding tumor bed.

## DISADVANTAGES / CHALLENGES

- FUS is not a "walking in the park" type of the procedure – patient needs to spend 3-4 hours inside the MRI scanner bore with the shaved head immobilized in pins.
- FUS is able to create true intracranial lesions with the attendant risks of permanent adverse effects, so FUS cannot be called "noninvasive".
  - described cases of lethal hemorrhage in brain tumor ablation.
- due to limitations* of current technology, FUS cannot be applied to posterior fossa, skull base**, and cortical areas

  *limited thermal ablation treatment envelope of current phased-array transducers.
  **if a focal point is selected near the skull base, the beam in the far field (beyond the focal point) will rapidly heat the bone and potentially damage nearby neural and vascular structures

The treatment envelope of Exablate 4000 is shown as a green area - minimum of 800 elements of the transducer can successfully transmit ultrasonic beams from the emitter surface to the focal spot, unimpeded by intervening skull or soft tissue. In the yellow and red areas, the number of the elements available for efficient ultrasound transmission is reduced respectively to 700 and 600, respectively. In these areas, the delivery of ultrasound beams may not produce the thermal intensity necessary to achieve ablation at the focal point. The clinically adopted targets, such as the ventrolateral thalamus, the subthalamic nucleus, and the anterior limb of the internal capsule, are included within the treatment envelope:

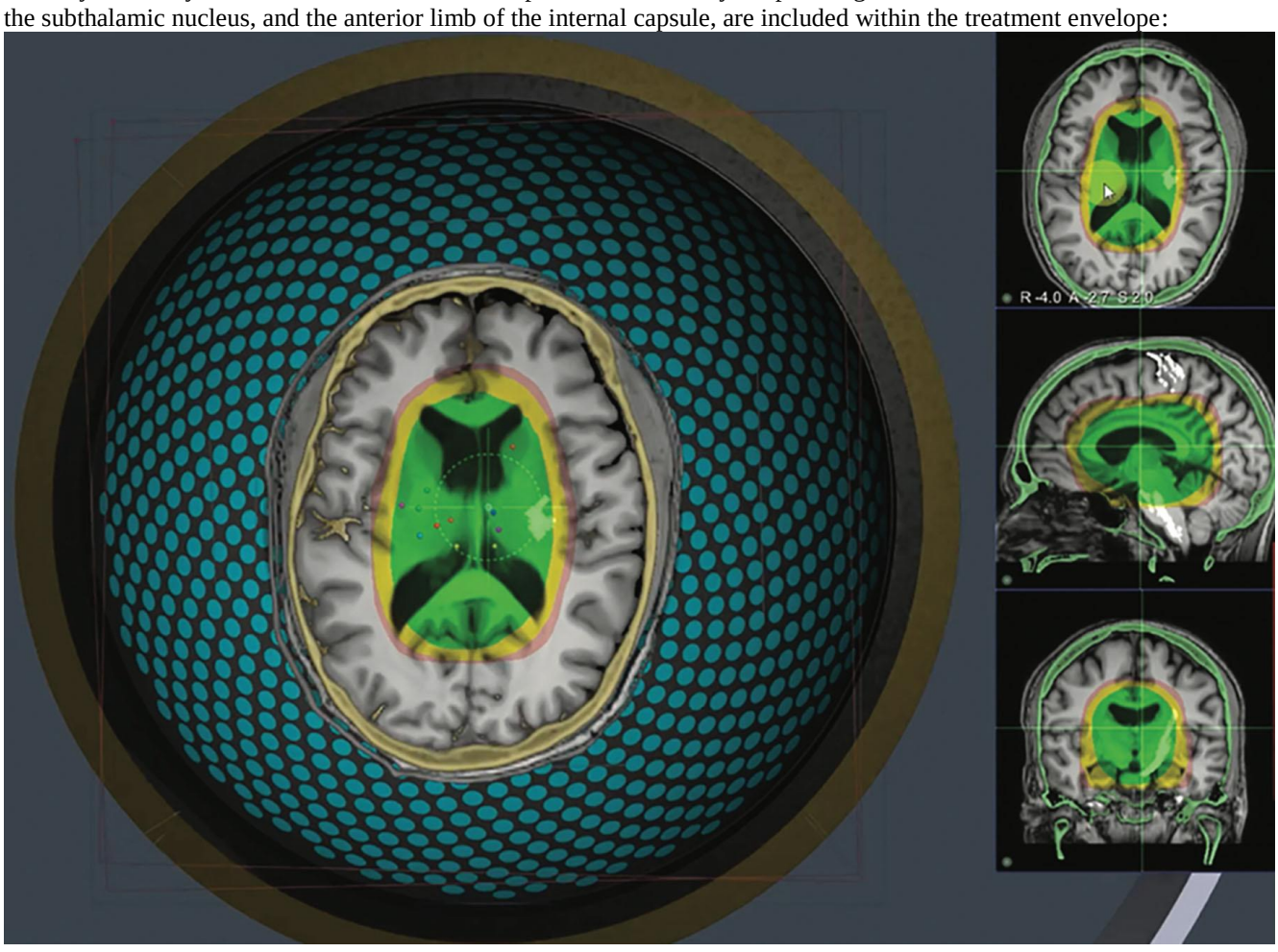


  - experimental ***nonthermal*** ablative mechanisms (**Cavitation-Enhanced Ablation using microbubbles***, **Histotripsy without microbubbles****) may circumvent this limitation.

    *mechanical damage to the microvasculature → localized ischemic tissue necrosis; other mechanisms, such as vascular spasm or the trapping or coalescence of microbubble fragments, could be involved.
    **physical parameters (very short-lasting pulses) of histotripsy allow for the creation of sharply conformed and even irregular lesions, thus avoiding damage to surrounding tissues even when treating lesions with complex geometries; histotripsy can be safely delivered more quickly and to larger areas than thermal ablation, including regions in close proximity to the skull surface; possible clinical applications – liquefaction of intracerebral hemorrhage-related clot volumes, fibrous tumors, multifocal intra-axial tumors.

- currently in the U.S., FUS is most commonly used for the ablation of uterine fibroids and prostate cancer; therefore, the postmarketing experience for neurological applications is still in the early stages.
- treatment of tumors (vs. functional applications) is challenging: tumor location may be anywhere in the brain, tumors tend to be more vascular and made of nonhomogeneous tissue, and it may require a large treatment volumes; possible solution - low frequency FUS to increase treatment envelope (but also higher risk of cavitation injury) - 220 kHz ExAblate Neuro system with a real-time cavitation monitoring system is in development.

# FUS Publications

Per year

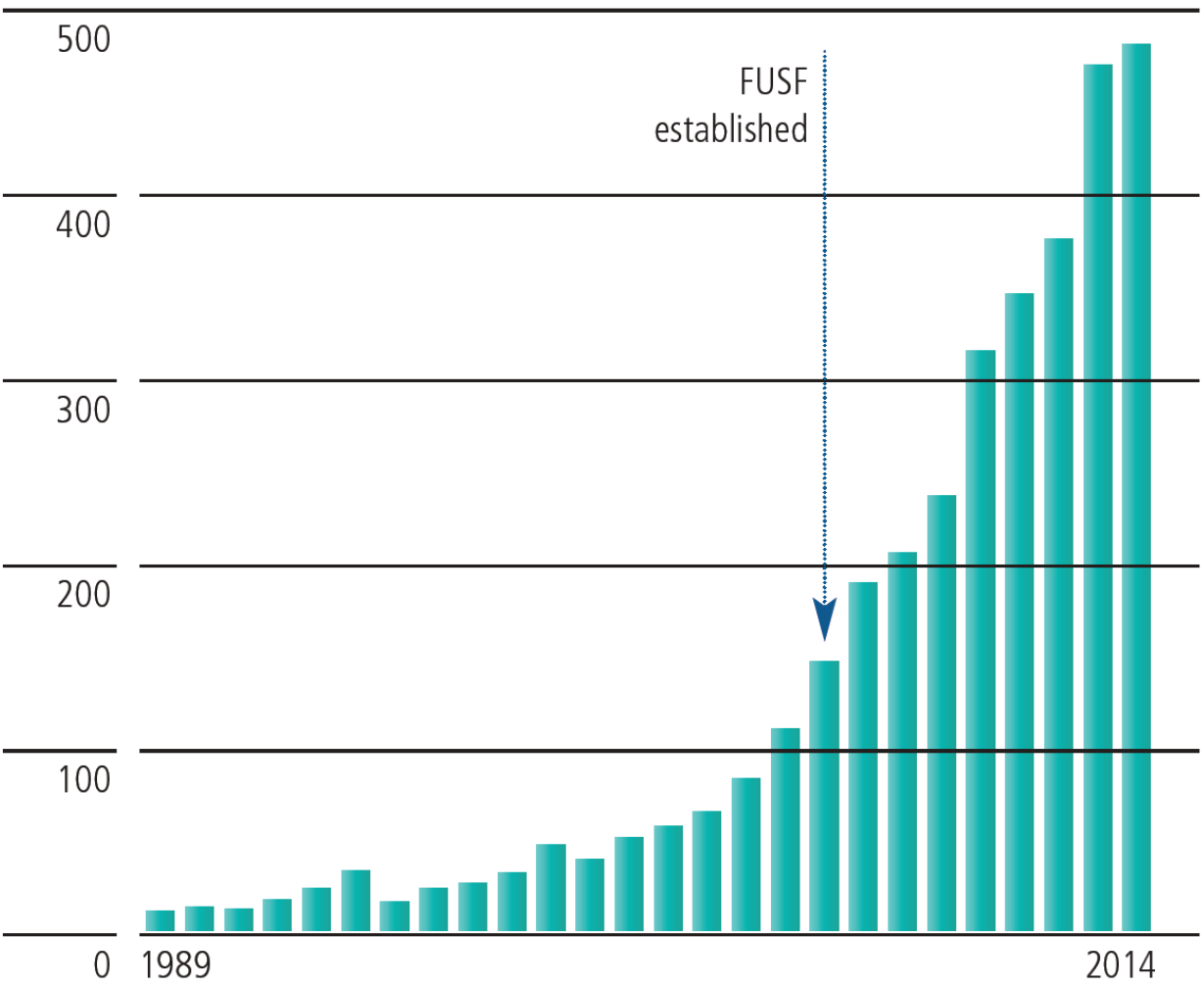


Source: Data from Medline as of February 2016.

Publications for 2015 are still being indexed by Medline and are not included in this graph.

# Total Awards for All FUS NIH Research Grants

Dollars in millions

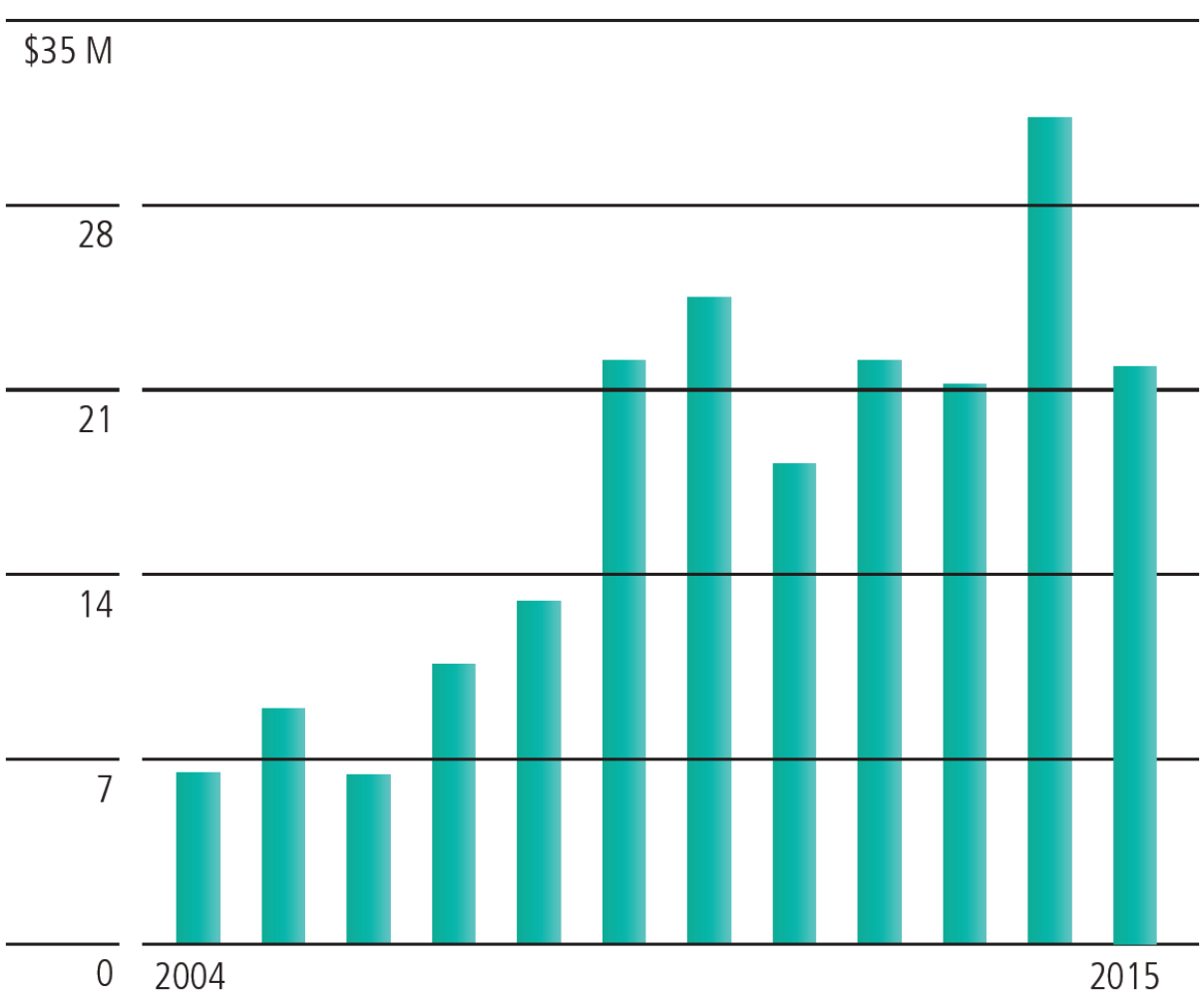


Source: NIH

## OTHER FACTS

The InSightec system is approximately $2 mil-this would be for the transducer that we would use for movement disorders (target area is 20-30 mm around AC/PC). There is another transducer currently under development that will be able to go more laterally and create larger lesions.

**Tres Glenn**
Customer Executive-East Zone, Americas
M: 214-399-0313
tresg@insightec.com | us.insightec.com

BIBLIOGRAPHY

1. **FUS foundation**: https://www.fusfoundation.org
2. FUS foundation: An Overview of the Biological Effects of Focused Ultrasound (July 2015)
3. Bond (2016) - Randomized, Sham-Controlled Trial of Transcranial Magnetic Resonance-Guided FUS Thalamotomy
4. Elias (2016) - A Randomized Trial of Focused Ultrasound Thalamotomy for Essential Tremor
5. FUS foundation: Focused Ultrasound for Glioblastoma Workshop
6. Ghanouni (2015) - Transcranial MRI-Guided Focused Ultrasound - A Review of the Technologic and Neurologic Applications
7. Hersch (2016) - Emerging Applications of Therapeutic Ultrasound in Neuro-oncology
8. Weintraub (2016) - The emerging role of transcranial magnetic resonance imaging-guided focused ultrasound in functional neurosurgery
9. Wu (2017) - Pulsed-wave low-dose ultrasound hyperthermia selectively enhances nanodrug delivery ...to brain mts

Viktor's Notes℠ for the Neurosurgery Resident
Please visit website at www.NeurosurgeryResident.net