

# Anterior Neck Injury

Last updated: April 20, 2019

Zones of neck ..... 1

**ETIOLOGY** ..... 2

**CLINICAL FEATURES** ..... 2

**DIAGNOSIS**..... 2

**TREATMENT** ..... 3

    PREHOSPITAL ..... 3

    HOSPITAL..... 3

        Blunt injuries ..... 3

        Penetrating injuries..... 3

**PROGNOSIS**..... 4

**SPECIAL SITUATIONS**..... 4

    CAROTID TRAUMA ..... 4

    VERTEBRALIS TRAUMA ..... 4

    LARYNGOTRACHEAL TRAUMA ..... 4

    ESOPHAGEAL TRAUMA..... 5

        Clinical Features..... 5

        Diagnosis ..... 5

        Treatment ..... 5

    PHARYNGEAL TRAUMA ..... 6

    STRANGULATION ..... 6

        Pathophysiology ..... 6

        Clinical Features..... 6

        Management ..... 6

        Prognosis ..... 7

**ANTERIOR NECK INJURY** - *one of greatest emergencies* - multitude of organ systems are compressed into compact conduit (single seemingly innocuous penetrating wound is capable of considerable harm - airway occlusion, exsanguinating hemorrhage, etc).

- anterior and lateral neck regions are most exposed to injury.

Structures at risk of injury:

**Musculoskeletal structures** – vertebrae, cervical muscles, tendons, ligaments, clavicles, first and second ribs, hyoid bone.

**Neural structures** – spinal cord, phrenic nerve, brachial plexus, recurrent laryngeal nerve, CN9-12, stellate ganglion.

**Vascular structures** – carotid (common, internal, external) and vertebral arteries; vertebral, brachiocephalic, and jugular (internal and external) veins.

**Visceral structures** – thoracic duct, esophagus and pharynx, larynx and trachea.

**Glandular structures** – thyroid, parathyroid, submandibular, parotid.

Two FASCIAL LAYERS invest neck:

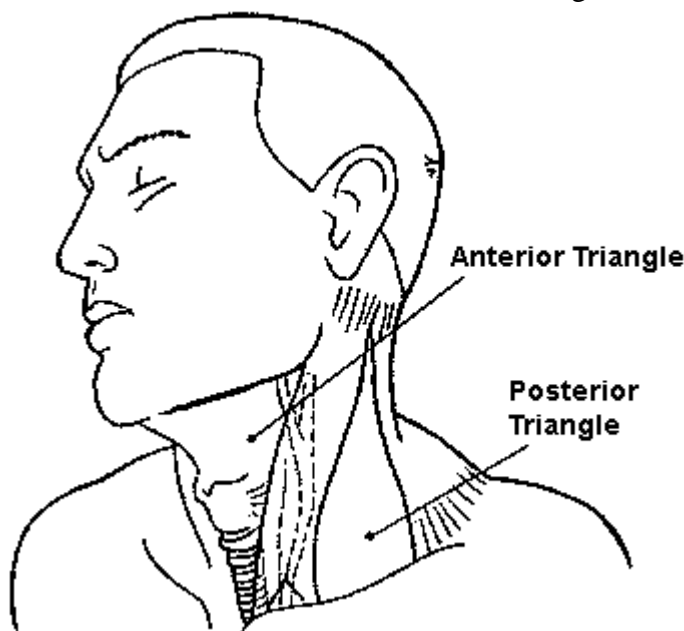
**SUPERFICIAL FASCIA** (enveloping platysma muscle)

**DEEP FASCIA** - envelops sternocleidomastoid and trapezius muscles; demarcates:

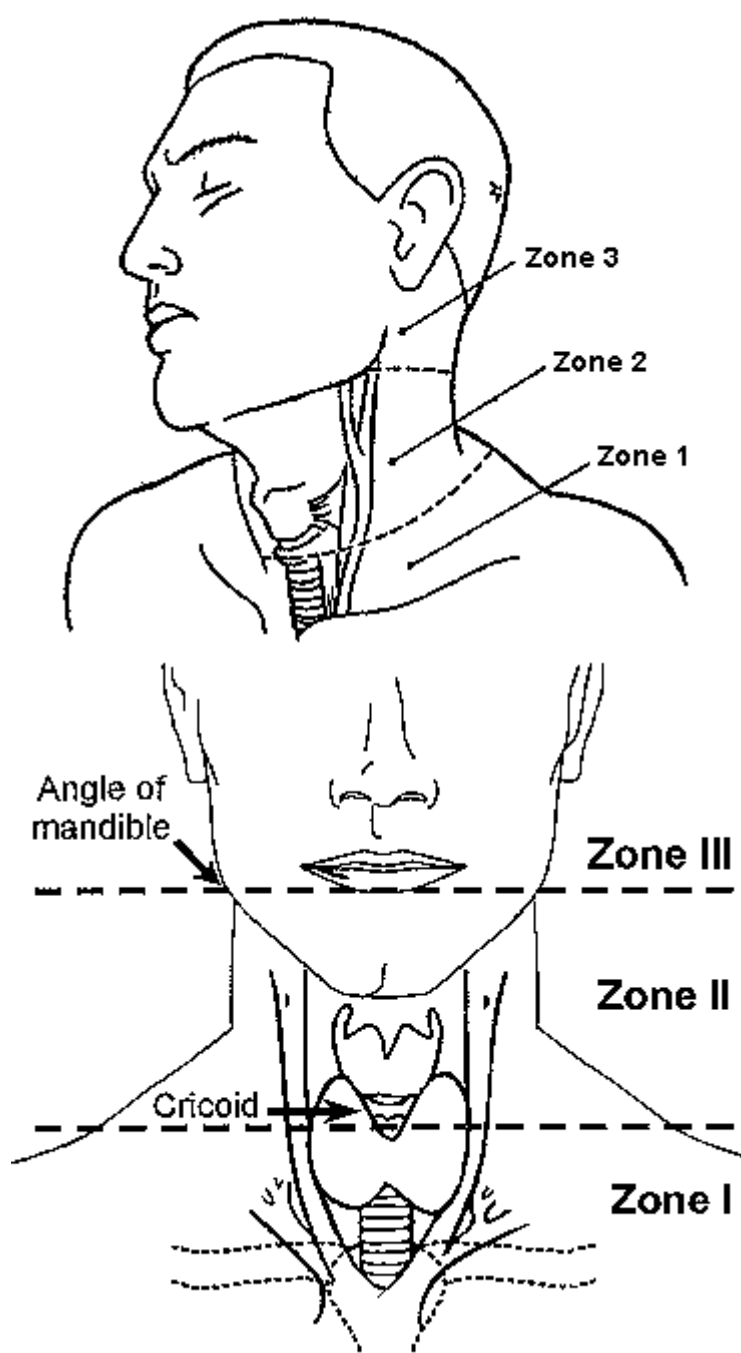
- 1) **pretracheal region** (trachea, larynx, thyroid gland, pericardium)
- 2) **prevertebral region** (prevertebral muscles, phrenic nerve, brachial plexus, axillary sheath)
- 3) **carotid sheath** (carotid artery, internal jugular vein, vagus nerve).

## ZONES OF NECK

- sternocleidomastoid separates neck into *ANTERIOR* and *POSTERIOR* triangles:



majority of important vascular and visceral organs lie within *ANTERIOR* triangle;  
few vital structures cross *POSTERIOR* triangle (only individual nerves to specific muscles), with exception of region just superior to clavicle, spinal cord and vertebral arteries.



**Zone III (superior neck)** - bounded by *angle of mandible* and *base of skull*.

- injuries can be very difficult to access surgically.
- structures at greatest risk: distal carotid artery, salivary glands, pharynx.

**Zone II (midportion of neck)** - region from *cricoid cartilage* to *angle of mandible*.

- largest portion – injuries are most common!
- injuries are likely to be most apparent on inspection (aggressive surgical exploration is rarely necessary) – leads to **best prognosis!**

**Zone I (neck base and thoracic outlet)** - demarcated by *thoracic inlet* inferiorly and *cricoid cartilage* superiorly.

- injuries are associated with **highest morbidity and mortality rates!** (because of major vascular and intrathoracic injury).
- structures at greatest risk: great vessels (subclavian vessels, brachiocephalic veins, common carotid arteries, aortic arch, jugular veins), trachea, esophagus, lung apices, cervical spine, spinal cord, cervical nerve roots.

Zone I wounds are often **associated with thoracic injury!** (pneumothorax, hemothorax)

*pneumothorax may not develop until positive pressure ventilation is applied during anesthesia (may present as unexplained hypotension)*

## ETIOLOGY

**Penetrating trauma** (> 95% result from *guns* and *knives*).

**Blunt trauma** typically results from *motor vehicle crashes* (other causes - sports-related injuries, “clothesline” injuries\*, strangulation, blows from fists or feet, excessive manipulation).

\*rider of motorcycle, snowmobile, horse, or bicycle runs into unseen wire or cord suspended between two stationary objects

## CLINICAL FEATURES

- presence or absence of symptoms can be misleading, serving as poor predictor of underlying damage (e.g. only 10% blunt vascular damages manifest in first hour).
- sensitivity of physical examination to identify all significant neck damage remains controversial.
  - physical examination alone is sufficient to assess zone II for injury (others believe that diagnostic testing is mandatory in all cases).
  - *single examination is not sufficient* (onset of signs of injury may be delayed).
- **any violation of platysma** - potential for grave damage to neck contents.
- unnecessary wound probing / manipulation, performing any action that causes patient to gag, choke, or cough is discouraged – all these **may dislodge clot** and provoke life-threatening hemorrhage.
- **subcutaneous emphysema** means disruption of either upper airway or esophagus.
- **loss of characteristic lateral profile of anterior neck** (prominence of thyroid cartilage, etc) indicates edema or bleeding.
- consequences of vascular injuries: Auscultate neck to reveal carotid bruit!
  - 1) life-threatening external hemorrhage.
  - 2) soft tissue hematoma can distort / obstruct airway.
  - 3) disruption of cerebral perfusion (e.g. complete transection of carotid artery, air embolization after neck vein tear).

## DIAGNOSIS

1. **Cervical X-ray**: fractures, subcutaneous or retropharyngeal emphysema, retropharyngeal hematoma, tracheal narrowing or deviation, presence of foreign body.
  - risk of unstable cervical spine injury after **PENETRATING** neck wound is minimal; X-ray serves to detect soft tissue changes (e.g. in preventing catastrophic rupture of retropharyngeal hematoma during intubation).
1. **Chest X-ray** – indicated for at least **zone I** wounds: hemothorax, pneumothorax, widened mediastinum, mediastinal emphysema, apical pleural hematoma, foreign bodies.
2. Neck **CT** – mainly to evaluate laryngotracheal injuries in stable patients (CT readily identifies clinically subtle **blunt injuries of larynx**).
3. 4-vessel **angiography** – criterion standard for evaluation of vascular trauma; indications:
  - 1) penetrating wounds to zones I and III.
  - 2) blunt trauma when neurologic deficits are inconsistent with findings on head CT.
  - 3) therapeutic embolization.
4. **CTA** is alternative to angiography.

5. **MRI** – for evaluation of neurological impairments.
6. **Color flow Doppler studies** – for suspected (asymptomatic) blunt carotid injuries.
7. **Contrast studies of esophagus** with:
  - Gastrografin* - less likely to cause inflammatory response if extravasation through breach occurs.
  - ↓ negative
  - Barium* - induces less inflammation in lungs if aspirated, better detects small leaks, makes subsequent endoscopy more difficult.
8. **Endoscopy** (laryngoscopy, bronchoscopy, pharyngoscopy, esophagoscopy)
  - defer examination until airway is protected (by intubation) and patient is anesthetized.

## TREATMENT

### PREHOSPITAL

Cervical spine precautions!!!

(risk of unstable cervical spine injury after penetrating neck wound is minimal)

Loss of airway patency may occur precipitously, but **try to avoid intubation** in prehospital setting!

- endotracheal intubation by field paramedics may mask high tracheal injury.
- **supplemental oxygen** and **clearing airway** of all secretions and foreign bodies frequently prove sufficient, practical, and helpful for conscious patient.
  - *tracheal / laryngeal fracture or closed injury* – calm patient and ask to breath very slowly (the only way to decrease wall collapse during inspiration), 100% oxygen → cricothyrotomy.
  - *tracheal / laryngeal penetrating injury* – place patient semiprone with lowered head end, suction blood from airways, 100% oxygen → intubation via wound / cricothyrotomy.
- cover **sucking neck wounds** or **lacerations exuding bubbling air** with **impregnated occlusive gauze dressing**.

Bleeding is best controlled with direct pressure – with hand (not bandage pressure!) and thick dressing; when dressing is soaked, it is not replaced, but covered with dry one on top.

- place patient supine, legs elevated.
- jugular vein injury (risk of air embolization) → **mild Trendelenburg position** (in left lateral decubitus position).
  - if embolus settles into right ventricle (sudden hypotension, tachycardia, “machinery murmur”, tachypnea) → right ventricle aspiration.
- *impaled objects* should not be extracted in field.
- do not blindly clamp blood vessels because other vital structures (e.g. nerves) travel alongside and may be irreparably damaged.
- **IV access** should be established in *upper extremity opposite side of injury* (in hospital add IV access site in *lower extremity*).
- if bleeding cannot be controlled / reached with direct pressure:
  - a) balloon tamponade with Foley catheter in wound.
  - b) temporary gauze packing (e.g. of pharynx wounds after intubation).

### HOSPITAL

Ensuring airway is highest priority! **Intubate early!**

- indications for emergency intubation: inadequate spontaneous respirations, blood / vomit obstructs airway, progressive cervical swelling from enlarging hemorrhage / emphysema threatens to occlude airway.
  - Procrastination converts simple intubation into difficult, bloody emergency tracheostomy!
- *endotracheal intubation with rapid sequence induction* is safe, effective, and preferable.
- be ready that intubation **may dislodge clots** → bleeding.
- **airway injury** (esp. **laryngeal injury**) is strong indication for **tracheostomy!** (intubation may detach larynx → complete loss of airway if larynx dislodges into chest).
- if airway is not jeopardized, nasogastric and endotracheal intubation may be deferred to allow endoscopic evaluation of larynx and hypopharynx (e.g. nasogastric / endotracheal tube can cause rebleeding from pharyngeal hematoma).

Shock should be vigorously resuscitated with crystalloid and blood; if hemodynamic stability cannot be achieved → prompt transfer to operating room.

Appoint assistant to maintain neck in neutral position → remove anterior aspect of collar → proceed with anterior neck evaluation:

### BLUNT INJURIES

- most can be managed nonoperatively.
- decision regarding admission is based on:
  - 1) presence of signs and symptoms
  - 2) patient's physiological status
  - 3) availability of outpatient care
- All but most trivial injuries should be admitted and observed for 24 hours.
- diagnostic workup is performed to establish need for surgery.
  - Blunt-injured patients can appear deceptively benign!
- **cervical & chest X-ray** are always necessary!
- signs of **vascular injury** (large hematoma, bruit) → **angiography** (regardless of neck zone), ± may be preceded by **color flow Doppler ultrasound**.
- signs of **laryngotracheal trauma** → **plain radiographs, CT, endoscopy**.
  - + always explore **esophagus** (**esophagogram** → **endoscopy**) - because of proximity of esophagus to trachea

### PENETRATING INJURIES

- with platysma violated (*platysma* is treated like *peritoneum* - if violated → assess by qualified surgeon).

Admit all patients (with violated platysma) for exploration or at least 24 hours observation  
 - to avoid missing occult injuries (esp. vascular and esophageal wounds – injuries with worst prognosis if treatment is delayed!!!).

- **cervical X-ray** is always necessary! (mainly, to detect soft tissue changes).
- **chest X-ray** is essential for **zone I** injuries.
- do not blindly probe wound in ED (in misguided attempt to determine extent of penetration)!!! – provides no useful information + may dislodge clot → bleeding, hemothorax!!!
  - N.B. can bleed internally – through neck wound connecting to pleural space! (if condition of patient with penetrating trauma deteriorates to cardiopulmonary arrest → emergent thoracotomy to gain better bleeding control)
- if **penetrating injury** is present in **zone I\* or III\*\*** → **angiography (aortography)\*\*\*** before any surgical exploration!!! (injuries to **zone II** are managed by exploration without prior invasive diagnostic studies)
  - \*possible injuries to thoracic outlet vessels
  - \*\*possible inaccessibility of internal carotid artery lesions
  - \*\*\*in all but most unstable patients

Strategies for penetrating injuries:

- A) **MANDATORY** exploration in operating room of all patients; major disadvantages - **exploration is negative in 46-50% cases + some injuries are missed** in spite of formal exploration.
- B) **SELECTIVE** exploration in operating room of following patients with **signs of significant injury**:
- vascular** – external hemorrhage, shock, expanding hematoma, diminished carotid pulse.
  - digestive tract** – dysphagia/odynophagia, subcutaneous air, blood in oropharynx.
  - airway** – hoarseness, stridor, dysphonia/voice change, hemoptysis, respiratory distress, air bubbling through wound.
  - neurologic** – lateralized neurologic deficit, altered state of consciousness, brachial plexus injury, Horner syndrome (stellate ganglion injury – near carotid).
- transcervical gunshot injuries** (> 80% likelihood of injury to cervical structures) → surgical exploration is warranted in nearly all cases!
  - for other patients (clinically silent), no definitive recommendation exists:
    - bronchoscopy, esophagography, esophagoscopy, and angiography for all injuries.
    - angiography + other studies only for suspected aerodigestive system injuries.
    - no workup + angiography only for wounds in zones I and III.

Because of prospect of occult injuries with **zone I and III wounds**, relatively aggressive workup is warranted!

Whether one adopts policy of mandatory or selective exploration, once decision to operate has been made, approach is same:

- exploration is performed under general endotracheal anesthesia.
- patient is always prepared for **possible median sternotomy**.
- INCISION** is planned to allow full exposure of tract of injury;
  - proximal and distal major vessel control** must be considered in length and position of incision.
  - unilateral** injury → **oblique incision along anterior border of sternocleidomastoid muscle** (for zone II injuries, extend incision from mandible to sternum)
  - if **bilateral** exposure is required → **modified collar incision** (carried up along sternocleidomastoid muscle on both sides).
  - access to major vessels:
    - common carotid, innominate – **median sternotomy**
    - subclavian – **resect middle 1/3 of clavicle** (for left subclavian – may use **anterior thoracotomy through 3rd interspace**)
  - incising through fascial planes can release previously contained hematoma and cause life-threatening hemorrhage!
- injury tract is followed to its depth, systematically examining each structure in or near tract. N.B. goal is to explore structures of neck to identify injuries, not to explore wound per se!
- wounds that approach carotid sheath or midline must be followed to end of wound tract to rule out injury; wounds that do not approach carotid sheath or midline do not need to be fully explored.
- endoscopy** is performed intraoperatively if pharyngeal / esophageal injury is suspected but cannot be found.
- in most cases, **primary repair of nerve injuries** is impractical (in selected cases with clean nerve transection and no significant associated injuries, there may be role for primary repair of injured nerve).
- neck is exceptionally well perfused - clean lacerations may be sutured as late as 12-18 hours after injury.
- prophylactic **antibiotics** for all penetrating wounds (infection is major cause of death and disability!), **tetanus** prophylaxis.

## PROGNOSIS

MORTALITY for civilian penetrating wounds ≈ 2-6%.

- injury to major blood vessel → ≈ 65% fatality (incl. prehospital deaths) by exsanguination\*  
\*if exsanguination is controlled, later complications are pseudoaneurysms, AV fistulas

Worst prognosis:

- blunt vascular** injuries.
- pharyngeal / esophageal** injuries with **delayed diagnosis**

## SPECIAL SITUATIONS

### CAROTID TRAUMA

- major arterial injuries occur in 18% penetrating neck wounds.

**BLUNT INJURY** (accounts for only 3% of all carotid injuries) – intramural hematoma, intimal tear (→ dissection), thrombosis, pseudoaneurysm formation → delayed focal neurologic signs in patient with direct blow or compression of neck. see p. Vas11 >>

**PENETRATING INJURY:**

- no neurologic deficit** or **neurologic deficit short of coma** → **primary vascular repair** (restored vascular continuity).
- comatose** patients, neither repair nor ligation appear to influence poor prognosis.
  - impact of prolonged ischemia and potential revascularization injury (**converting ischemic stroke to hemorrhagic**) is not well defined.
  - carotid ligation is indicated in patient with no prograde flow, in presence of uncontrollable hemorrhage, or when technical reasons prohibit repair.

### VERTEBRALIS TRAUMA

- if bleeding → **angiographic embolization** (virtually impossible to reach surgically in emergency)

### LARYNGOTRACHEAL TRAUMA

- indicators of laryngeal injury:
  - voice quality alterations** (but normal voice does not rule out laryngeal injury).
  - loss of physiologic laryngeal crepitus** (rattling sensation when thyroid cartilage is grasped between thumb and finger and moved side to side).

**PENETRATING WOUNDS** - subcutaneous emphysema (may compress airways extrinsically), crepitus, hemoptysis, air bubbling through wound.

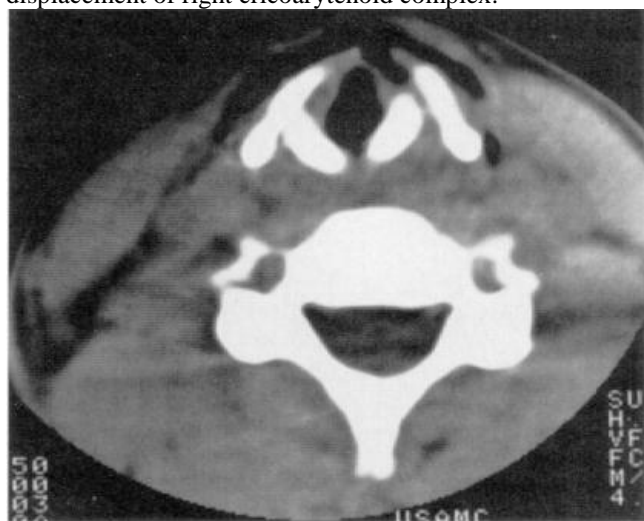
- endotracheal intubation by field paramedics** may mask high tracheal injury!

- **repair principles** - debridement of devitalized cartilage, mucosal coverage of exposed cartilage, and closure of tracheal defects.
  - mucosal is repaired with fine absorbable suture.
  - if defect cannot be primarily closed, tracheal mobilization may bridge gap of several tracheal rings (loss of larger portions → tracheostomy or complex reconstructive procedures).
  - tracheostomy is not always required following repair (but is useful if extensive edema or prolonged airway compression is anticipated).

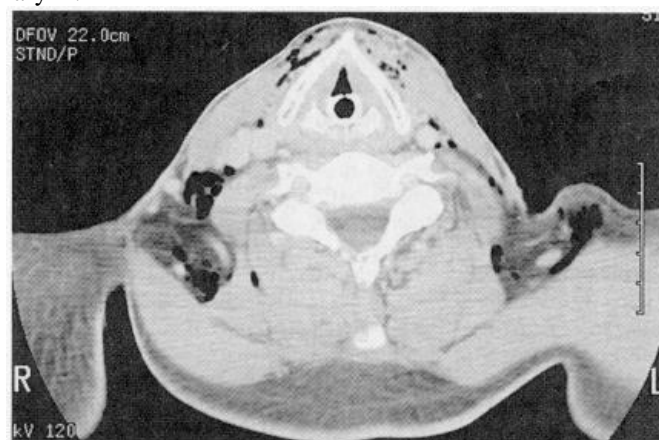**BLUNT INJURIES** (easily overlooked in multiple trauma victim): fracture of thyroid cartilage (lost prominence of thyroid cartilage), recurrent laryngeal nerve injury, vocal cord disruption (voice pitch↓), dislocation of airway cartilages, lacerations of mucosal surface of larynx / trachea.

- initially asymptomatic patient may suddenly develop severe respiratory distress.
- **diagnosis** - **plain radiographs** (supraglottic or subglottic narrowing of air column, prevertebral soft tissue swelling or air, hyoid bone fracture, high-riding hyoid bone\*), **CT**, **direct laryngoscopy**, **bronchoscopy**.
  - \*sometimes seen in complete tracheal transection
- patient should be placed on voice rest, and humidified air.
- **if emergency airway is required:**
  - a) **tracheostomy** - recommended emergency airway following blunt laryngotracheal injuries (incl. tracheal transections)!
  - b) **direct endotracheal intubation** (passing endotracheal tube over flexible endoscope) - may risk worsening tracheal injury!!!
- **repair principles** - reduction of cartilaginous fractures (± **stenting**), primary closure of mucosal lacerations.

CT of blunt neck trauma - subcutaneous emphysema, midline fracture and diastasis of thyroid cartilage, posterolateral displacement of right cricoarytenoid complex:



CT of blunt neck trauma - fracture of thyroid cartilage, significant airway swelling and air in soft tissues surrounding larynx:



## ESOPHAGEAL TRAUMA

- blunt injury is exceedingly uncommon!

### CLINICAL FEATURES

- esophageal injuries are relatively silent until infection has developed!
- odynophagia, hematemesis, spitting up blood, subcutaneous emphysema.
- **MACKLER TRIAD** (classical presentation in Boerhaave syndrome):
  1. Vomiting
  2. Lower chest pain
  3. Subcutaneous emphysema - only seen in half of patients at initial presentation (typically in those patients who present later)
- **HAMMAN SIGN** - crunching, rasping sound, synchronous with heart beat, heard over precordium (sometimes at a distance from the chest) in mediastinal emphysema.

### DIAGNOSIS

- esophagus injuries are *most difficult to diagnose* (sensitivity of **esophagography** 50-90%; sensitivity of **endoscopy** 29-83%).
  - THIN BARIUM is the best choice for esophagography (Gastrografin aspiration → terrible pneumonitis).
- **high morbidity & mortality of missed esophageal injury** demands high index of suspicion (virtually all reported deaths are result of delayed / missed diagnosis).

### TREATMENT

**BLUNT INJURIES** - clinical observation is sufficient in asymptomatic patients

**PENETRATING INJURIES** - repaired **primarily**; principles:

- incisions:
  - a) **neck** – left (anterior to sternocleidomastoideus)
  - b) **upper chest** – right 4<sup>th</sup> intercostal space (posterolateral thoracotomy)
  - c) **lower chest** – left 7<sup>th</sup> intercostal space (posterolateral thoracotomy)
  - d) **abdominal** – laparotomy

N.B. anterior incisions for thoracic esophagus are inadequate; close anterior incision → turn patient → new lateral incision
- **debride**
- **repair in two layers** (using absorbable and nonabsorbable suture); extend incision to see edges of mucosal tear (may be larger than tear of muscular layer).
- **cover with flap** (esophagus has no serosa!): muscle (best choice), pleura, stomach wrap (in abdomen)
- **drain all such wounds** via tube thoracostomy! (drain should be left in place after all esophageal repairs - infection or salivary fistula are not infrequent) – principle of DAMAGE CONTROL
- **feeding** jejunostomy.
- plan **reconstruction**.
- **exceptions:**
  - **massive tissue loss** → **diversion**: cutaneous esophagostomy (for feeding) and cutaneous pharyngostomy (for salivary drainage) → secondary **reconstructive** procedure (after initial healing is complete).

- *injuries diagnosed > 12-48 hours after injury* → initial **diversion** (e.g. esophageal T tube) and **drainage**.

## PHARYNGEAL TRAUMA

- treated with debridement and primary closure whenever practical.
  - posterior aspect cannot be approached through neck - lacerations can be closed from within pharynx, and cervical area drained.
  - patient is kept "nothing by mouth" for 5-7 days.

## STRANGULATION

- **neck compression** by external mechanism:

- hanging** (most common type) – ligature tightens because of weight of victim's body (body does not have to be suspended!); classified:
  - complete** (feet do not touch floor) vs. **incomplete** (all other positions)
  - typical** (point of suspension placed centrally over occiput - greatest likelihood of arterial occlusion) / **atypical** (point of suspension in any other position).
- ligature strangulation**
- manual strangulation**
- postural strangulation** – victim's neck lies over object with weight of body applying pressure to neck; most common in infants and toddlers.

Classified by setting in which it occurs:

- suicidal**
  - hanging is 3<sup>rd</sup> most common form of suicide, after firearms and poisons.
- accidental**
  - accidental strangulation deaths are rare (usually victim's clothing being caught in machinery; also described autoerotic hanging syndrome).
- homicidal**
- judicial**.

## PATHOPHYSIOLOGY

Strangulation creates low pressure on neck

↓  
**Venous obstruction**

↓  
Loss of consciousness (resulting from stagnant hypoxia)

↓  
Flaccidity and loss of muscle tone

↓  
Increased pressure on neck → vagal tone↑ due to carotid sinus pressure → **reflex cardiac arrest**

↓  
**Arterial occlusion** or **airway collapse\***

↓  
Death

\*asphyxiation is not main cause of death (hangings are reported in individuals with tracheostomy sites below level of constricting ligature)

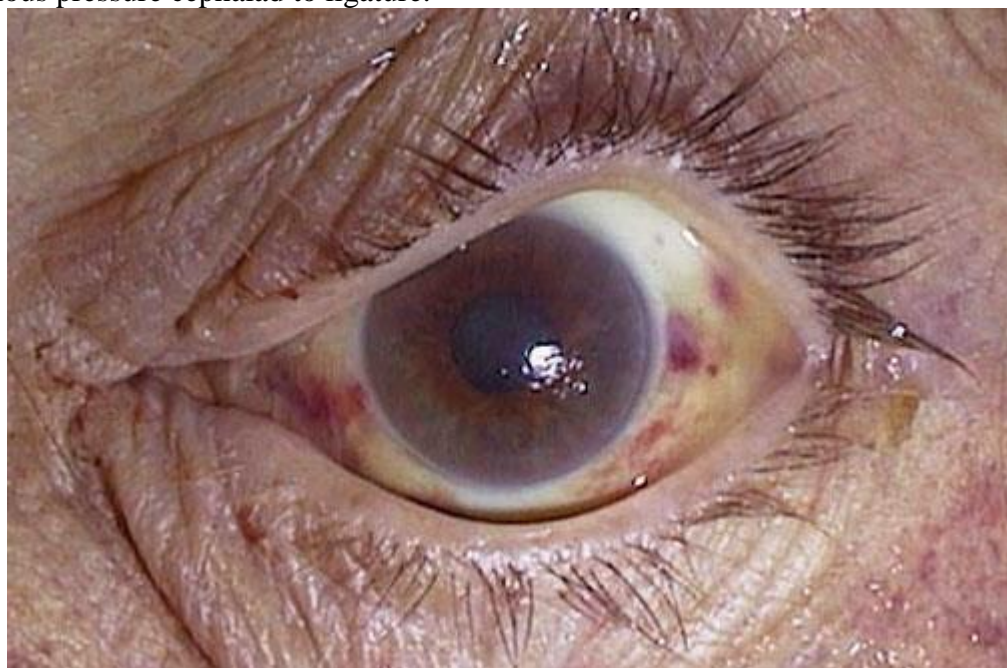
Pathophysiology of **judicial hanging\*** is similar to *DECAPITATION INJURY* - **forceful distraction of head from torso** → fracture of upper cervical spine, transection of upper spinal cord.

\*distance victim is dropped is at least equal to height of victim.

## CLINICAL FEATURES

### Superficial Neck

- 1) **parchment-like compression groove** around neck (duplicates size and pattern of ligature).
- 2) **abrasions** from fingernails (if patient tried to get free before unconsciousness or if manual strangulation was cause of death)
- 3) **TARDIEU'S spots** – subconjunctival and skin **petechial hemorrhages** from increase in venous pressure cephalad to ligature.



### Deep Neck

- only in judicial hangings and manual strangulations: **fractures of larynx, hyoid bone, thyroid cartilage** → palpable crepitus, tenderness, stridor, hoarseness, dysphagia.

### Neurological Deficits

#### Respiratory

- cause delayed mortality:

- 1) **bronchopneumonia**
- 2) **aspiration pneumonitis**
- 3) **delayed airway obstruction**
- 4) **centroneurogenic ARDS** (congestion, edema, hemorrhage, surfactant activation, atelectasis) – via autonomically mediated constriction of pulmonary postcapillary sphincters.

#### Neuropsychiatric

- victim who survives attempted strangulation can display multitude of neuropsychiatric sequelae:

**EARLY PERIOD** - **restlessness** and **violence**.

**LATER PERIOD** - **psychosis, Korsakoff syndrome, amnesia, progressive dementia**.

- memory defects occur as result of selective vulnerability of hippocampus to anoxic damage.

## MANAGEMENT

- all patients should be **observed for at least 24 hours** (for delayed airway obstruction).
- **cervical spine** does not need to be immobilized (unless mechanism is consistent with significant drop, i.e. fall at least equal to height of patient).

- immediate attention to airway - volume-cycled ventilator with PEEP and fluid restriction (for *centroneurogenic ARDS*).
- hyperventilation, **MANNITOL** and **FUROSEMIDE** (for *cerebral edema*).
- life-threatening *cardiac dysrhythmias* must be aggressively treated.
- steroids are not effective!!! (neither for cerebral edema nor *centroneurogenic ARDS*).
- potentially useful drugs:
  - 1) **PHENYTOIN** - preventing ischemic cerebral damage, arresting *centroneurogenic ARDS*.
  - 2) **NALOXONE** - reversing cerebrovascular ischemia in animal models by increasing cerebral perfusion to ischemic areas.
  - 3) calcium channel blockers.

### PROGNOSIS

- dismal prognosis:
  - 1) patients who present in cardiac arrest
  - 2) complete lack of neurological function after successful resuscitation.

BIBLIOGRAPHY for ch. "Spinal Trauma" → follow this [LINK >>](#)