VERTEBRAL COLUMN

33 slanksteliai

INTERVERTEBRAL DISKS – not pain-sensitive!

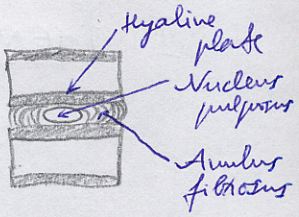

1) fibrocartilage
2) amphiarthrosis (symphysis) – mažai paslankus
3) absent – C_{1-2}, S, Cx
4) 25% stuburo ilgio (plonesni kaklo, storesni juosmenyje)

Annulus fibrosus – stipriosios skaidulos įvairiomis kryptimis (dense fibrous connective tissue)

Nucleus pulposus:
1) embryonic notochorda liekana
2) daug mukopolisacharidų – aukštas osmosas – 70-80% vandens – 1 cm aukštesnis nyte
3) „noncompressible but deformable pad" – peskinsto jėgą vienodai visam slankstelio kūnui
4) su amžiumi mažėja vandens (disk degeneration) – ūgis ↓; susidaro kompensaciniai osteofitai – dirgina n. spinalis bei mažėjusios audinius
5) plyšus annulus fibrosus, nucleus pulposus išsiveržia (disk herniation):
   a) dažn. L_{4-5} ir L_5-S_1 – max krūvis (5-10% kaklo)
   b) posterolateraliai (nėra išilginių raiščių)
   c) retai į slankstelio kūnų (SCHMORL'S node)
   d) sukelia n. spinalis kompresiją → referred pain in dermatome; → myotome muscles ↓
   e) dėl lokalaus skausmo (plyšęs annulus fibrosus) – spasm of back muscles

Juosmenyje vienoniis nervas išeina per angą po viršumi žiūr slankstelio. Todėl angi pedicle turi apačioje daug vietos tai nervas išeina aukščiau diskos. Hernia užspaudžia nervą viena vienoms žemiau (pvz.: L_{4-5} užspaudžia L_5). Ret dažniau hernios gali užspausti kelis nervus!

Kaklo vienoniis nervas išeina per angą virš vienoniojo slankstelio – todėl C_{4-5} užspaus C_5

NORMAL SPINAL CURVATURES

pagrinde dėl DISKŲ formos!!!

1. Sacral – primary (terrestrial adaptation)
2. Lumbar – secondary (adaptation to upright posture)
   ↑ nestabiliausia vieta
3. Thoracic – primary (terrestrial)
4. Cervical – secondary (adaptation to quadrupedal posture)

ABNORMAL CURVATURES

1. KYPHOSIS (HUNCHBACK) – pakylėjusi thoracic curvature
2. LORDOSIS (SWAYBACK) – pakylėjusi lumbar curvature (dėl svorio centro pasidarymo į priekį – vėstumas, nutukimas)
3. SCOLIOSIS:
   a) dažn. idiopathic
   b) compensatory curvature kitose vietose
   c) progresuojanti rotacija (krukdo kvėpavimą) toward convex side
   d) chirurgija iki 30 m. (iki vėstumo)

VERTEBRAL COLUMN

Vertebral (neural) arch = pedicles + laminae

Pedicle fracture atjungia slankstelių kūnus nuo stabilizuojančio „articular column" (zygo-apophyses)

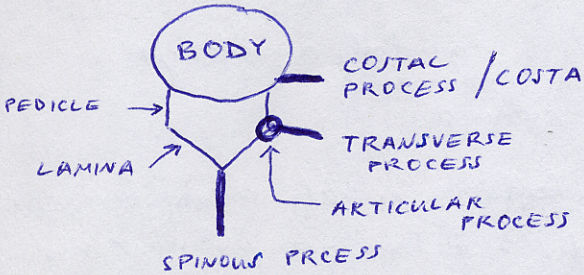

susiliejęs < kaklė → TRANSVERSE FORAMEN
sacrum → ALA (WING OF SACRUM)

Slankstelio kūnas iš $C_1 \to C_2$ (tapo DENS)
C_1 trip pat neturi spinous process

ARTICULAR PROCESS (= ZYGAPOPHYSIS) turi savo FACET:
III° freedom { 1. Superior – žiūri atgal (kaklas), medialyn (lumbar), atgal ir lateralyn (krūtinė)
2. Inferior

Vertebral (neural) canal = n × vertebral foramen (siauriausias torakalinėje dalyje)

Intervertebral foramen (n. spinalis, a. intervertebralis)

C — Transverse foramen – kaklo slankstelinės (a. vertebralis) (kyšinojasi su n. spinalis (ventralian jo!))
absent in C_7
C_6 turi didelį tuberculum anterius processus transversi – tuberculum caroticum

Atlantookcipitalinis sąnarys – pagrindinė kaklo flekcija/ekstenzija po 15° (nes atlas neturi kūno!)

Atlantoaksialinis sąnarys (supported only by lig. cruciforme) – rotation (pusė visos kaklo rotacijos!)

Kaklo lateralinė fleksija – tarp C_2 ir C_7

Kaklo slankstelių iš priekio

tik kaklė → LUSCHKA'S joint

Th — slankstelių kūnai ir processus transversus jungiasi su COSTA



- Th sąnarėlių paviršius sutampa su vertebral arch – Th slankstelių pasižymi didele rotacija. Kitus judesius riboja šonkaulių susijungę su sternum (gelbėti tik kremzliniai šonkaulių galai ir synovialinės sternohostalinės jungtys)
- Th processus spinosi sunkiai palpuojasi!: Th_{1-6} ilgi, bet eina įstrižai žemyn, Th_{7-12} horizontalūs, bet trumpi

L
- processus spinosus horizontalūs:
  1) L slankstelių pasižymi didele flekcija/ekstenzija
  2) galima lumbalinė punkcija
- sąnarėlių paviršius panasagitalus – riboja rotaciją!

Mamillary process (aut viršutinės processus articularis) – m. multifidus

Accessory process (aut processus transversus) – m. longissimus

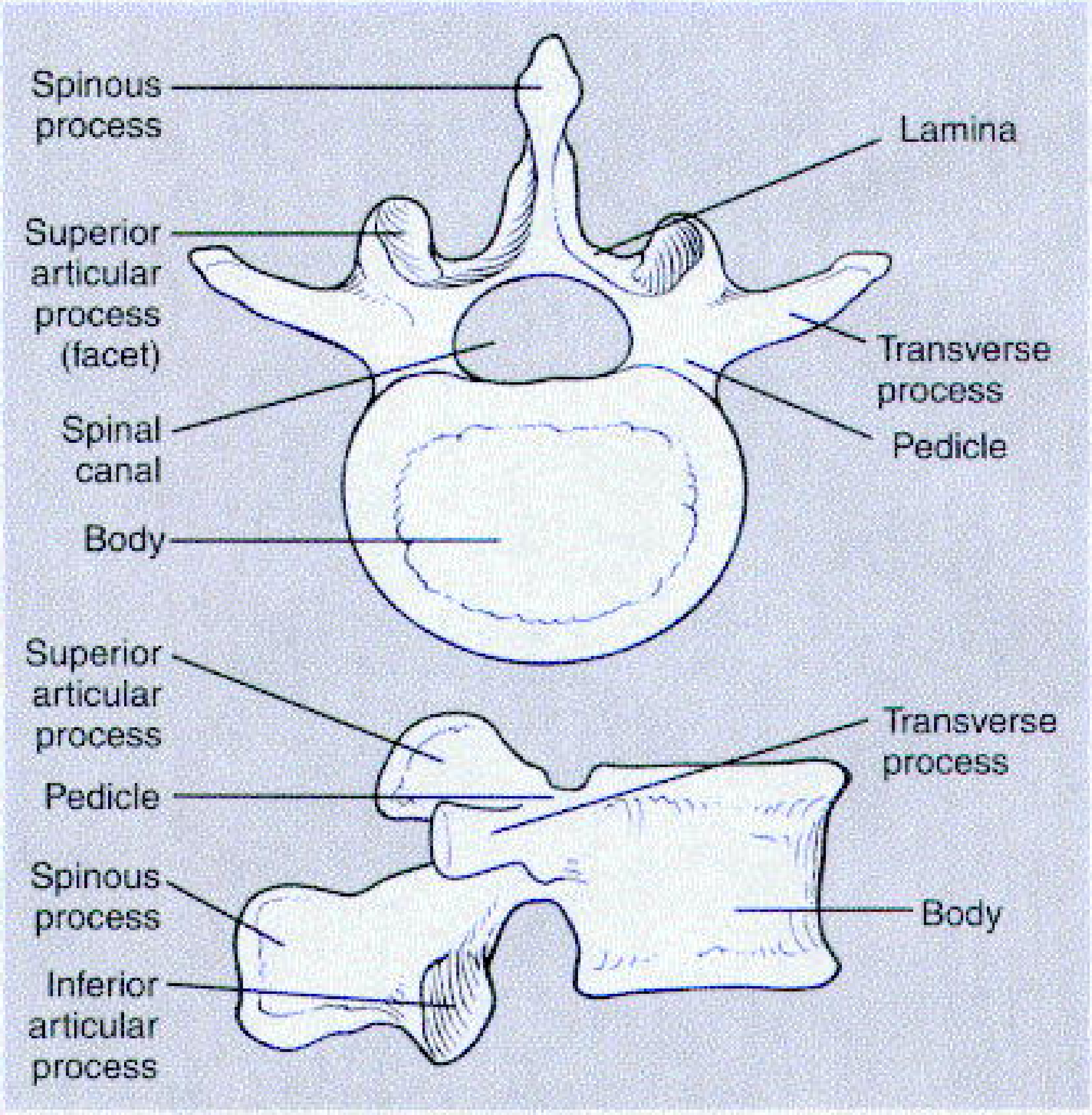
Spinous process
Lamina
Superior articular process (facet)
Transverse process
Spinal canal
Pedicle
Body
Superior articular process
Transverse process
Pedicle
Spinous process
Body
Inferior articular process

NEURO-CENTRAL SYNOVIAL CAVITY (LUSCHKA)

ANTERIOR TUBERCLE

ANT. LONG. LIG.

DISC

VERTEBRAL ARTERY

TRANSVERSE-PROCESS

ARTERIAL FORAMEN

NERVE ROOT

POSTERIOR TUBERCLE

POST. LONG. LIG.

NEURAL GROOVE

LAMINA

SPINOUS PROCESS

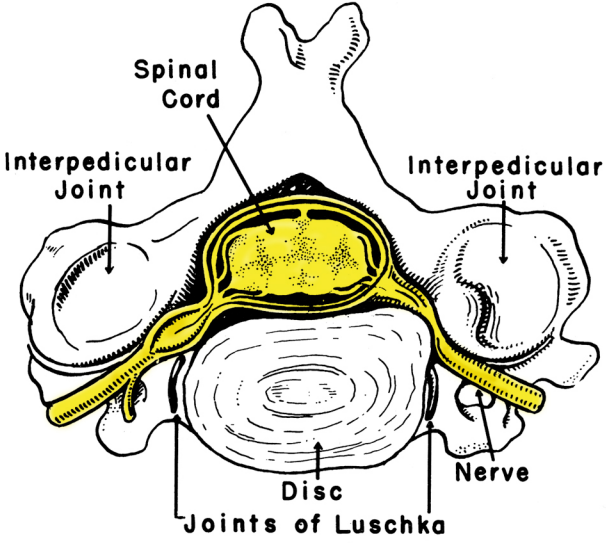

Mechanism of cervical nerve root compression by osteophytes extending into the intervertebral foramen.

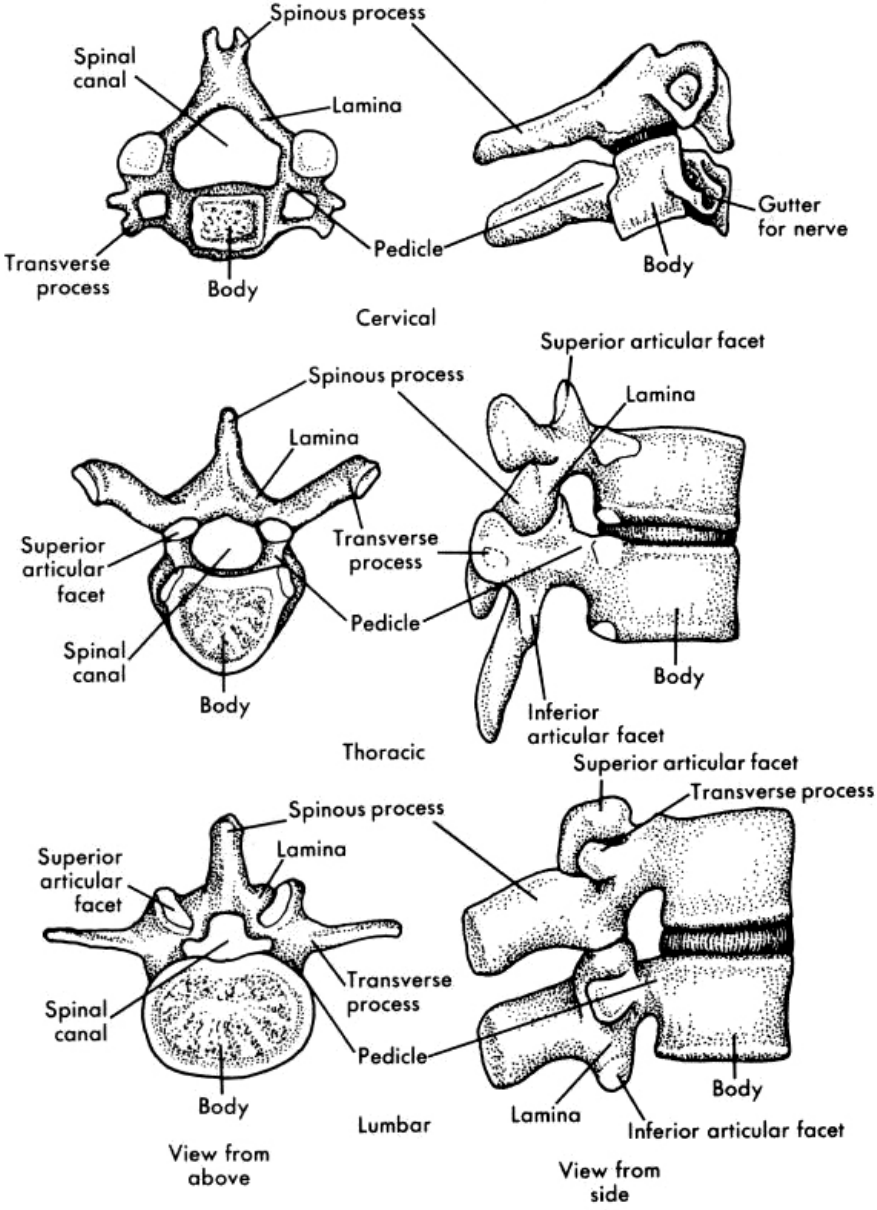
Spinous process
Spinal canal
Lamina
Transverse process
Pedicle
Body
Gutter for nerve
Body
Cervical
Superior articular facet
Spinous process
Lamina
Lamina
Superior articular facet
Transverse process
Pedicle
Spinal canal
Body
Body
Inferior articular facet
Thoracic
Superior articular facet
Transverse process
Spinous process
Lamina
Superior articular facet
Transverse process
Spinal canal
Pedicle
Body
Body
Lamina
Inferior articular facet
Lumbar
View from above
View from side

Atlas

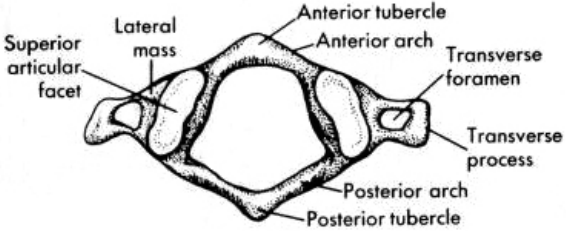

Axis

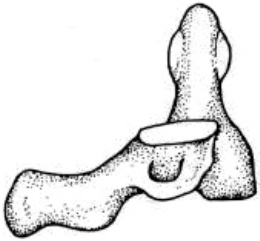

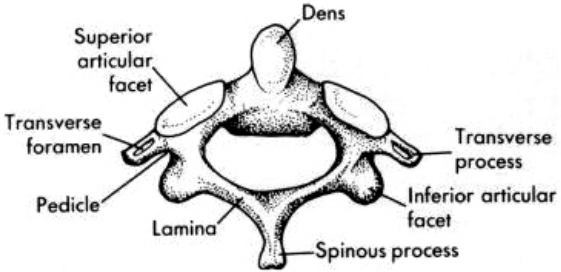

1014f

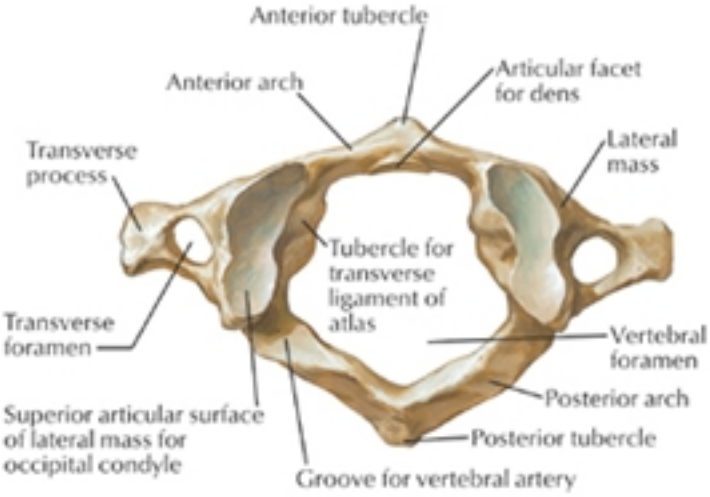

Atlas (C1): superior view

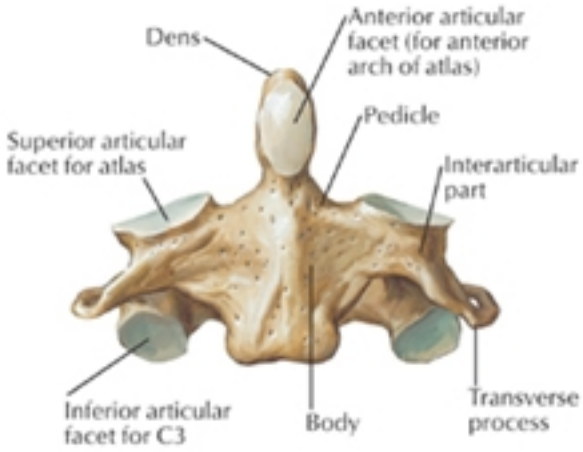

Axis (C2): anterior view

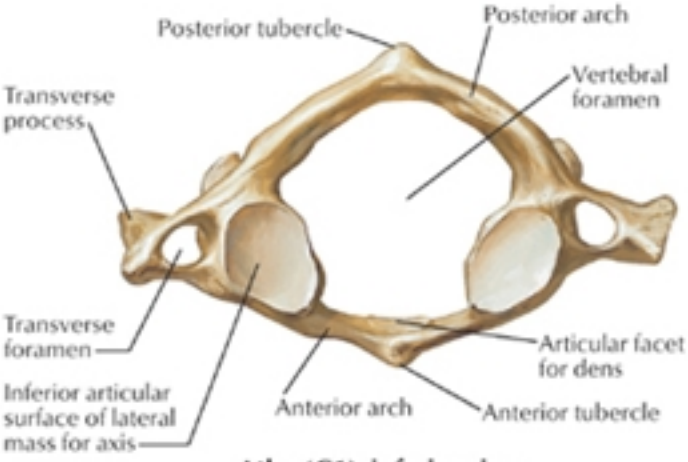

Atlas (C1): inferior view

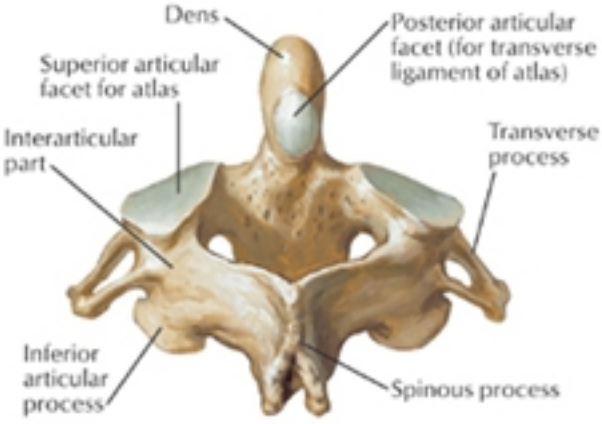

Axis (C2): posterosuperior view

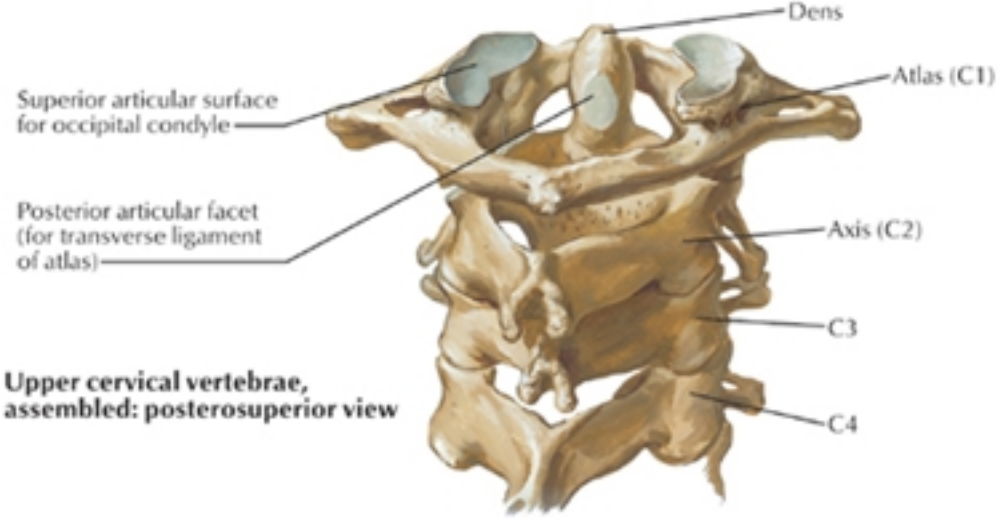

Upper cervical vertebrae, assembled: posterosuperior view

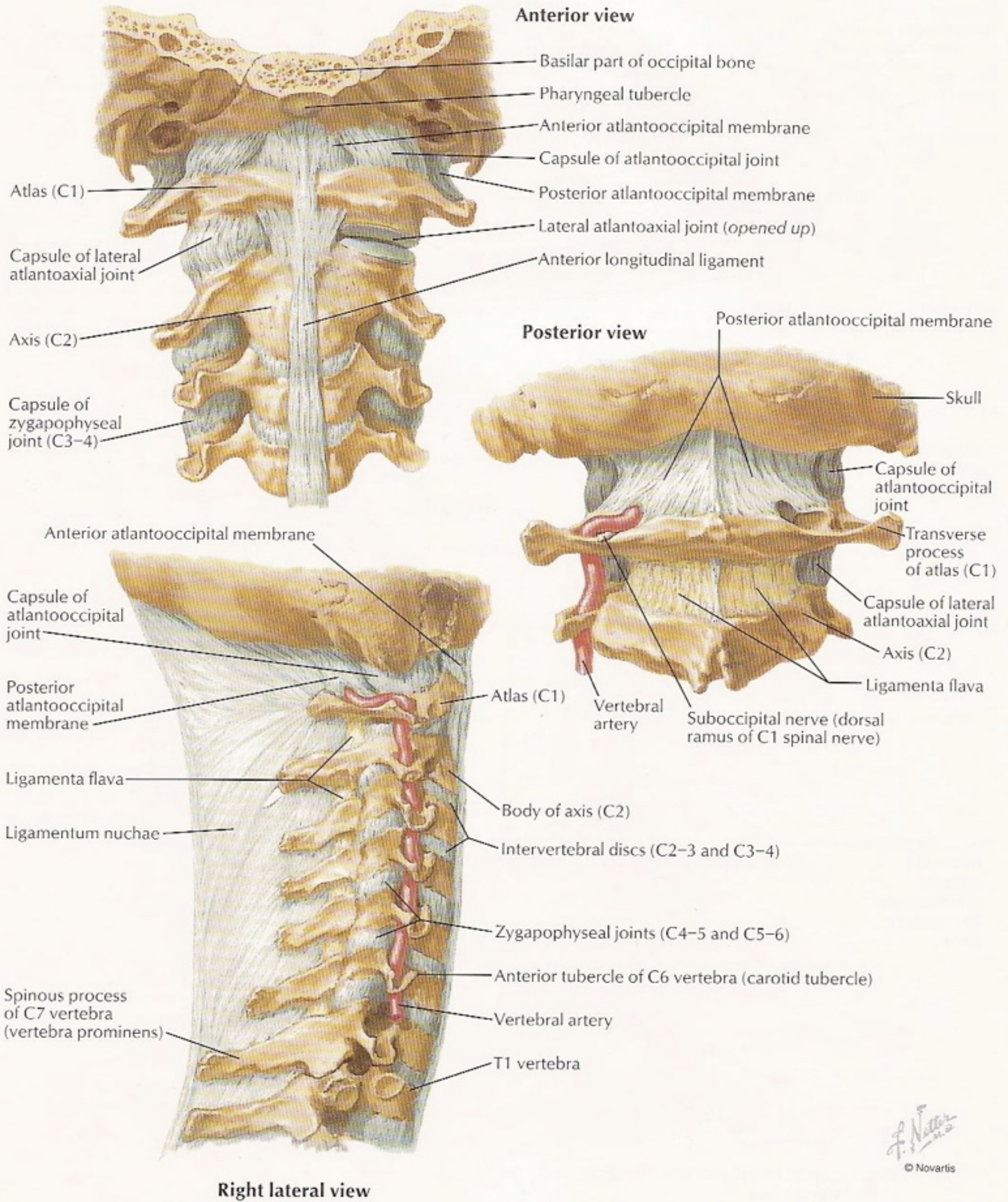
Anterior view
Basilar part of occipital bone
Pharyngeal tubercle
Anterior atlantooccipital membrane
Capsule of atlantooccipital joint
Posterior atlantooccipital membrane
Lateral atlantoaxial joint (opened up)
Anterior longitudinal ligament
Atlas (C1)
Capsule of lateral atlantoaxial joint
Axis (C2)
Capsule of zygapophyseal joint (C3–4)
Posterior view
Posterior atlantooccipital membrane
Skull
Capsule of atlantooccipital joint
Transverse process of atlas (C1)
Capsule of lateral atlantoaxial joint
Axis (C2)
Ligamenta flava
Vertebral artery
Suboccipital nerve (dorsal ramus of C1 spinal nerve)
Anterior atlantooccipital membrane
Capsule of atlantooccipital joint
Posterior atlantooccipital membrane
Atlas (C1)
Ligamenta flava
Ligamentum nuchae
Body of axis (C2)
Intervertebral discs (C2–3 and C3–4)
Zygapophyseal joints (C4–5 and C5–6)
Anterior tubercle of C6 vertebra (carotid tubercle)
Vertebral artery
Spinous process of C7 vertebra (vertebra prominens)
T1 vertebra
Right lateral view
© Novartis

Clivus (surface feature) of basilar part of occipital bone

Upper part of vertebral canal with spinous processes and parts of vertebral arches removed to expose ligaments on posterior vertebral bodies: posterior view

Tectorial membrane

Capsule of atlantooccipital joint

Deeper (accessory) part of tectorial membrane

Atlas (C1)

Posterior longitudinal ligament

Capsule of lateral atlantoaxial joint

Axis (C2)

Capsule of zygapophyseal joint (C2–3)

Alar ligaments

Atlas (C1)

Cruciate ligament

Superior longitudinal band

Transverse ligament of atlas

Inferior longitudinal band

Axis (C2)

Deeper (accessory) part of tectorial membrane

Principal part of tectorial membrane removed to expose deeper ligaments: posterior view

Apical ligament of dens

Alar ligament

Atlas (C1)

Posterior articular facet of dens (for transverse ligament of atlas)

Axis (C2)

Anterior tubercle of atlas

Alar ligament

Synovial cavities

Dens

Transverse ligament of atlas

Cruciate ligament removed to show deepest ligaments: posterior view

Median atlantoaxial joint: superior view

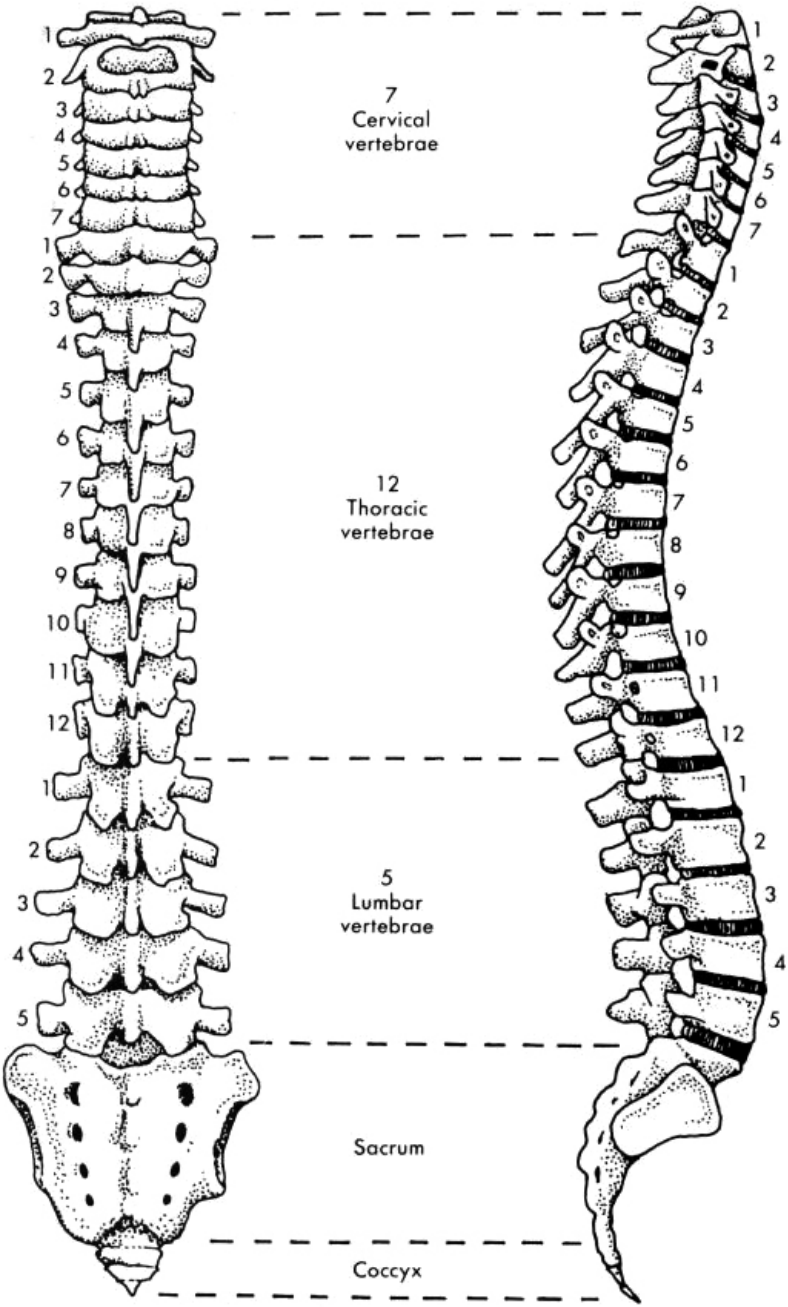
7
Cervical
vertebrae
12
Thoracic
vertebrae
5
Lumbar
vertebrae
Sacrum
Coccyx

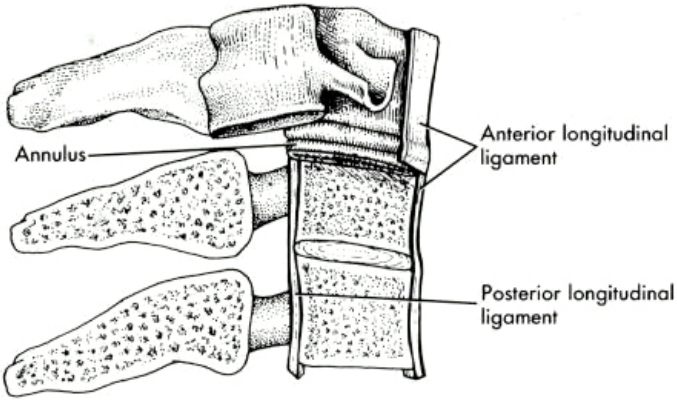
Annulus
Anterior longitudinal ligament
Posterior longitudinal ligament

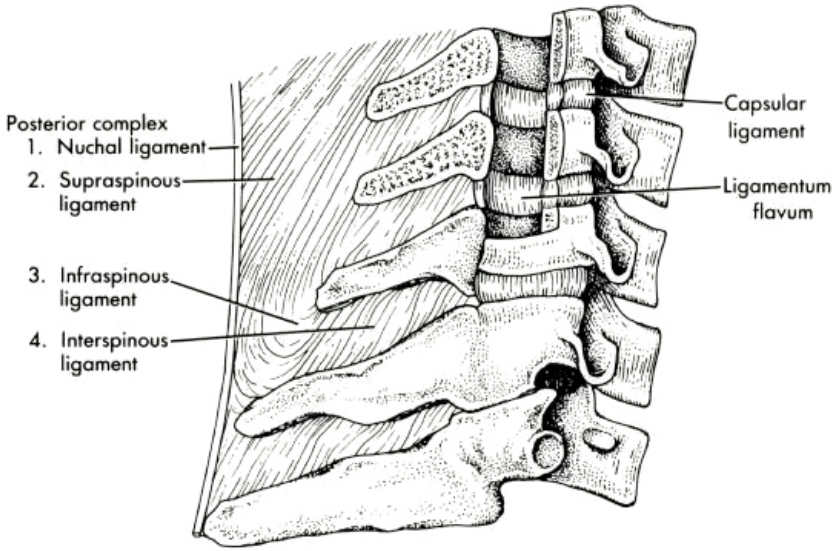
Posterior complex
1. Nuchal ligament
2. Supraspinous ligament
3. Infraspinous ligament
4. Interspinous ligament
Capsular ligament
Ligamentum flavum

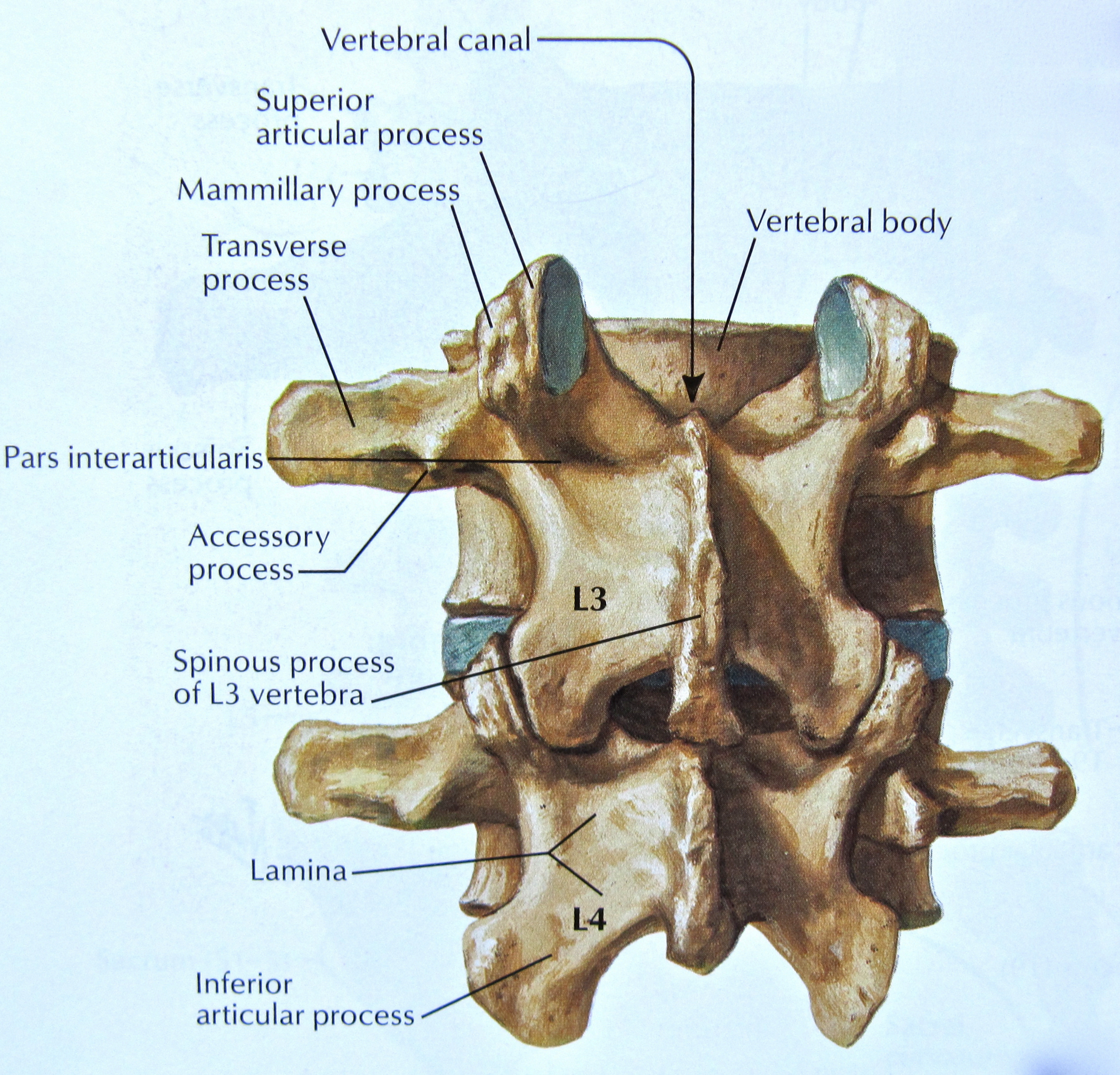
Vertebral canal
Superior articular process
Mammillary process
Transverse process
Vertebral body
Pars interarticularis
Accessory process
L3
Spinous process of L3 vertebra
Lamina
L4
Inferior articular process

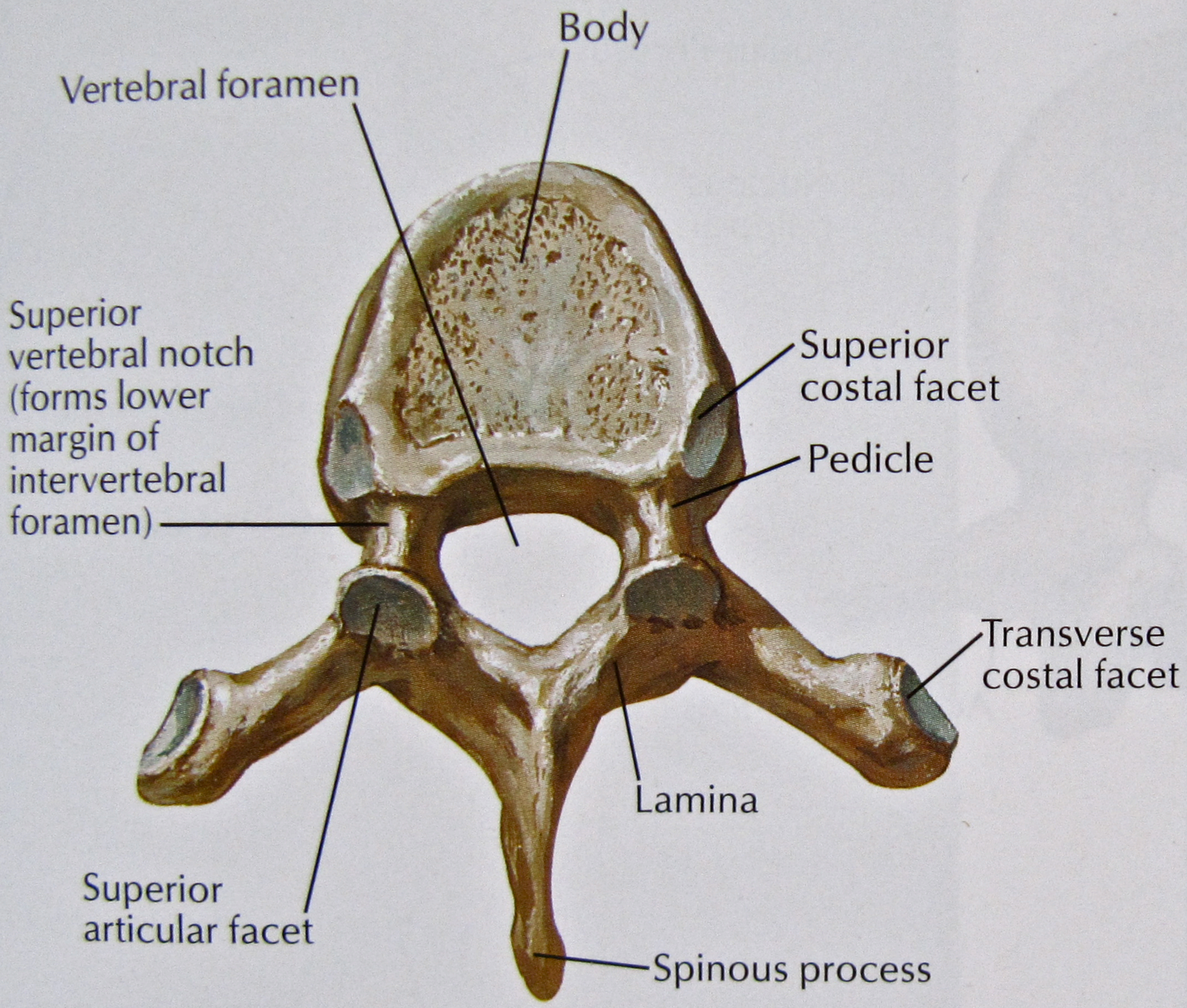

T6 vertebra: superior view

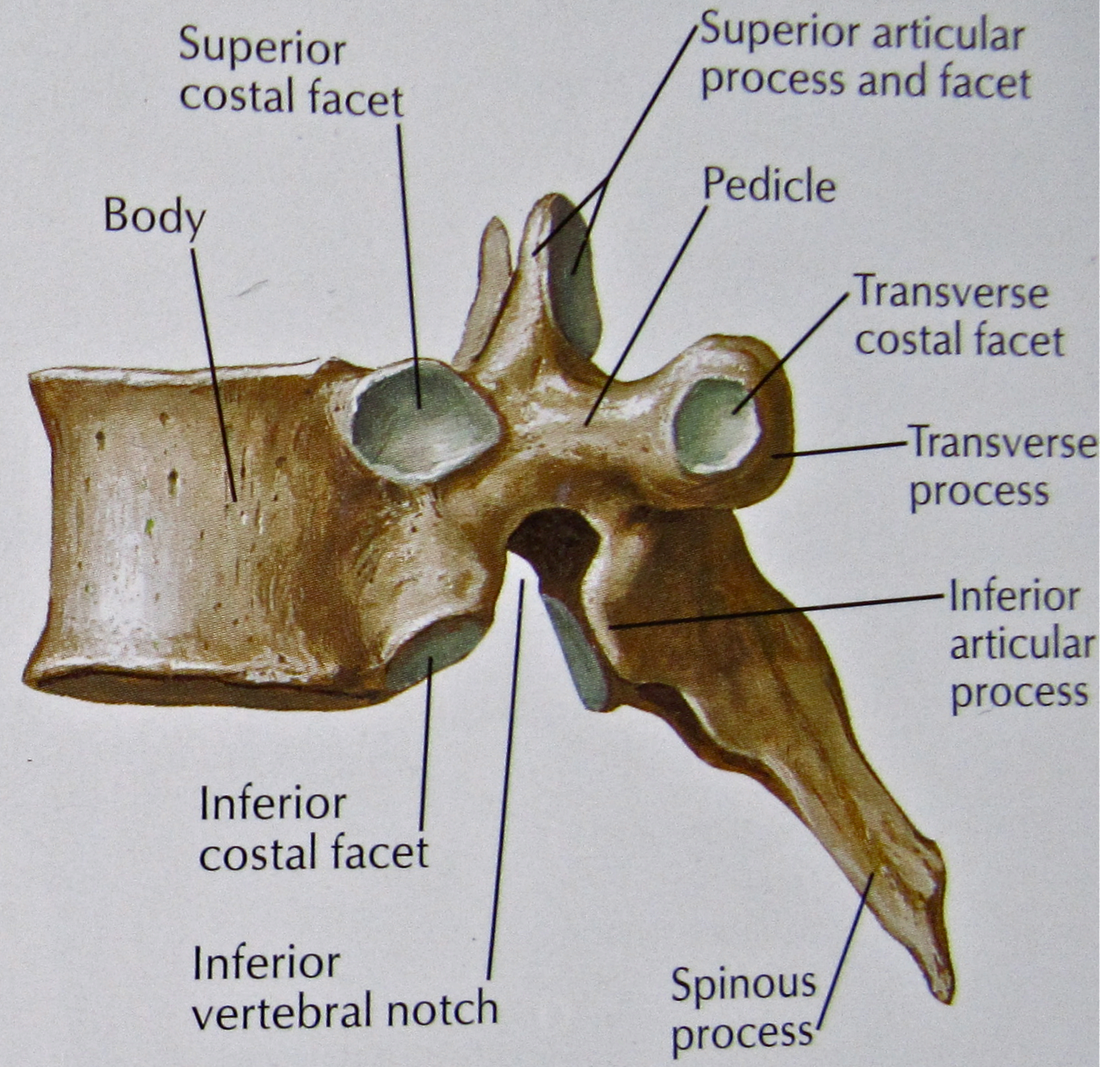

T6 vertebra: lateral view

S

- Foramen sacrale: anterius – ventral primary ramus of n. spinalis
  posterius – dorsal " " " "

- S_5 neturi laminae (hiatus sacralis) – caudal anestezija
  S_5 pedicles čiuopiamos kaip sacral cornua (ORIENTYRAS)

- S_1 articular facet nukreiptas atgal – neleidžia įvykti SPONDILOLISTEZEI (jam dar padeda lig. longitudinale ant.) – o tam yra polinkis, nes:

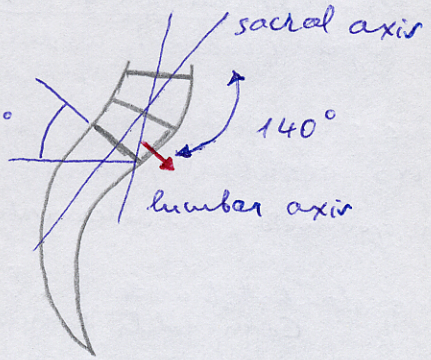

Dėl įgimtų/įgytų L_5 ar S_1 lankų defektų įvyksta spondilolisteze → (S_1, S_2 n. spinalis kompresija → SCIATICA)

- Art. sacroiliaca – stipriausias sinovinis sąnarys kūne

Cx

Cx_1 pedicles sudaro coccygeal cornua

$Cx_{2-4(5)}$ tai tik išlikę slankstelių kūnai
♂ coccyx palinkęs į priekį
♀ coccyx vertikalus

S_5 – Cx_1 sąnarys turi diskų, kurie su amžiumi sukaulėja
↑
kūdikis ar artrifas → COCCYGODYNIA

- "Whiplash" injury (hyperextension trauma) – plyšta lig. supra-/interspinata; lig. flavum (sudarytas tik iš elastinių skaidulų) įlinkęsta į vidų (traumuoja nugaros sm.)

- Dažnus slankstelio kūnui, nugarai nestabilioma ekstenzija (tada lig. longitudinale ant. veikia kaip įtvaras)
  tvirtinasi prie slankst. kūnų, bet ne prie diskų

- Lig. longitudinale post. platesnis tiek slankstelio kūnu, siauresnis tiek diskas

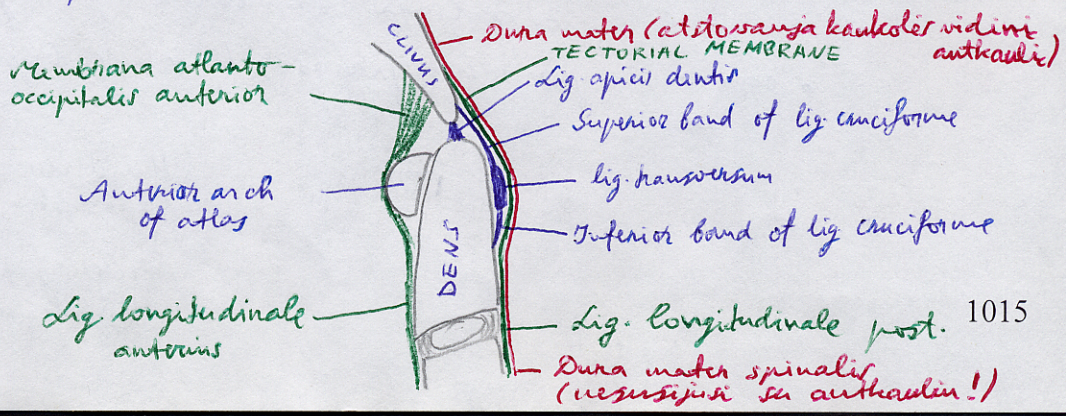

Nuo dens į šonus ir į viršų (prie foramen magnum šonų) eina ALAR ligaments

Neutral primary rami of n. spinalis inervuoja paviršinius nugaros raumenis!

POSTERIOR VERTEBRAL MUSCLES – dorsal primary rami of n. spinalis

I. SUPERFICIAL layer (spinotransverse group)

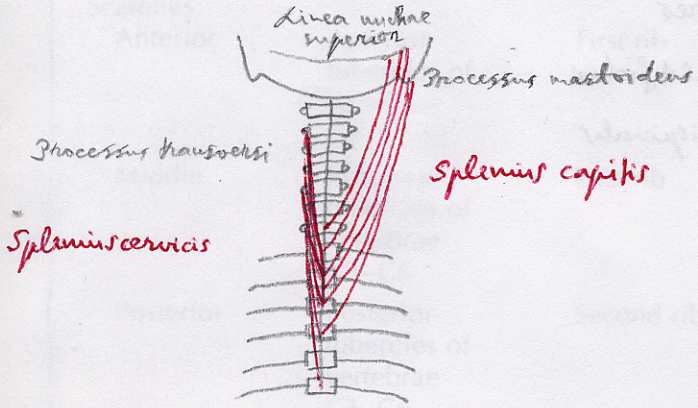

Pati paviršiniai sluoksniai

sudaro:

m. serratus post. sup (esti po mm. rhomboidei)

mm. intercostales!

m. serratus post. inf (po m. latissimus dorsi)

II MIDDLE layer (sacrospinalis group – erector spinae)

1) medialinė porcija – M. SPINALIS

2) vidurinė porcija –

– M. LONGISSIMUS

- prasideda nuo processus transversi
- baigiasi ant processus transversi ir šonkaulių

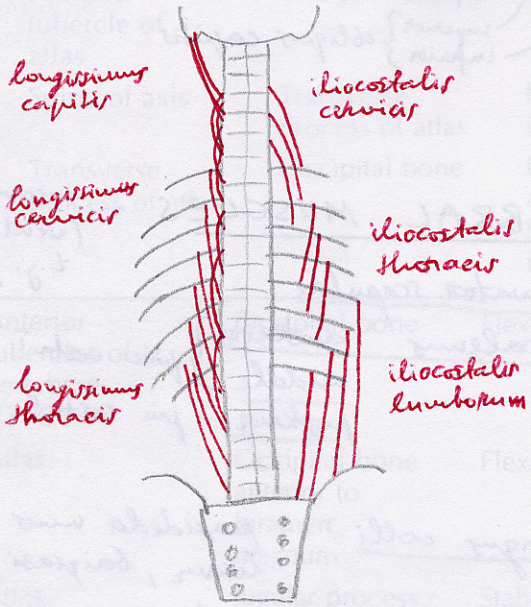

3) lateralinė porcija –

– M. ILIOCOSTALIS

YOKOCHI – 201

III INNERMOST layer (transversospinalis group)

Kuo giliesnis raumuo – tuo mažiau slankstelių peršoka!



gilyn

1) M. SEMISPINALIS – peršoka ≥ 5 slankstelius
2) MM. MULTIFIDI – peršoka 2–3 slankstelius (ypač rytinės kaklo ir juosmenyje)
3) MM. ROTATORES LONGI – peršoka 1 slankstelį
4) MM. ROTATORES BREVES – tvirtinasi ant ankščiau esančio slankstelio
5) MM. INTERSPINALES
6) MM. INTERTRASVERSARII

} segmentiniai – – tarp gretimų slankstelių

Speciali grupė – suboccipital muscles

YOKOCHI – 203

TABLE 12-1. Posterior Vertebral Musculature-Posterior Group

Muscle	Origin	Insertion	Primary Action	Innervation
Spinotransverse group				
Splenicus capitis	Upper thoracic vertebrae and ligamentum nuchae	Mastoid process	Extend head	Dorsal primary rami of cervical plexus
Splenius cervicis	Spines of vertebrae C3–C6	Transverse process of vertebrae C1–C4	Extend neck	Dorsal primary rami of cervical plexus
Sacrospinalis (erector spinae) group				
Iliocostalis lumborum	Sacrum and iliac crest	Lower six ribs	Extend and laterally flex vertebral column	Dorsal primary rami of spinal nerves
Iliocostalis thoracis	Ribs T7–T12	Ribs T1–T6	Extend and laterally flex vertebral column	Dorsal primary rami of spinal nerves
Iliocostalis cervicis	Ribs T1–T6	Transverse processes of C4–C6	Extend and laterally flex neck	Dorsal primary rami of spinal nerves
Longissimus capitis	Transverse processes of vertebrae C2–C5	Mastoid process	Extend and rotate head to ipsilateral side	Dorsal primary rami of cervical plexus
Longissimus cervicis	Transverse processes of vertebrae C7–T5	Transverse processes or vertebrae C2–C6	Extend and laterally flex vertebral column	Dorsal primary rami of cervical plexus
Longissimus thoracis	Transverse processes of vertebra T6–L5	Ribs and transverse processes of vertebra T12–T1	Extend and laterally flex vertebral column	Dorsal primary rami of spinal nn. T1–L5
Spinalis thoracis	Spinous processes	Spinous processes	Extend vertebreal column	Dorsal primary rami
Spinalis cervicis	Spinous processes	Spinous processes	Extend vertebreal column	Dorsal primary rami
Spinalis capitis	Spinous processes	Spinous processes	Extend vertebreal column	Dorsal primary rami
Transverseospinalis group				
Semispinalis capitis	Transverse processes of vertebrae T1–T6	Occipital bone	Extend head and rotate head to opposite side	Dorsal primary rami of cervical plexus
Semispinalis cervicis	Transverse processes of vertebrae T1–T7	Spinous processes of vertebrae C1–C5	Extend vertebral column and rotate to opposite side	Dorsal primary rami of cervical plexus

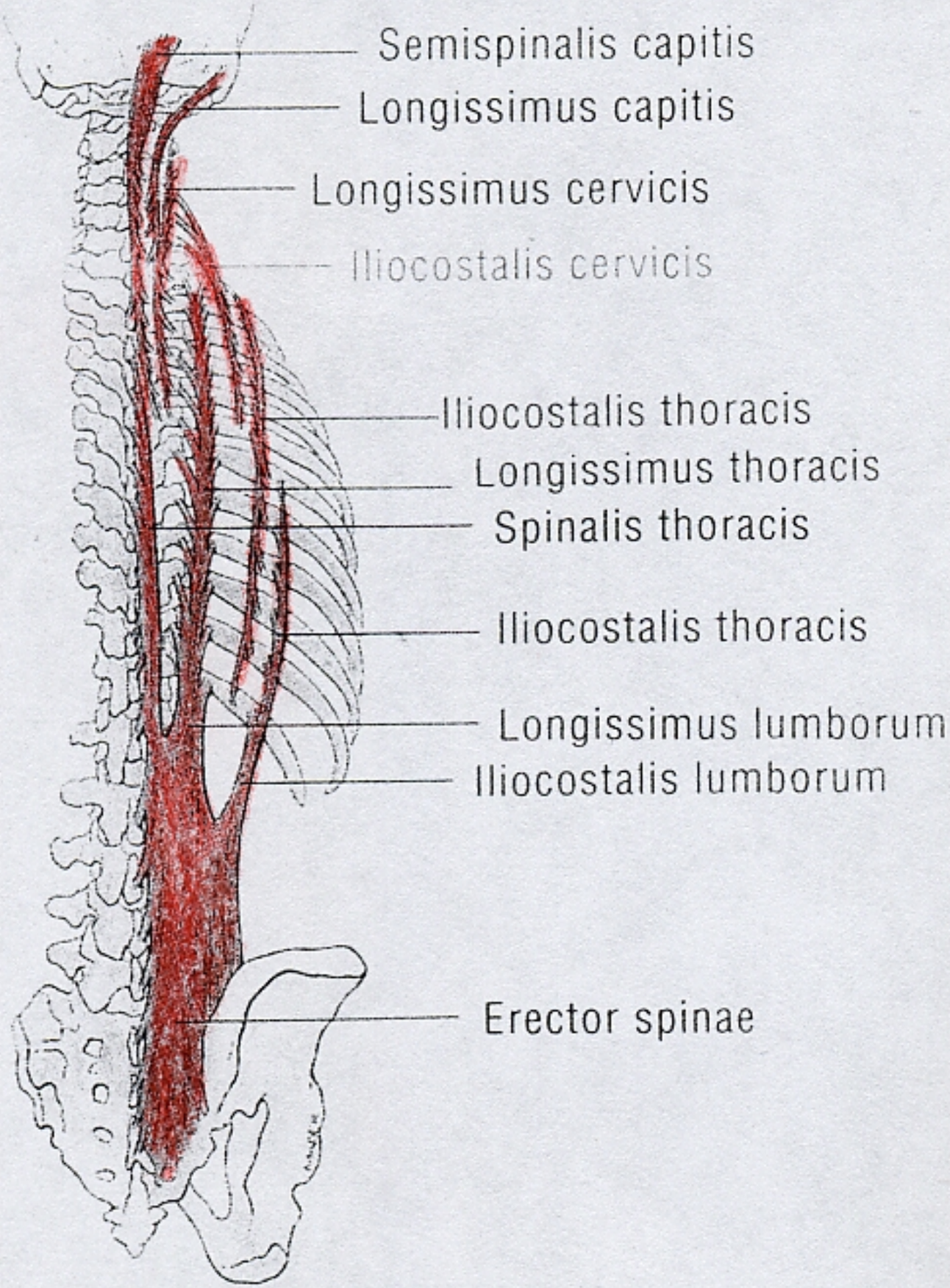

4.50

Erector spinae and semispinalis

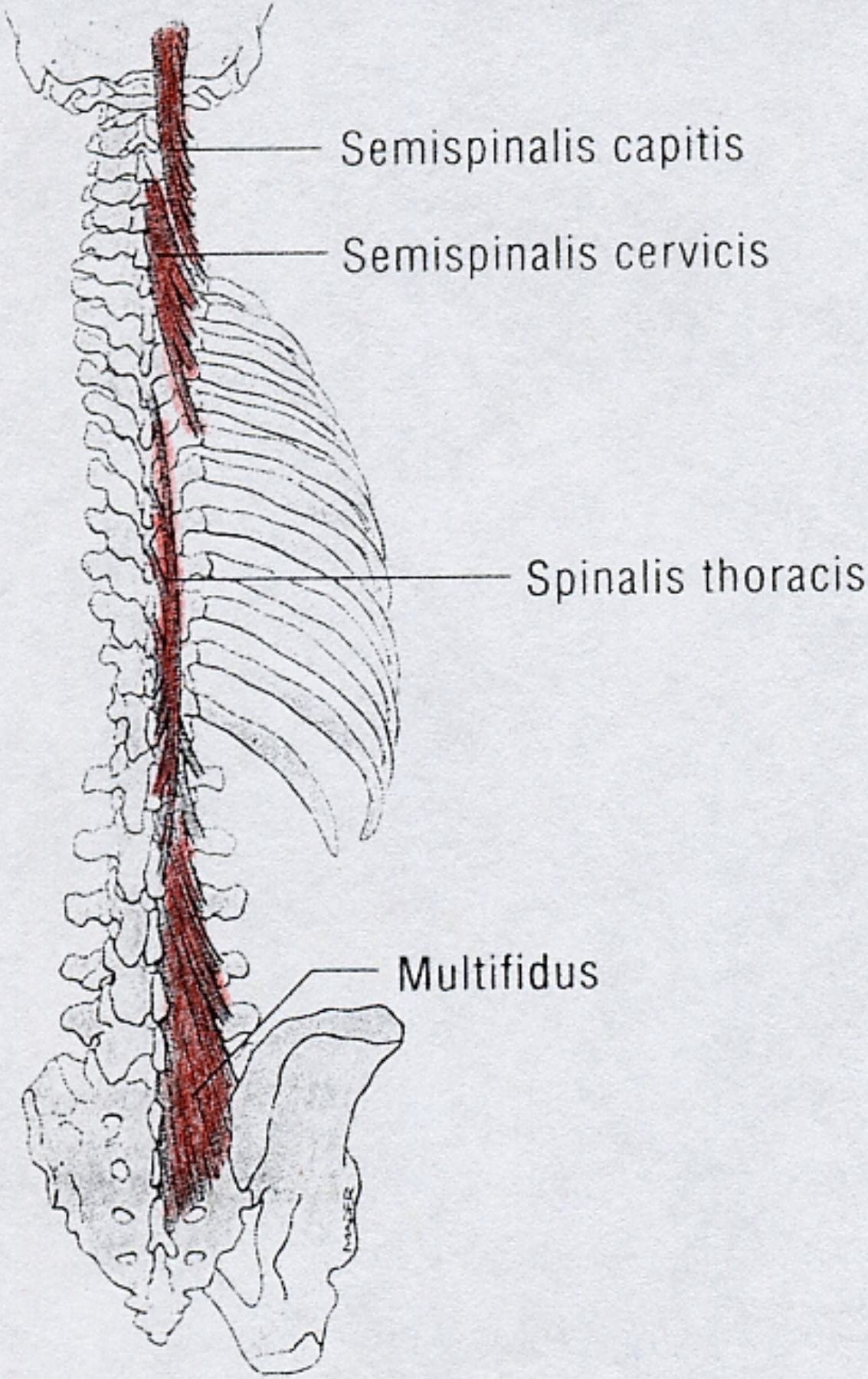

4.52

Semispinalis, multifidus, and spinalis

VERTEBRAL COLUMN – muscles

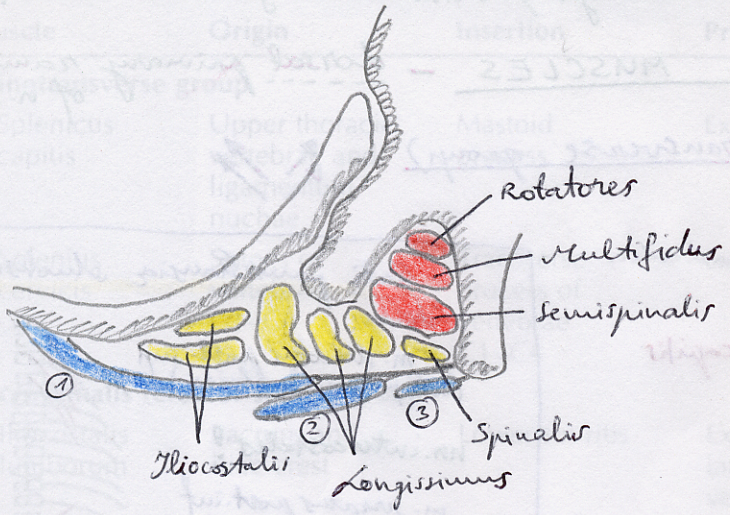

① Serratus posterior
② Latissimus dorsi
③ Trapezius

III^a SUBOCCIPITAL MUSCLES – dorsal ramus of n. spinalis C_1



YOKOCHI – 215

ANTERIOR VERTEBRAL MUSCLES – inervuoja C priekinės (ventral/anterior) šakos t.y. plexus cervicalis

I. Lateral group:

1. Levator scapulae
2. Scalenus anterior, middle } prie costa I; posterior – prie costa II

pagalbiniai kvėpavimo raumenys, nes keliai I–II šonkaulius

II. Anterior group:

1. Longus colli – prasideda nuo C_5–Th_3 slankstelių kūnų, baigiasi ant C_{1-4} kūnų
2. Longus capitis – prasideda nuo processus transversi C_{3-6}, baigiasi ant pars basilaris ossis occipitalis
3. Rectus capitis anterior – baigiasi ant pars basilaris ossis occipitalis (prasideda nuo processus transversi atlantis)
4. Rectus capitis lateralis – baigiasi ant pars lateralis ossis occipitalis (processus jugularis)
5. Quadratus lumborum: iliac crest → XII costa

TABLE 12-2. Intrinsic Cervical Musculature—Suboccipital Group

Muscle	Origin	Insertion	Primary Action	Innervation
Rectus capitis post. maj.	Spine of axis	Occipital bone	Extend head	Spinal n. C1 (posterior)
Rectus capitis post. min.	Posterior tubercle of atlas	Occipital bone	Extend head	Spinal n. C1 (posterior)
Obliquus capitis inf.	Spine of axis	Transverse process of atlas	Rotate head to ipsilateral side	Spinal n. C1 (posterior)
Obliquus capitis sup.	Transverse process of atlas	Occipital bone	Extend head and rotate head to ipsilateral side	Spinal n. C1 (posterior) ↑ n. suboccipitalis

Muscle	Origin	Insertion	Primary Action	Innervation
		Lateral group		
Scalenes:				
Anterior	Anterior tubercles of vertebrae C3–C6	First rib	Elevates first rib	Spinal nn. C4–C6 (anterior)
Middle	Posterior tubercles of vertebrae C3–C6	First rib	Elevates first rib	Spinal nn. C3–C8 (anterior)
Posterior	Posterior tubercles of vertebrae C3–C6	Second rib	Elevates second rib	Spinal nn. C3–C8 (anterior)
Levator scapulae	Posterior tubercles of vertebrae C2–C5	Superior angle of scapula	Elevates scapula	Spinal nn. C3–C4 (anterior)
		Anterior group		
Longus cervicis (colli)				
Sup. oblique head	Anterior tubercles of vertebrae C3–C6	Anterior tubercle of atlas		
Vertical head	Upper thoracic vertebrae	Bodies cervical vertebrae C2–C4	Flexes neck	Spinal nn. C2–C7 (anterior)
Inf. oblique head	Upper thoracic vertebrae	Transverse processes of C4–C5		
Longus capitis	Anterior tubercles of vertebrae C3–C6	Occipital bone	Flexes head	Spinal nn. C1–C3 (anterior)
Rectus capitis anterior	Atlas	Occipital bone anterior to foramen magnum	Flexes head	Spinal nn. C1–C2 (anterior)
Rectus capitis lateralis	Atlas	Jugular process of occipital bone	Stabilizes atlantooccipital joint	Spinal nn. C1–C2 (anterior)
Quadratus lumborum	Iliac crest	Twelfth rib	Stabilizes and lowers 12th ribs during inspiration; abducts vertebral column	Twigs from nn. T12–L4 (ant)

VERTEBRAL COLUMN – biomechanika (diskai)
inervacija

Stuburo raumenys palaiko kūno svorio centrą ties S_1!

a) jei į rankas paimsime 20 kg – slankstelius slegs 20 kg

b) jei tada sulenksime alkūnes, svoris paveš̌tos į priekį 20 cm. Raumenys ties processus spinalis įsitempę (had išlaikyti kūno stačią) taiko jėgą:

$$\frac{20\ kg}{x} = \frac{2\ cm}{20\ cm}$$

– slankstelio leverio arm (processus spinosus) ilgis

$$x = 200\ kg$$

Taigi slankstelius slegs 200 kg raumenų jėga + 20 kg svoris – viso 220 kg

c) jei dar pasilenksime į priekį, svoris nuo S_1 taps per 50 cm, o svoris taps 520 kg – gali plyšti diskas.

$\boxed{\text{Tarpslankstelinio disko atsparumo riba 500–800 kg}}$



Stuburo sensorinė inervacija:

1) r. meningeus (recurrens) (s. N. SINUVERTEBRALIS) – atsišakoja nuo n. spinalis ir tuoj grįžta per foramen intervertebrale atgal

2) šakelės iš DORSAL ir VENTRAL primary rami of n. spinalis