

Vertebrobasilar Ischemia

Last updated: April 20, 2019

ETIOLOGY 1
 PATHOPHYSIOLOGY 1
 CLINICAL FEATURES 1
 DIAGNOSIS 1
 MEDICAL TREATMENT 1
 SURGICAL VERTEBRAL ARTERY RECONSTRUCTION 1
 Indications 2
 Procedure 2
 Postoperative 2
 Complications 2
 SUBCLAVIAN STEAL 3
 Clinical Features 3
 Diagnosis 3
 Treatment 3

ETIOLOGY

1. Atherosclerosis
2. Extrinsic compression (e.g. osteophyte, cervical spine dislocation) – esp. V₂ segment
3. Repetitive trauma (e.g. chiropractic manipulation)
4. Fibromuscular lesions
5. Aneurysms
6. Dissections
7. Takayasu disease

N.B. most serious VERTEBROBASILAR disease is **intracranial**, where surgery is not feasible. (vs. CAROTID disease – **extracranial**, with good surgery results)

PATHOPHYSIOLOGY

- A. **Hemodynamic ischemia** (low risk of infarction):
- a) significant disease must be present in both VAs + incomplete compensation via circle of Willis.
 - b) subclavian-vertebral steal phenomenon. *see below*
- repetitive, short-lived symptoms, which are more of nuisance than danger (but **risk of traumatic injuries** resulting from loss of balance).
 - symptoms are reproducible with **postural - positional* changes**.
*neck rotation or extension
 - symptoms are aggravated by cardiac insufficiency.
- B. **Embolic ischemia** (≈ 30%) from atherosclerotic ostial stenosis of subclavian, vertebral, or basilar arteries.
- likely to cause dangerous infarcts that leave permanent and debilitating strokes.
- C. **Thrombotic ischemia**

N.B it is very rare for VA to be completely occluded at the origin!

CLINICAL FEATURES

- ischemia of "end-organ" of posterior circulation (brainstem, cerebellum, occipital lobes).
see p. Vas3 >>

DIAGNOSIS

Only few studies clearly ascertain VA anatomy:

1. **Systolic BP difference** > 15 mmHg between arms (suggests **subclavian stenosis**).
2. **Duplex ultrasound** - significant limitations (vs. carotid artery); used mainly to detect:
 - 1) flow reversal within VA
 - 2) flow velocity changes (consistent with proximal stenosis).
3. **MRI & MRA** - visualization of VA and BA, posterior fossa infarcts.
4. **Arteriography** (diagnostic test of choice; mandatory prior to any operative intervention)
 - most common site of VA disease is at its origin - requires special projections.
 - suspected VA **compression** → DYNAMIC ANGIOGRAPHY (incorporates provocative positioning).
 - delayed imaging - reconstitution of extracranial VA through cervical collaterals.

MEDICAL TREATMENT

Dual antiplatelet therapy (long-term) - for patients not amenable to surgery or endoluminal therapy.

N.B. role of dual antiplatelet therapy is proven (vs. unclear for carotid stenosis)

Cerebroselective calcium antagonists:

CINNARIZINE

Mechanism of action:

- 1) blocks Ca²⁺ channels → vasodilatation (cerebral, coronary, peripheral).
– does not affect BP and heart rate.
- 2) blocks H₁ receptors → vestibular suppression
- 3) improves blood rheology.

Administration: well absorbed per os; T_{1/2} ≈ 3-6 hrs; max dose – 225 mg/d.

Indications:

- 1) chronic cerebrovascular insufficiency 25-75 mg × 3/d
- 2) labyrinth disorders (vertigo, tinnitus, motion sickness, Ménière disease) 50 mg × 1-2/d.
- 3) migraine prophylaxis
- 4) peripheral circulation disorders 50 mg × 3/d.

Adverse effects: CNS sedation, dry mouth, constipation, epigastric distress (H: use with food), extrapyramidal side effects (e.g. hand tremor), hypotension.

FLUNARIZINE – bifluor derivative of CINNARIZINE – can be administered ×1/d (T_{1/2} ≈ 18 days).
10-15 mg × 1/d at bedtime

SURGICAL VERTEBRAL ARTERY RECONSTRUCTION

- fewer ischemic complications (than carotid surgery) and durable long-term results.

INDICATIONS

N.B. unilateral VA stenosis in asymptomatic patient is not indication for surgery!

Single normal-caliber VA can supply sufficient blood flow into BA regardless of status of contralateral VA.

A. Bilateral severe (> 70%) stenosis

B. Symptomatic cases:

Hemodynamic symptoms + **insufficient blood flow to basilar artery** (i.e. severely stenotic [$> 75\%$] VA and equally diseased or occluded contralateral VA)

- asymptomatic status indicates good compensation from carotid circulation (via PComA).

Embolic symptoms regardless of condition of contralateral VA.

PROCEDURE

- disease location dictates type of surgical reconstruction:

A. Ostial (V₁ segment) - two main options:

- a) **balloon angioplasty & stenting**; stent has to protrude into subclavian lumen (VA ostium is very muscular and has to be stented)
- b) **transposition** of proximal VA onto common carotid artery
- c) VA **bypass**:
 - origin - common carotid artery or subclavian artery.
 - conduit - saphenous vein or prosthetic material (polytetrafluoroethylene or Dacron).
- d) subclavian-vertebral **endarterectomy** is less commonly performed.

B. V₂ segment (surgical reconstruction is very rarely undertaken) – **ligation** (at C₁₋₂ level) and **bypass** to V₃ segment.

- extrinsic lesions can be corrected to relieve kinking or compression of artery (e.g. cervical alignment or surgically opening foramina transversaria).
- most common indication for V₂ segment exposure - control of hemorrhage in traumatic injuries to V₂ segment (H: proximal & distal ligation of artery or coil embolization).

C. V₃ segment:

- a) saphenous vein **bypass** from CCA, subclavian, or proximal VA.
- b) **transposition** of ECA or hypertrophied occipital artery to distal VA.
- c) **transposition** of distal VA to side of distal ICA.

D. V₄ segment – treat only if maximal medical therapy fails!

- **balloon angioplasty & stenting**
- saphenous vein **bypass** from distal ICA - surgical exposure requires resection of C₁ transverse process and part of its posterior arch.

POSTOPERATIVE

- long-term antiplatelet therapy (e.g. **ASPIRIN**).

COMPLICATIONS

Combined morbidity/mortality rates:

Proximal reconstructions (technically easier) - 0.9%.

Distal reconstructions - 3-4%.

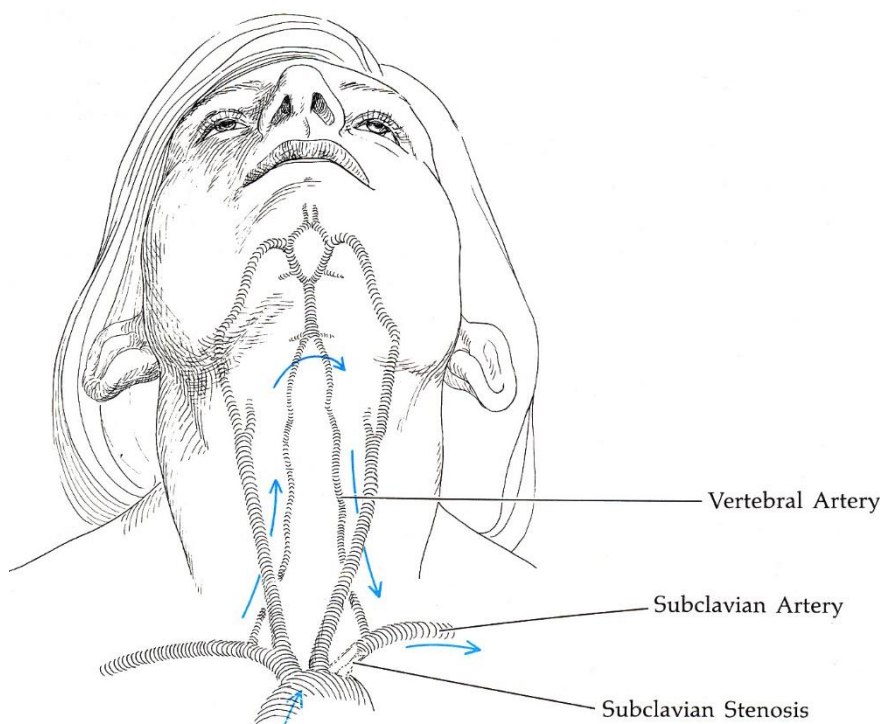
1. **Stroke, hematoma, thrombosis, lymphocele.**

2. **Nerve injury** (e.g. Horner syndrome, spinal accessory nerve, vagus nerve).

- **ptosis on operative side** (known complication of proximal VA reconstructions - traction injury of lower cervical sympathetic nerves) - usually temporary.

SUBCLAVIAN STEAL

- **occlusive disease in proximal subclavian artery (or innominate artery)** → blood flow reversal down VA* on affected side to ischemic limb (i.e. blood siphoning away from brain):
 *VA fills from contralateral VA



Stenosis of the left subclavian artery has caused reversal of blood flow in the patent ipsilateral vertebral artery. Arrows indicate the pattern of blood flow through the cerebral circulation that is characteristic of the subclavian steal syndrome.

CLINICAL FEATURES

- often precipitated by **limb exercise**:
 • **vertebrobasilar TIAs** (but rarely causes stroke).

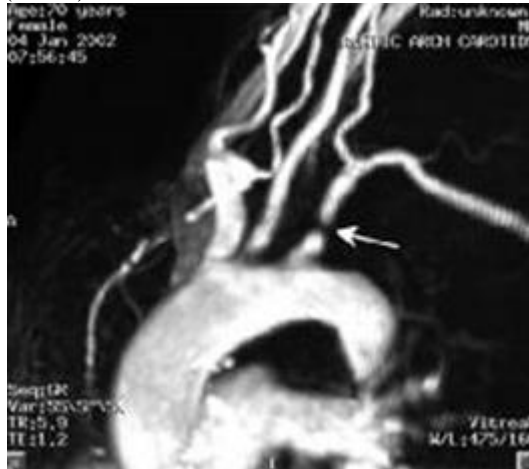posterior circulation symptoms with arm exercise

- **bruit** may be heard over subclavian artery.
- **BP diminished** in affected limb (systolic BP difference > 15-20 mmHg between arms supports diagnosis).
- **pulse beat in radial artery** is diminished and asynchronously follows that of other side.
- **limb claudication**; limb may become cyanotic if held above heart level.

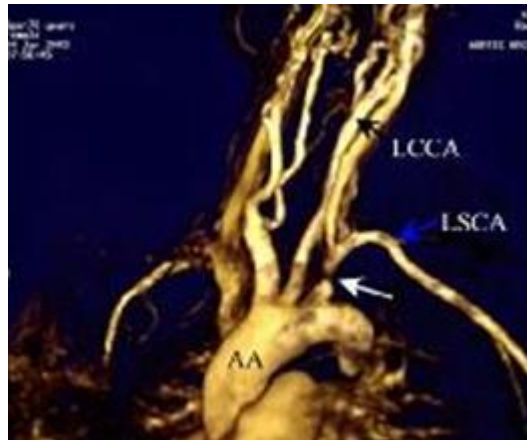
N.B. majority of persons with subclavian steal detected by noninvasive techniques have no neurological symptoms (i.e. merely radiographic curiosity).

DIAGNOSIS

Oblique **MRA** of aortic arch - high-grade stenosis of proximal left subclavian artery (**arrow**):



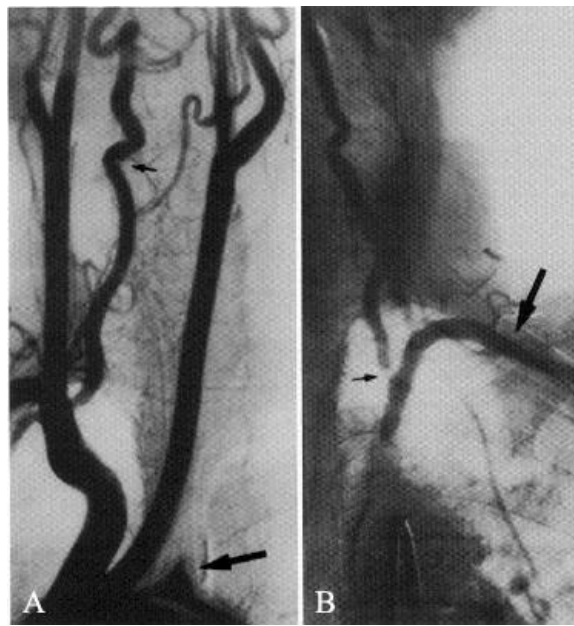
Oblique 3D contrast-enhanced **MRA** of aortic arch - high-grade stenosis of proximal left subclavian artery (**white arrow**); left common carotid artery (LCCA); left subclavian artery (LSCA) (**blue arrow**):



Aortic arch **aortogram**:

A. Left anterior oblique projection, arterial phase: proximal occlusion of left subclavian artery (**arrow**). Note irregularity and tortuosity of right VA - related to degenerative changes in cervical vertebrae (**small arrow**).

B. Right anterior oblique projection late phase of aortogram; distal segment of left subclavian artery (**arrow**) fills via retrograde flow in left VA, despite this vessel being almost completely obstructed at its origin (**small arrow**):



TREATMENT

Surgery is almost never indicated.

BIBLIOGRAPHY for ch. "Neurovascular Disorders" → follow this [LINK >>](#)